

Arthroscopic Bone Block Procedure for Posterior Shoulder Instability: Updated Surgical Technique



Sanne H. van Spanning, M.D., Kevin Picard, M.D., Geert Alexander Buijze, M.D., Ph.D., Alexander Themessl, M.D., Laurent Lafosse, M.D., and Thibault Lafosse, M.D.

Abstract: Posterior shoulder instability is generally caused by traumatic posterior dislocations or repetitive microtrauma during sports or other activities and has an annual incidence rate of 4.64 per 100,000 person-years. Several surgical techniques to treat posterior shoulder instability have been described, including soft-tissue repair and both open and arthroscopic bone block procedures. However, even though patient-reported outcomes are commonly high, surgical procedures are associated with high complication and revision rates of up to 14% and 67%, respectively. In particular, accurate placement of the bone graft, screw orientation, and the treatment of concomitant lesions are considered challenging. Therefore, improvement of surgical techniques is desirable. This Technical Note describes an updated approach to the arthroscopic posterior bone block augmentation described by Lafosse et al. (2012), with tips and tricks on the harvest and positioning of the graft.

Posterior shoulder instability (PSI) is generally caused by traumatic posterior dislocations or repetitive microtrauma during sports or other activities and has an annual incidence rate of 4.64 per 100,000

person-years.^{1,2} Classic mechanisms of injury are a fall on the outstretched arm and hyperstimulation of the subscapularis caused by tonic-clonic seizures and electric shocks, generating forceful internal rotation and adduction of the glenohumeral joint.³ Common pathologies associated with PSI are posterior glenoid fractures, posterior Bankart lesions, and reverse Hill–Sachs lesions.⁴ The number of surgical interventions to treat PSI has increased considerably over the years.¹ Surgical indications include recurrent PSI caused by glenoid dysplasia, irreparable soft-tissue defects, or posterior glenoid bone loss. In addition, posterior bone block procedures may function as revision surgery for persistent instability following posterior Bankart repairs. Several surgical techniques to treat PSI have been described, including soft-tissue repair and both open and arthroscopic bone block procedures.⁵ In 2012, Lafosse et al. proposed an arthroscopic posterior bone block technique using an iliac crest bone graft for both bony and soft-tissue defects, with good clinical results.^{6,7} However, even though patient-reported outcomes are commonly high, posterior bone block procedures are associated with high complication and revision rates of up to 14% and 67%, respectively.^{5,8} In particular, accurate placement of the bone graft, screw orientation, and the treatment of concomitant lesions are considered challenging.⁹ Therefore, improvement of surgical techniques is desirable. This Technical Note describes an updated approach to the arthroscopic posterior bone block augmentation described by Lafosse

From the Alps Surgery Institute, Hand, Upper Limb, Peripheral Nerve, Brachial Plexus and Microsurgery Unit, Clinique Générale Annecy, France (S.H.v.S., K.P., G.A.B., A.T., L.L., T.L.); Shoulder and Elbow Unit, Joint Research, Department of Orthopedic Surgery, OLVG, Amsterdam, The Netherlands (S.H.v.S.); The Amsterdam Shoulder and Elbow Centre of Expertise (ASECE), Amsterdam, The Netherlands (S.H.v.S.); Hôpital Saint-Antoine, Sorbonne Université, Paris, France (K.P.); Department of Orthopedic Surgery, Amsterdam Movement Sciences, Amsterdam UMC, Location AMC, University of Amsterdam, Amsterdam, The Netherlands (G.A.B.); Department of Orthopedic Surgery, Montpellier University Medical Centre, Lapeyronie Hospital, University of Montpellier, Montpellier, France (G.A.B.); and Department of Orthopaedic Sports Medicine, Technical University of Munich, Munich, Germany (A.T.).

The authors report the following potential conflicts of interest or sources of funding: T.L. is a consultant for DePuy Mitek and Stryker. G.A.B. received consultancy fees from DePuy-Synthes and research funds from Société Européenne pour la Chirurgie de l'Epaule et du Coude (SECEC), Vivalto Santé. L.L. is a consultant for DePuy Stryker and received royalties from DePuy. Full ICMJE author disclosure forms are available for this article online, as [supplementary material](#).

Received April 4, 2022; accepted June 18, 2022.

Address correspondence to Thibault Lafosse, 4 Chem. de la Tour la Reine, 74000 Annecy, France. E-mail: thibaultlafosse@hotmail.com

© 2022 THE AUTHORS. Published by Elsevier Inc. on behalf of the Arthroscopy Association of North America. This is an open access article under the CC BY-NC-ND license (<http://creativecommons.org/licenses/by-nc-nd/4.0/>).

2212-6287/22446

<https://doi.org/10.1016/j.eats.2022.06.016>

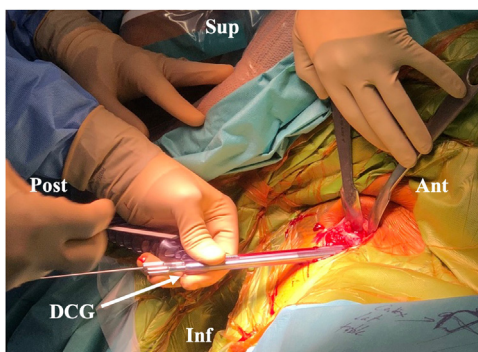


Fig 1. Bone block harvest of the right iliac crest with the patient in beach chair position. Two K-wires are positioned with the double cannula guide, the handle of the cannula is directed superiorly. (Ant, anterior; DCG, double cannula guide; Inf, inferior; Post, posterior; Sup, superior.)

et al. (2012), with tips and tricks on the harvest and positioning of the graft.

Surgical Technique (With Video Illustration)

Arthroscopic Posterior Bone Block Technique

Surgery is performed under general anesthesia in combination with an interscalene regional block. For iliac bone crest harvest, local anesthetics are applied subcutaneously and around the periosteum. Patients are placed in a beach-chair position with the backrest at a 45° angle, to allow for adequate access to the iliac crest. Following the harvest of the bone graft, surgery is continued with the patient in a more sitting position at a 70° angle. The patient is draped in standard sterile fashion and the operated arm is positioned in 30° anterior flexion via a 2- to 3-kg traction cord. Similar to the arthroscopic Latarjet procedure, the DePuy/Mitek arthroscopic Bristow/Latarjet set is used for this arthroscopic posterior bone block procedure.¹⁰

The procedure can be divided into the following steps: (1) arthroscopic joint evaluation; (2) bone graft harvest and preparation; (3) posterior portal landmark and access; (4) glenoid preparation; and (5) graft positioning and fixation.

Arthroscopic Joint Evaluation

Two or three portals are used for this procedure. For the senior author, the first posterior (A) portal is redundant. Thorough joint exploration can be performed with the first anterior (E) portal. The scope can be introduced directly into the joint through the rotator interval. In some cases, the direct introduction of the scope is impossible (i.e., scar tissue around the rotator interval). A lateral C portal, or anterolateral D portal, can be created, giving access to the subacromial space, allowing visualization of the rotator interval. Arthroscopic radiofrequency ablation (VAPR VUE Radiofrequency Electrode System, DePuy Synthes, Raynham,

MA) is used to open the rotator interval. A switching stick is positioned in the joint through the E portal to switch the scope to an intra-articular view. After global evaluation of the joint, soft-tissue lesions, both glenoid and humeral bone loss (i.e., posterior labral, capsular, glenoid rim lesions, and a reverse Hill–Sachs lesion), and concomitant lesions are assessed. After thorough arthroscopic glenohumeral joint evaluation and confirmation of the appropriate indication, harvesting of the bone graft is initiated.

Bone Graft Harvest and Preparation

A bicortical autograft is harvested from the ipsilateral anterior iliac crest, retaining the inner cortex of the pelvic bone. A skin incision is made along the iliac crest about 2 cm posterior to the anterosuperior iliac spine and about 2 cm inferior of the crest to avoid scar formation directly overlying the crest. After visualization of the cortical bone, 2 parallel K-wires are inserted into the lateral cortex using the coracoid cannula's alpha and beta hole previously loaded with 2 long coracoid screws from the arthroscopic Latarjet equipment (Fig 1). The handle of the guide is oriented superiorly to anatomically match the bone graft to the posteroinferior glenoid neck. The placement of the guide allows to select the superior crest as the articular side of the bone block. Then, the cannulated coracoid step drill is advanced over the K-wires to drill two 2.9-mm holes into the bone block. The drill and the K-wires are removed. Before insertion of the top hat washers into the drill holes, tapping of the holes with the top hat tap is required. Once the top hats are in place, the 2-cm × 1-cm × 1-cm graft is harvested, using an oscillating saw or osteotome preserving the medial cortex of the iliac crest (Figs 2 and 3). Following graft harvest, the bone block is attached to coracoid cannula using 2 long cannulated coracoid screws, creating a single unit that can be manipulated into its final position (Fig 4). The iliac crest wound is

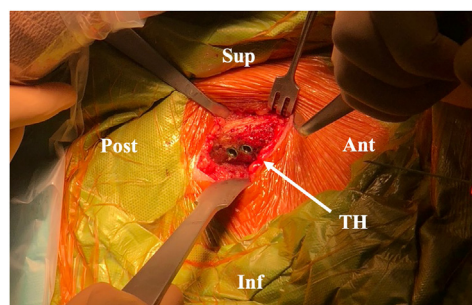


Fig 2. Bone block harvest of the right iliac crest with the patient in the beach-chair position. The drill and K-wires are removed following drilling of the cortical lateral table of the iliac crest, followed by the insertion of 2 "top hats." (Ant, anterior; DCG, double cannula guide; Inf, inferior; Post, posterior; Sup, superior; TH, top hats.)

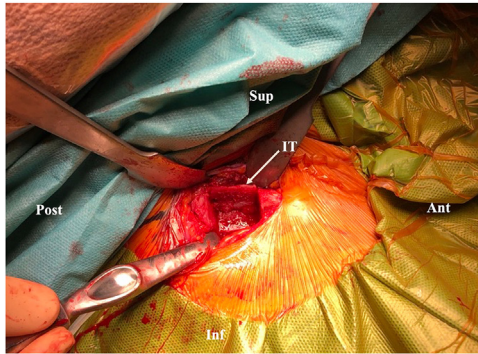


Fig 3. Bone block harvest of the right iliac crest with the patient in the beach-chair position. The inner table of the iliac crest is left intact after graft harvesting. (Ant, anterior; Inf, inferior; IT, inner table; Post, posterior; Sup, superior.)

closed in layers with a drain and dressing is applied. The backrest of the operating table is then adjusted to a 70° angle.

Posterior Landmark and Access

Two to three portals are commonly used. The aim is to create the posterior A portal as aligned with the glenohumeral joint line as possible, therefore, with arthroscopic control and is thus mostly performed after starting the surgery from the anterolateral portals.

The anterolateral portal E is placed in the rotator interval above the biceps, allowing perfect visualization of the posterior half of the glenoid rim (Table 1). Most cases do not require more portals; however, if necessary, an additional posterolateral B portal through the posterior cuff can be used (e.g., to manage complementary labral repair).

Ideally the A portal is created exactly in the axis of the glenohumeral joint line. With an anterior to posterior view via in the E portal, 2 spinal needles are inserted posteriorly at 2.5 to 3 cm from each other, parallelly into the joint at 7- and 9-o'clock position (right shoulder). A skin incision is made between the 2 needles and used as a posterior A portal (Fig 5 A and B).

Glenoid Preparation

Instruments are introduced through the posterior (A) portal. The labrum and posterior capsule are removed from 7 to 10 o'clock (right shoulder) with VAPR and shaver (Fig 6 A and B, Video 1). The posterior glenoid neck is abraded with the arthroscopic burr until bleeding bone is exposed and a flat surface is prepared (Fig 7). Once the glenoid neck is prepared, the posterior A portal is enlarged to allow passage of the graft and double-barreled coracoid cannula. The scalpel can be used to enlarge the muscle split and capsulotomy while the blunt rectangular trocar (subscapularis channeler) may be used to further enlarge the passage (Fig 8).

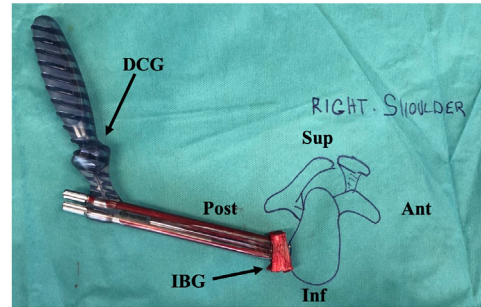


Fig 4. Preparation of the bone block on the side table. Following graft harvest, the bone graft is attached to the double-barreled cannula with the use of 2 cannulated obturators. (Ant, anterior; DCG, double cannula guide; IBG, iliac bone graft; Inf, inferior; Post, posterior; Sup, superior.)

Graft Positioning and Fixation

The graft is inserted through the posterior portal with the handle oriented to the top (Fig 9) and moved through the muscle and capsule split until it is positioned against the neck of the posterior glenoid and flush with the glenoid articular surface. This step requires an important focus on the preparation of the split, particularly focusing on the opening of the infraspinatus muscle fascia which is thick and robust, and will prevent the passage of the graft. It is important to widely open the fascia using a scalpel blade. If necessary, later in the procedure, if irrigation leakage is too important to maintain enough pressure in the shoulder, instruments can be used to partially close the surgical wound (e.g., wound clamps). The coracoid cannula is positioned parallel to the articular surface so that the

Table 1. Tips and Pitfalls

Tips	During positioning of the graft, special attention must be paid to the opening of the infraspinatus muscle fascia to allow appropriate passage of the graft
	During drilling of the bicortical glenoid tunnel, the guide should be held still by both hands and a third K-wire must be ready for insertion to avoid losing the tunnel. A complementary B portal could be created to provide better visualization
	Soft-tissue repair can lead to joint stiffness and is no longer performed by the senior author
	During stabilization of the graft against the posterior glenoid neck, insertion of K-wires should not exceed 40 mm to avoid damaging anterior neurovascular structures
Pitfalls	Due to the natural tendency of the arthroscope to tilt the graft at an angle, final position of the graft must be carefully checked and prominent parts must be rimmed to avoid proud position
	Grafts that are too small may increase the risk of a fracture and limit the amount the graft could be reshaped
	Physiological posterior drawer should still be possible following graft placement
	After remodeling of the graft (minimum 6 months), the screws can become prominent and require hardware removal

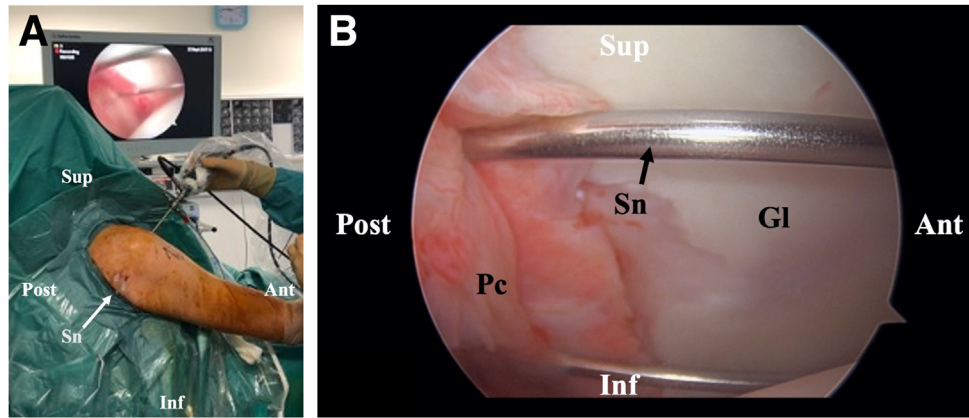


Fig 5. (A) Landmark and preparation for skin incision with the patient in a sitting position at a 70° angle, right shoulder, E-portal view. For the optimum alignment of the posterior A portal with the glenohumeral joint line, 2 spine needles are inserted posteriorly to determine the landmark of the skin incision. (B) Arthroscopic visualization of the placement of the needles with the patient in a sitting position at a 70° angle, right shoulder, E-portal view. (Ant, anterior; DCG, double cannula guide; Gl, glenoid; Inf, inferior; Post, posterior; Pc, posterior capsule; Sn, spinal needle; Sup, superior.)

subsequent K-wires and screws do not penetrate the joint during insertion. By inserting 2 long 1.5-mm K-wires through cannulated coracoid screws, the graft is stabilized against the posterior glenoid neck (Fig 10). Insertion of the K-wires should not exceed 40 mm to avoid passing through the anterior glenoid neck, potentially damaging anterior neurovascular structures, despite the presence of the subscapularis muscle which runs between the neck and the neurovascular structures, protecting it only partially.

Because of the perspective from the anterior portal with the 30° arthroscope, there is a natural tendency to tilt the graft at an angle with the inferior surface being prominent instead of being flush. It is important to check that the physiological posterior drawer is still possible after the graft placement. Once the graft is positioned flush with the posterior glenoid rim, the first long coracoid screw is removed and a bicortical 3- to 2-mm wide glenoid tunnel is drilled over the K-wire. At

this step it is important to be very still after the first drill. The aid must have his both hands maintaining the guide (Fig 11). A third K-wire must be ready to be put in the hole as the one in place is often involuntarily removed being stuck in the motor with the drill. Care must be taken not to remove the K-wire when withdrawing the drill through the coracoid cannula. Then, a 4.5-mm partially threaded Latarjet screw is inserted over the K-wire (Fig 12) and inserted completely to prevent shifting of the graft, before drilling the superior screw. Ideally, screw length should not exceed 32 to 36 mm. Any length greater than 40 mm warrants a double check, as this could be due to a steep angle of the graft relative to the glenoid surface, potentially resulting in malposition of the graft. At this stage, it is still possible to correct the level of graft positioning according to the glenoid by rotating it around the inferior screw. After the first (inferior) screw is inserted the first K-wire can be removed. The second screw is inserted in

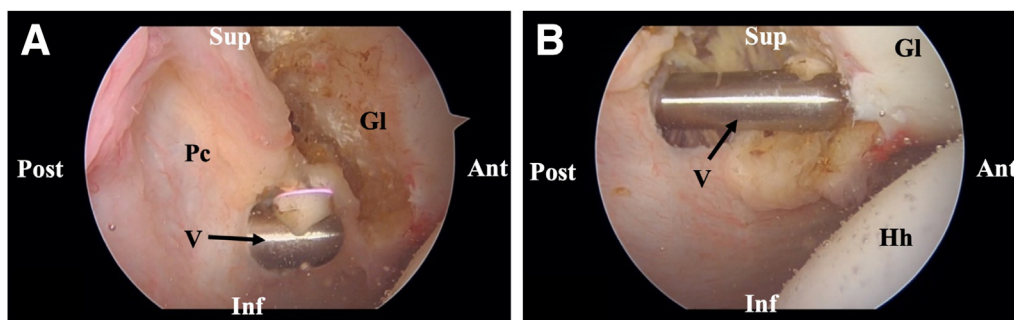


Fig 6. (A-B) Arthroscopic visualization of the glenoid preparation with the patient in a sitting position at a 70° angle, right shoulder, E-portal view. Labrum and posterior capsule detachment from 7 to 10 o'clock with VAPR and shaver during glenoid preparation. (Ant, anterior; Gl, glenoid; Hh, humeral head; Inf, inferior; Pc, posterior capsule; Post, posterior; Sup, superior; V, VAPR.)

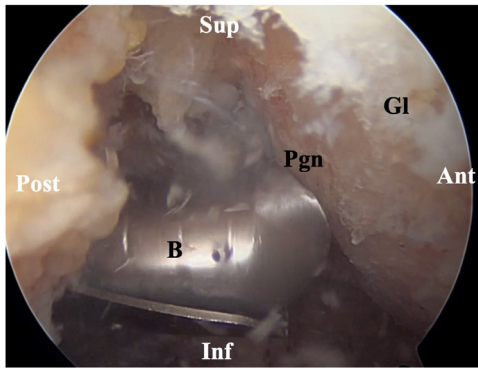


Fig 7. Arthroscopic visualization of the glenoid preparation with the patient in a sitting position at a 70° angle, right shoulder, E-portal view. Abrasion of the posterior glenoid neck during glenoid preparation. (Ant, anterior; B, burr; Gl, glenoid; Inf, inferior; Pgn, posterior glenoid neck; Post, posterior; Sup, superior.)

the same manner. Once the 2 screws have been inserted and the K-wires are removed, the final graft position is checked with a probe from the A portal (Fig 13) and any prominent parts of the graft should be trimmed with the burr. Soft-tissue repair is no longer performed by the senior author to prevent joint stiffness.

Postoperative Management

After surgery, the shoulder is immobilized at a 20° abduction angle and neutral rotation for 6 weeks. The day after surgery, passive shoulder, elbow, and hand range of motion exercises are initiated. Internal rotation and painful movements should be avoided. At 3 weeks, active range of motion exercises are initiated. Following a radiograph to confirm graft stability at 6 weeks postoperative, progression into strengthening exercises can

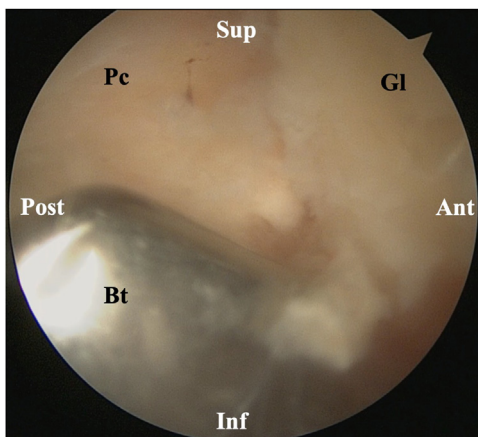


Fig 8. Arthroscopic visualization of the glenoid preparation with the patient in a sitting position at a 70° angle, right shoulder, E-portal view. Enlargement of the posterior A portal with a blunt trocar. (Ant, anterior; Bt: Blunt trocar; Gl, glenoid; Inf, inferior; Pc, posterior capsule; Post, posterior; Sup, superior.)

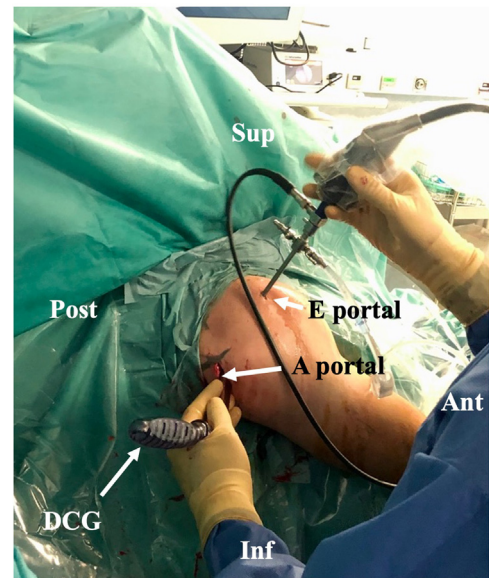


Fig 9. Graft insertion with the patient in a sitting position at a 70° angle, right shoulder, view from posterolateral. The graft is inserted through the posterior portal with the handle oriented to the top. (Ant, anterior; DCG, double cannula guide; Inf, inferior; Post, posterior; Sup, superior.)

begin. In athletes seeking a prompt return to sports, a postoperative computed tomography scan is made at 3 months to assess graft integration.

Discussion

Recent studies support the concept that surgical treatment of PSI remains challenging, with poor clinical results at long-term follow-up.^{11,12} Since accurate placement of the bone graft remains challenging, we propose an updated version the arthroscopic bone block technique by Lafosse et al.⁷ using a 2- or 3-portal procedure. The anterolateral portal through the rotator cuff

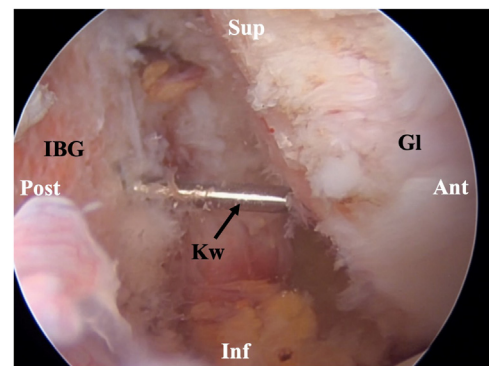


Fig 10. Arthroscopic visualization of graft positioning with the patient in a sitting position at a 70° angle, right shoulder, E portal view. The two inserted K-wires stabilize the graft against the posterior glenoid neck. (Ant, anterior; Gl, glenoid; IBG, iliac bone graft; Inf, inferior; Kw, K-wire; Post, posterior; Sup, superior.)

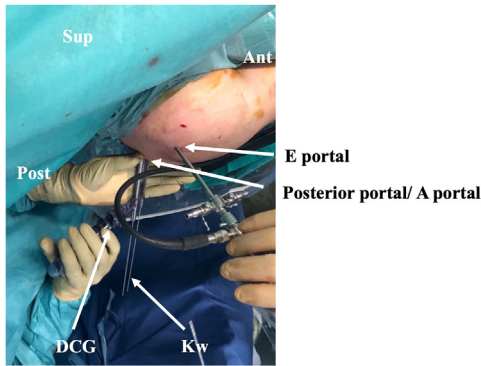


Fig 11. Graft positioning and fixation, with the patient in a sitting position at a 70° angle, right shoulder, view from above. During and after drilling of the graft, the guide is held still with 2 hands to prevent loosening of the tunnel with the K-wire. (Ant, anterior; DCG, double cannula guide; Kw, K-wire; Post, posterior; Sup, superior.)

interval increases visibility, which allows the posterior portal to be perfectly aligned with the level of the glenoid. This in turn ensures an easier placement of the bone graft. In addition, an alternative way to harvest the bone graft at the iliac crest site has been proposed to facilitate the procedure.

PSI, unlike anterior shoulder instability, can be easily missed and therefore a thorough clinical examination and imaging are necessary. In cases of structural lesions and recurrent instability, surgery is warranted. Important risk factors of recurrent posterior shoulder instability are glenoid retroversion and glenoid bone loss.¹³ Several surgical techniques have been proposed to treat PSI, including soft-tissue repair and bone block procedures. Patient-reported outcomes and return to sport have improved following posterior Bankart

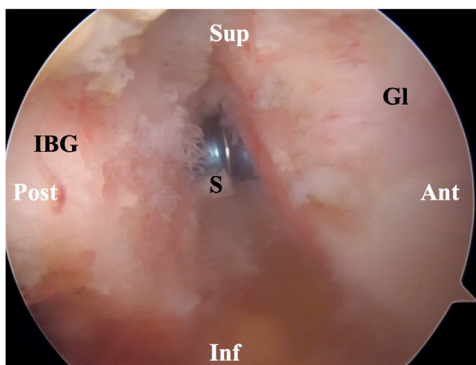


Fig 12. Arthroscopic visualization of graft fixation with the patient in a sitting position at a 70° angle, right shoulder, E-portal view. The inferior 4.5 mm partially threaded Latarjet screw is positioned first over the K-wire. (Ant, anterior; Gl, glenoid; IBG, iliac bone graft; Inf, inferior; S, screw; Post, posterior; Sup, superior.)

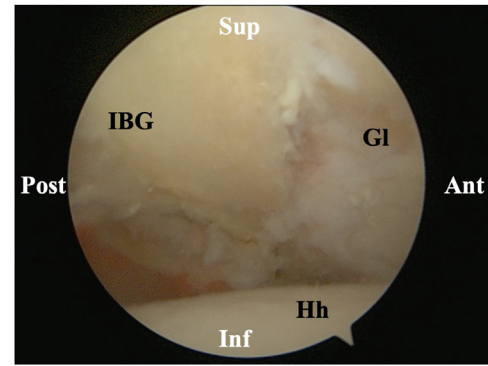


Fig 13. Arthroscopic visualization of graft positioning with the patient in a sitting position at a 70° angle, right shoulder, E portal view. Following insertion of the two screws and removal of K-wires, the final graft position is checked. This bone graft has a good compression and does not have a proud position. (Ant, anterior; Gl, glenoid; Hh, humeral head; IBG, iliac bone graft; Inf, inferior; Post, posterior; Sup, superior.)

repair; however, soft-tissue repair is associated with high recurrence rates of up to 73%.^{8,14} Patients with glenoid retroversion of >10° and posterior glenoid bone loss may benefit more from bone block procedures.^{15,16} However, there is still an ongoing debate on defining critical posterior glenoid bone loss for PSI. According to one study, patients with 11% bone loss were 10 times more likely to experience recurrent PSI following capsulolabral repair, whereas the failure risk increased to 25 times with 15% glenoid bone loss.¹⁷ Shoulders with >20% posterior glenoid bone loss remain unstable following capsulolabral repair, whereas glenoid contact areas could be fully restored with distal tibial allograft or iliac crest bone graft reconstruction.^{17,18} However, bone block procedures are still associated with high complication rates.⁵ Symptomatic hardware problems are the most common complications, especially insertion of screws remains challenging.^{5,6,9,19} Posterior open-wedge glenoid osteotomy, used in patients with excessive glenoid retroversion, is associated with high reported rates of recurrent PSI (86%) and osteoarthritis (100%) at long-term follow-up.¹² Bone block procedures using distal tibial grafts have shown good clinical outcomes, but literature on this procedure is scarce.¹⁹ The more commonly used iliac crest bone graft procedure is associated with high recurrence and revision rates of up to 73% and 40% when performed open and 21% and 67% when performed arthroscopically.^{5,11,20,21} However, patient reported outcomes are generally satisfactory.^{6,9,21} Comparing literature on either of these procedures remains challenging due to the small sample sizes and heterogeneity throughout.

An important advantage of the updated arthroscopic technique proposed here is the increased visibility and

the tips and tricks leading to a more convenient execution of the procedure. In addition, compared with open techniques, good cosmetic results are achieved.

This study is a Technical Note to facilitate the procedure and improve its outcome; however, further research is needed to confirm the latter. In conclusion, the technical recommendations here may help surgeons improve the arthroscopic bone block technique and achieve improved clinical outcomes following surgical treatment of PSI.

References

- Woodmass JM, Lee J, Wu IT, et al. Incidence of posterior shoulder instability and trends in surgical reconstruction: A 22-year population-based study. *J Shoulder Elbow Surg* 2019;28:611-616.
- Provencher MT, LeClere LE, King S, et al. Posterior instability of the shoulder: Diagnosis and management. *Am J Sports Med* 2011;39:874-886.
- Perron AD, Jones RL. Posterior shoulder dislocation: Avoiding a missed diagnosis. *Am J Emerg Med* 2000;18:189-191.
- Clavert P, Furioli E, Andieu K, et al. Clinical outcomes of posterior bone block procedures for posterior shoulder instability: Multicenter retrospective study of 66 cases. *Orthop Traumatol Surg Res* 2017;103:S193-S197.
- Cognetti DJ, Hughes JD, Kay J, et al. Bone block augmentation of the posterior glenoid for recurrent posterior shoulder instability is associated with high rates of clinical failure: A systematic review. *Arthroscopy* 2021;38:551-563.e555.
- Schwartz DG, Goebel S, Piper K, Kordasiewicz B, Boyle S, Lafosse L. Arthroscopic posterior bone block augmentation in posterior shoulder instability. *J Shoulder Elbow Surg* 2013;22:1092-1101.
- Lafosse L, Franceschi G, Kordasiewicz B, Andrews WJ, Schwartz D. Arthroscopic posterior bone block: Surgical technique. *Musculoskelet Surg* 2012;96:205-212.
- Mojica ES, Schwartz LB, Hurley ET, Gonzalez-Lomas G, Campbell KA, Jazrawi LM. Posterior glenoid bone block transfer for posterior shoulder instability: A systematic review. *J Shoulder Elbow Surg* 2021;30:2904-2909.
- Barbier O, Ollat D, Marchaland JP, Versier G. Iliac bone-block autograft for posterior shoulder instability. *Orthop Traumatol Surg Res* 2009;95:100-107.
- Lafosse L, Lejeune E, Bouchard A, Kakuda C, Gobezie R, Kochhar T. The arthroscopic Latarjet procedure for the treatment of anterior shoulder instability. *Arthroscopy* 2007;23. 1242.e1241-1245.
- Meuffels DE, Schuit H, van Biezen FC, Reijman M, Verhaar JA. The posterior bone block procedure in posterior shoulder instability: A long-term follow-up study. *J Bone Joint Surg Br* 2010;92:651-655.
- Waltenspul M, Haller T, Ernstbrunner L, Wyss S, Wieser K, Gerber C. Long-term results after posterior open glenoid wedge osteotomy for posterior shoulder instability associated with excessive glenoid retroversion. *J Shoulder Elbow Surg* 2022;31:81-89.
- Owens BD, Campbell SE, Cameron KL. Risk factors for posterior shoulder instability in young athletes. *Am J Sports Med* 2013;41:2645-2649.
- Hurley JA, Anderson TE, Dear W, Andrish JT, Bergfeld JA, Weiker GG. Posterior shoulder instability. Surgical versus conservative results with evaluation of glenoid version. *Am J Sports Med* 1992;20:396-400.
- Imhoff FB, Camenzind RS, Obopilwe E, et al. Glenoid retroversion is an important factor for humeral head centration and the biomechanics of posterior shoulder stability. *Knee Surg Sports Traumatol Arthrosc* 2019;27:3952-3961.
- Nacca C, Gil JA, Badida R, Crisco JJ, Owens BD. Critical glenoid bone loss in posterior shoulder instability. *Am J Sports Med* 2018;46:1058-1063.
- Arner JW, Ruzbarsky JJ, Midtgaard K, Peebles L, Bradley JP, Provencher MT. Defining critical glenoid bone loss in posterior shoulder capsulolabral repair. *Am J Sports Med* 2021;49:2013-2019.
- Frank RM, Shin J, Saccomanno MF, et al. Comparison of glenohumeral contact pressures and contact areas after posterior glenoid reconstruction with an iliac crest bone graft or distal tibial osteochondral allograft. *Am J Sports Med* 2014;42:2574-2582.
- Gilat R, Haunschild ED, Tauro T, et al. Distal tibial allograft augmentation for posterior shoulder instability associated with glenoid bony deficiency: A case series. *Arthrosc Sports Med Rehabil* 2020;2:e743-e752.
- Wellmann M, Pastor MF, Ettinger M, Koester K, Smith T. Arthroscopic posterior bone block stabilization-early results of an effective procedure for the recurrent posterior instability. *Knee Surg Sports Traumatol Arthrosc* 2018;26:292-298.
- Camenzind RS, Martin Becerra J, Gossing L, Serane-Fresnel J, Wagner ER, Lafosse L. Acceptable long-term outcomes of arthroscopic bone grafting for recurrent posterior shoulder instability: Minimum follow-up of 5 years. *Arthroscopy* 2021;37:816-823.