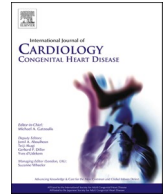




Contents lists available at ScienceDirect

# International Journal of Cardiology Congenital Heart Disease

journal homepage: [www.journals.elsevier.com/international-journal-of-cardiology-congenital-heart-disease](http://www.journals.elsevier.com/international-journal-of-cardiology-congenital-heart-disease)



## Percutaneous edge-to-edge repair in congenital heart disease

We read with great interest the recent review by Silini and Iriart regarding the role of percutaneous edge-to-edge repair in congenital heart disease (CHD) [1]. The authors aimed to compile all published case reports and case series of patients with CHD and atrioventricular valve regurgitation treated with percutaneous edge-to-edge repair. Their literature search yielded nine cases with a systemic right ventricle and a biventricular circulation (eight patients with congenitally corrected transposition of the great arteries (CCTGA), one after the Mustard procedure for transposition of the great arteries) [1]. Out of these, eight had an intervention on the systemic atrioventricular valve – the tricuspid valve, and one patient on the subpulmonary atrioventricular valve.

Unfortunately, they missed the largest case series reported so far. We published our single-center experience of six patients with CCTGA and tricuspid regurgitation (TR), for whom surgery was deemed high risk [2]. Percutaneous repair of TR was safe and successful in all, while a significant reduction of TR severity was achieved [2]. After twelve months of follow-up, improvement of TR severity was sustained in all but one patient. The latter had reoccurrence of severe TR and required a second intervention with two additional MitraClips (MitraClip®; Abbott Vascular, Santa Clara, CA, USA). While the baseline New York Heart Association class was  $\geq$ III in all patients, it showed a sustained improvement to  $\leq$  II in all patients at the follow-up after twelve months.

Therefore, at least 14 cases of an intervention on the systemic atrioventricular valve in patients with a systemic right ventricle have been reported in the literature. Additional cases have already been performed in expert centers, which were not published yet.

In conclusion, percutaneous repair techniques for atrioventricular valve regurgitation might indeed play a role in selected patients with CHD, especially in those with a high surgical risk. Particularly, when taking into account that new interventional devices are currently developed and evaluated for TR in the setting of acquired cardiovascular disease [3,4]. These could also hold promise for our CHD patients. However, the optimal timing of the intervention as well as long-term

outcomes need to be studied. Furthermore, these interventions should only be performed in centers with experience in both, CHD and percutaneous valve repair.

### Declaration of competing interest

The authors declare that they have no known competing financial interests or personal relationships that could have appeared to influence the work reported in this paper.

### References

- [1] Silini A, Iriart X. Percutaneous edge-to-edge repair in congenital heart disease: preliminary results of a promising new technique. *Int J Cardiol Congenital Heart Dis* 2022;8:100370. <https://doi.org/10.1016/j.ijchd.2022.100370>.
- [2] Ott I, Rumpf PM, Kasel M, Kastrati A, Kaemmerer H, Schunkert H, et al. Transcatheter valve repair in congenitally corrected transposition of the great arteries. *EuroIntervention* 2021;17:744–6.
- [3] Nickenig G, Weber M, Lurz P, von Bardeleben RS, Sitges M, Sorajja P, et al. Transcatheter edge-to-edge repair for reduction of tricuspid regurgitation: 6-month outcomes of the TRILUMINATE single-arm study. *Lancet* 2019;394:2002–11.
- [4] Kodali S, Hahn RT, Eleid MF, Kipperman R, Smith R, Lim DS, et al. Feasibility study of the transcatheter valve repair system for severe tricuspid regurgitation. *J Am Coll Cardiol* 2021;77:345–56.

Oktay Tutarel<sup>a,b,\*</sup>

<sup>a</sup> Department of Congenital Heart Disease and Paediatric Cardiology, German Heart Centre Munich, TUM School of Medicine, Technical University of Munich, Munich, Germany

<sup>b</sup> DZHK (German Centre for Cardiovascular Research), Partner Site Munich Heart Alliance, Munich, Germany

\* Department of Congenital Heart Disease and Paediatric Cardiology, German Heart Centre Munich, TUM School of Medicine, Technical University of Munich, Munich, Germany.  
E-mail address: [oktay.tutarel@tum.de](mailto:oktay.tutarel@tum.de).

<sup>1</sup> This author takes responsibility for all aspects of the reliability and freedom from bias of the data presented and their discussed interpretation.