

# A case report of primary cardiac sarcoma: a diagnostic and therapeutic challenge

Carsten Lennerz<sup>1,2\*</sup>, Matthew O'Connor<sup>3</sup>, Heribert Schunkert<sup>1,2</sup>, and Marcus-André Deutsch<sup>4</sup>

<sup>1</sup>Deutsches Herzzentrum München, Klinik für Herz- und Kreislauferkrankungen, Faculty of Medicine, Technische Universität München, Lazarettstr. 36 80636 Munich, Germany;

<sup>2</sup>DZHK (German Centre for Cardiovascular Research), Partner Site Munich Heart Alliance, Munich, Germany; <sup>3</sup>Wellington Hospital, Department of Cardiology, Wellington, New Zealand; and <sup>4</sup>Deutsches Herzzentrum München, Klinik für Herz- und Gefäßchirurgie, Faculty of Medicine, Technische Universität München, Munich, Germany

Received 18 September 2017; accepted 8 November 2018; online publish-ahead-of-print 7 December 2018

## Background

Primary cardiac tumours are rare and the majority are benign; of those that are malignant sarcomas are the most common and have a poor prognosis. Genomic sequencing of tumours has permitted targeted treatments in other tumour types such as leukaemia and non-small cell lung cancer. These targeted treatments such as tyrosine kinase inhibitors and cyclin-dependent kinase 4 (CDK-4) inhibitors are effective and better tolerated than chemotherapy options. Our case highlights their potential use in cardiac tumours.

## Case summary

An 18-year-old female patient presented with severe dyspnoea and sinus tachycardia. A computed tomography chest scan identified a large filling defect within the left atrium consistent with a cardiac tumour. The mass was surgically excised and confirmed to be an undifferentiated pleomorphic sarcoma. Treatment was with doxorubicin and ifosfamide. Tumour genome sequencing was undertaken revealing an amplification of 12q including CDK-4 identifying Palbociclib (a CDK-4 inhibitor) as a potential innovative future therapeutic option in the case of failure of first-line therapy. The patient made a full recovery with no evidence of recurrence at 30 months.

## Discussion

Cardiac tumours are often identified during investigations for other conditions as their non-specific symptoms mimic other conditions, and a high degree of suspicion is required to diagnose them. To date Palbociclib is not yet licenced for use in cardiac sarcomas. It has been shown to be more tolerable than chemotherapy in breast cancer and offers a viable alternative therapy in cardiac sarcomas. More importantly this case demonstrates the importance of tumour genomic sequencing in identifying tumour-specific mutations that can be targeted.

## Keywords

Cardiac sarcoma • Genome sequencing • Personalized treatment • Palbociclib • CDK-4 • Case report

## Learning points

- This case illustrates two crucial aspects of cardiac tumours; (i) they can masquerade as other conditions and (ii) their genomic analysis can potentiate individualized therapy.

\*Corresponding author. Tel: +49 89 1218 0, Fax: +49 89 1218 4593, Email: lennerz@dhm.mhn.de

Handling Editor: Matteo Cameli

Peer-reviewers: Flavio D'Ascenzi, Noémi Nyolczas, and Sabiha Gati

Compliance Editor: Anastasia Vamvakidou

Supplementary Material Editor: Peysh Patel

© The Author(s) 2018. Published by Oxford University Press on behalf of the European Society of Cardiology.

This is an Open Access article distributed under the terms of the Creative Commons Attribution Non-Commercial License (<http://creativecommons.org/licenses/by-nc/4.0/>), which permits non-commercial re-use, distribution, and reproduction in any medium, provided the original work is properly cited. For commercial re-use, please contact [journals.permissions@oup.com](mailto:journals.permissions@oup.com)

## Introduction

Primary malignant cardiac tumours are rare (incidence <0.005%) and often present due to symptoms from local mass effect. Common symptoms include dyspnoea, chest pain, and congestive heart failure secondary to compromised blood flow<sup>1</sup>; these symptoms are non-specific and often mimic other conditions i.e. acute pulmonary embolism. Despite surgical resection and chemotherapy prognosis remains poor with a median survival of 6–12 months. We report the use of tumour genome sequencing to allow for personalized treatment to optimize outcomes.

## Timeline

1 month prior to presentation	Insidious onset of fatigue and lethargy
2–3 days prior to presentation	Onset of progressive dyspnoea
Upon presentation	Severe dyspnoea associated with a sinus tachycardia (140 b.p.m.) and pre-syncope. Blood pressure 120/80 mmHg. Elevated d-dimer (6.6 µg/mL). Computed tomography pulmonary angiogram scan and echocardiography demonstrated large left atrial mass obstructing the mitral valve inflow.
After 3 days	Successful surgical resection of the tumour (confirmed as an undifferentiated pleomorphic sarcoma on histology) and standard treatment with doxorubicin and ifosfamide.
After 6 months	Tumour genome sequencing revealed an amplification in cyclin-dependant kinase 4 (CDK-4) Identifying Palbociclib, a CDK-4 inhibitor, as therapy strategy in case of failure of the standard first-line chemotherapy.
After 30 months	The patient remains free of disease recurrence and is currently on no treatment.

## Case summary

An 18-year-old female patient with no prior medical history presented to the emergency department with a one month history of fatigue and lethargy without associated constitutional symptoms of weight loss or fevers. She complained of pre-syncope and severe dyspnoea on minimal exertion (a single flight of stairs) culminating in paroxysmal nocturnal dyspnoea associated, chest tightness and palpitations which acutely precipitated her presentation. She was a non-smoker with no relevant family history.

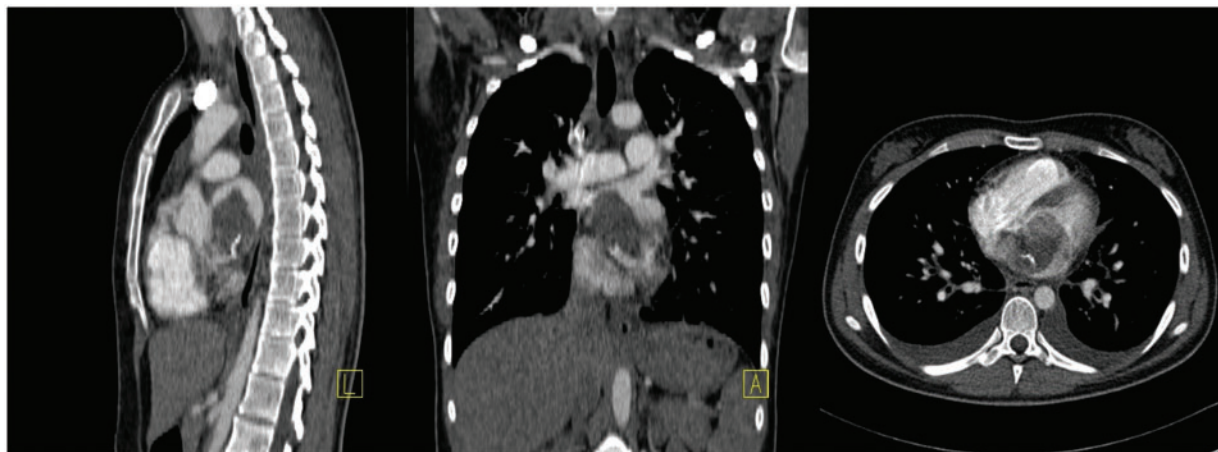
On presentation the patient was afebrile, but had an elevated respiratory rate of 22 breaths/minute with an oxygen saturation of 98% without supplemental oxygen. She had a sinus tachycardia of 140 b.p.m., was normotensive with no postural deficit (120/

80 mmHg lying and 118/82 mmHg standing). Examination revealed no peripheral oedema and a non-elevated jugular venous pressure. Cardiac auscultation revealed a II/VI pan-diastolic murmur with no additional sounds and no right ventricular heave. The chest was resonant to percussion, but breath sounds were decreased bibasally.

Laboratory results revealed a d-dimer of 6.6 µg/mL (<0.5 µg/mL) and a haemoglobin of 13.7 g/dL (12.3–15.3 g/dL); the remainder of the blood count and biochemistry being within normal limits. An ECG revealed sinus tachycardia with normal p-wave axis (+60°) and a narrow QRS. A chest X-ray demonstrated mild blunting of the costophrenic angles bilaterally. The primary differential diagnosis was a pulmonary embolus (PE) and as such a computed tomography pulmonary angiogram (CTPA) was performed and ruled out a PE, but did demonstrate bilateral pleural effusions and a large (60 × 38 mm) filling defect in the left atrium (*Figure 1*). Transthoracic echocardiogram confirmed the presence of a mobile large left atrial mass originating from the intra-atrial septum with associated compromise of the mitral inflow (*Supplementary material online, Video S1*), there was no associated pericardial effusion. The mass was non-pedunculated and partially prolapsed into the LV during diastole with anterior displacement of the anterior mitral valve leaflet. There was no thrombus in association with the mass; however, anticoagulation was commenced with a heparin infusion. A full-body CT scan revealed no evidence of distant metastasis. A left atrial mass arising from the intra-atrial septum is most commonly a benign atrial myxoma, but the differential includes thrombus and a wide variety of primary and secondary malignant tumours.

Due to the compromise of the mitral inflow and cardiovascular compromise as indicated by the presence of a significant sinus tachycardia urgent cardiothoracic surgery was performed to resect the tumour (*Figure 2*). Intra-operatively the mitral valve was found to be structurally intact and did not need repair or replacement and the tumour was successfully resected (*Figure 3*). Histological analysis identified the tumour as an undifferentiated pleomorphic sarcoma and chemotherapy with doxorubicin and ifosfamide was administered over a period of 18 weeks (six cycles of doxorubicin (25 mg/m<sup>2</sup> intravenously) on Days 1–3, ifosfamide (2.5 g/m<sup>2</sup> intravenously) on Days 1–4 and pegylated granulocyte colony stimulating factor (6 mg subcutaneously) on Day 5. Each cycle consists of 21 days). The patient was initially followed up with three monthly cardiac magnetic resonance imaging (cMRI), CT, and transoesophageal echocardiogram for 24 months and then with six monthly cMRI scans planned until 60 months post-surgery. Additionally, we performed comprehensive tumour genome sequencing to identify cancer-driving mutations and to enable personalized, targeted therapy against molecular and genetic factors promoting tumour growth. This analysis revealed amplification of 12q including cyclin-dependent kinase 4 (CDK-4) and thereby identified a viable second line, tumour-specific treatment option, the CDK-4 inhibitor Palbociclib. In this case first-line chemotherapy was effective and Palbociclib was not required, but remains a viable option in the case of recurrence.

The patient was able to be discharged 10 days after surgery and remains disease free and asymptomatic at 30 months after surgery with no ongoing therapy. The patient tolerated chemotherapy well with no lasting side effects.



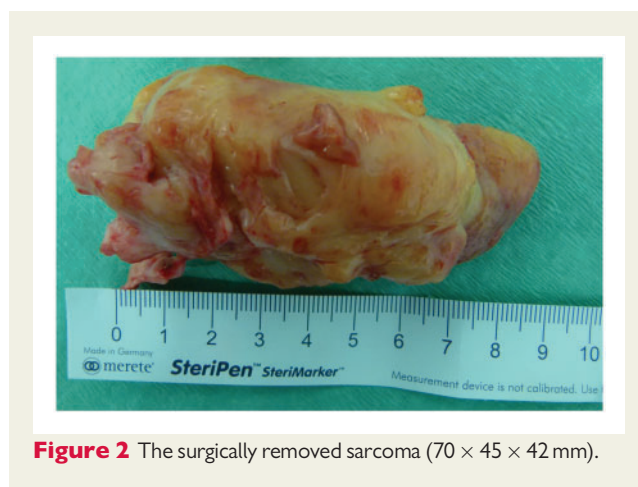**Figure 1** Computerized tomography images demonstrating a region of hypoattenuation (60 × 38 mm) within the left atrium. Left: sagittal plane. Middle: coronal plane. Right: transverse plane.

## Discussion

Cardiac tumours often present with non-specific symptoms due to their mass effect, such as dyspnoea, tachycardia, congestive cardiac failure or syncope. They can therefore mimic a variety of other clinical entities such as PE, ischaemic heart disease, cardiac failure, or stroke. Due to their non-specific presentation they are often identified during investigation for other causes, such as in our case with a CTPA for a PE. Cardiac tumours are benign in 80% of cases, predominantly myxomas.<sup>1</sup> It is difficult to differentiate between tumour types non-invasively; cMRI can provide information such as tissue characterization, extent of cardiac, and extra-cardiac involvement, but the diagnostic accuracy remains low, 68%, compared to the gold standard of histopathological examination.<sup>2</sup> In our case the patient's tachycardia and dyspnoea would have limited cMRI image quality and thus surgical resection was performed to relieve the cardiovascular compromise and to facilitate histological and genetic analysis.

Primary cardiac sarcomas account for the majority of primary cardiac malignancies and have a poor prognosis with a median survival of 9 months.<sup>3</sup> First-line treatment consists of surgical resection and chemotherapy with doxorubicin and ifosfamide,<sup>4,5</sup> due to the low incidence of primary cardiac sarcomas this recommendation is based on case reports and retrospective analyses not randomized controlled studies. As with other solid tumours genetic tumour profiling can be performed to help identify alternative therapeutic options including tyrosine kinase inhibitors, monoclonal anti-bodies and, as in our case, CKD-4 inhibitors.

Palbociclib is a CDK-4 inhibitor that is currently licenced for hormone receptor positive, human epidermal growth receptor 2 negative breast cancer. There is also phase II trial evidence for its use in liposarcomas which exhibit abnormal amplification of CDK-4(6). Its efficacy of CDK-4 inhibition is inversely related to levels of p16ink4 mRNA levels on immunohistochemical analysis.<sup>7</sup> Palbociclib is an oral agent administered over a 28 day cycle; 125 mg daily for 21 days followed by 7 days off.<sup>6</sup> The number of



**Figure 2** The surgically removed sarcoma (70 × 45 × 42 mm).

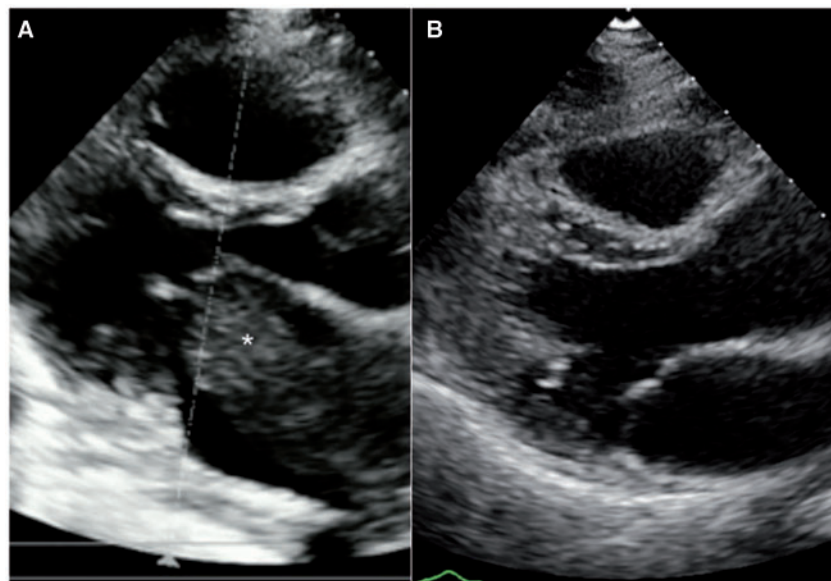
cycles is based on response and is determined on an individual basis. The most common side effects include neutropenia (Grade 3: 56.1%), anaemia (Grade 3: 5.2%), asthenia (Grade 3: 2.3%), and thrombocytopenia (Grade 3: 1.4%) with febrile neutropenia occurring in 3% of patients.<sup>8</sup>

## Conclusions

This case highlights the use of tumour genomic sequencing to identify viable second line therapies in cardiac sarcomas. However, reimbursement of such orphan drugs often represents an obstacle to personalized therapy in most health care systems.

## Supplementary material

Supplementary material is available at *European Heart Journal - Case Reports* online.



**Figure 3** Echocardiographic images (parasternal long axis during diastole) before (A) and after (B) surgical resection of the tumour (\*).

## Funding

This work was supported by the German Research Foundation (DFG) and the Technical University of Munich within the funding programme Open Access Publishing.

**Slide sets:** A fully edited slide set detailing this case and suitable for local presentation is available online as [Supplementary data](#).

**Consent:** The author/s confirm that written consent for submission and publication of this case report including image(s) and associated text has been obtained from the patient in line with COPE guidance.

**Conflict of interest:** none declared.

## References

1. Molina JE, Edwards JE, Ward HB. Primary cardiac tumors: experience at the University of Minnesota. *Thorac Cardiovasc Surg* 1990;**38** Suppl 2:183–191.
2. Patel R, Lim RP, Saric M, Nayar A, Babb J, Ettel M, Axel L, Srichai MB. Diagnostic performance of cardiac magnetic resonance imaging and

echocardiography in evaluation of cardiac and paracardiac masses. *Am J Cardiol* 2016;**117**:135–140.

3. Oliveira GH, Al-Kindi SG, Hoimes C, Park SJ. Characteristics and survival of malignant cardiac tumors. *Circulation* 2015;**132**:2395–2402.
4. Frezza AM, Stacchiotti S, Gronchi A. Systemic treatment in advanced soft tissue sarcoma: what is standard, what is new. *BMC Med* 2017;**15**:109.
5. Judson I, Verweij J, Gelderblom H, Hartmann JT, Schöffski P, Blay J-Y, Kerst JM, Suflarsky J, Whelan J, Hohenberger P, Krarup-Hansen A, Alcindor T, Marreaud S, Litière S, Hermans C, Fisher C, Hogendoorn PCW, Dei Tos AP, van der Graaf WTA. Doxorubicin alone versus intensified doxorubicin plus ifosfamide for first-line treatment of advanced or metastatic soft-tissue sarcoma: a randomised controlled phase 3 trial. *Lancet Oncol* 2014;**15**:415–423.
6. Dickson MA, Schwartz GK, Keohan ML, D'Angelo SP, Gounder MM, Chi P, Antonescu CR, Landa J, Qin L-X, Crago AM, Singer S, Koff A, Tap WD. Progression-free survival among patients with well-differentiated or dedifferentiated liposarcoma treated with CDK4 inhibitor palbociclib. *JAMA Oncol* 2016;**2**:937–940.
7. Perez M, Muñoz-Galván S, Jiménez-García MP, Marín JJ, Carnero A. Efficacy of CDK4 inhibition against sarcomas depends on their levels of CDK4 and p16ink4 mRNA. *Oncotarget* 2015;**6**:40557–40574.
8. Finn RS, Martin M, Rugo HS, Jones S, Im S-A, Gelmon K, Harbeck N, Lipatov ON, Walshe JM, Moulder S, Gauthier E, Lu DR, Randolph S, Diéras V, Slamon DJ. Palbociclib and letrozole in advanced breast cancer. *N Engl J Med* 2016;**375**:1925–1936.