

Disseminated Granuloma Annulare – Treatment with Fumaric Acid Esters

B. Eberlein-König^a M. Mempel^a J. Stahlecker^b I. Forer^b J. Ring^b
D. Abeck^b

^aDivision 'Environmental Dermatology and Allergology' GSF/TUM, Neuherberg-Munich, and

^bDepartment of Dermatology and Allergy Biederstein, Technical University Munich, Munich, Germany

Key Words

Fumaric acid esters · Disseminated granuloma annulare

Abstract

Background: The therapy of disseminated granuloma annulare has often limited success. Treatment of granuloma annulare with fumaric acid esters (FAE) has recently been reported to be effective in 2 patients. **Objectives:** To assess the efficacy of a systemic therapy with FAE in consecutive patients with disseminated granuloma annulare. **Methods:** Eight patients with disseminated granuloma annulare were treated with FAE in tablet form according to the standard therapy regimen used in psoriasis. The colour and the elevation of the skin lesions were assessed by a visual analogue scale before and after therapy. **Results:** Systemic therapy with FAE induced a significant clinical improvement in elevation and colour of skin lesions, with remission in 3 and partial remission in 4 patients. One patient remained unchanged. Side-effects associated with the therapy were seen in 6 patients. **Conclusions:** Systemic therapy with FAE can be effective in patients suffering from disseminated forms of granuloma annulare, but side-effects of FAE have to be taken into consideration.

Copyright © 2005 S. Karger AG, Basel

Introduction

Disseminated granuloma annulare is a benign skin disease of unknown aetiology associated with diabetes mellitus in up to 20% of patients. Various treatments (niacinamide, clofazimine, dapsone, retinoids, pentoxifylline, cyclosporin, methotrexate, UVA-1, corticosteroids, PUVA therapies) were tried, but their efficiency was inconstant. Recently, 2 patients with disseminated granuloma annulare have successfully been treated with fumaric acid esters (FAE) [1, 2]. We studied the effect of systemic FAE in 8 consecutive patients.

Material and Methods

Patients

Eight female patients (aged 19–72 years) were included. Five of them had been suffering from the disease for several years, with a stable course, while 3 of them had recent onset (≤ 1 year) disease. Seven out of the 8 patients had already been treated with other treatments, e.g. topical steroids or UV therapies. For details, see table 1.

Treatment

All patients were treated with FAE in tablet form starting with the low-strength formulation (Fumaderm[®] initial: 30 mg dimethylfumarate, 67 mg monoethyl fumarate Ca salt, 5 mg monoethylfumarate Mg salt, 3 mg monoethylfumarate Zn salt) followed by

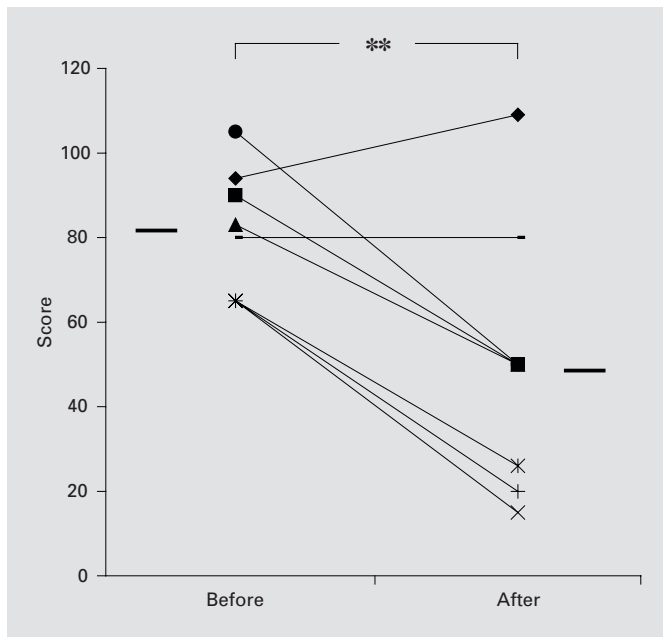


Fig. 1. Changes of colour before and after FAE treatment in patients with disseminated granuloma annulare as determined by visual analogue scale. Single cases and mean (■), n = 8, **p < 0.01.

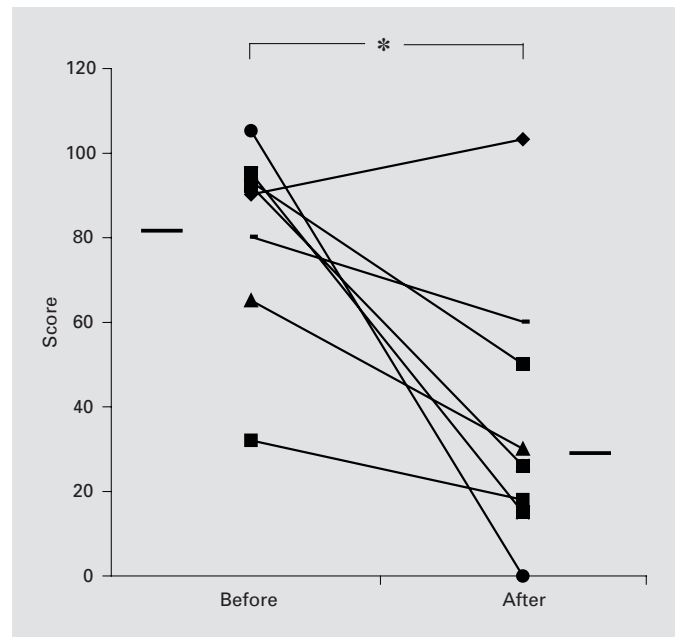


Fig. 2. Changes of elevation before and after FAE treatment in patients with disseminated granuloma annulare as determined by visual analogue scale. Single cases and mean (■), n = 8, *p < 0.05.

the high-strength tablets (Fumaderm®: 120 mg dimethylfumarate, 87 mg monoethyl fumarate Ca salt, 5 mg monoethylfumarate Mg salt, 3 mg monoethylfumarate Zn salt; Fumedica GmbH, Herne, Germany). The dosage of FAE was performed according to the standard therapy regimen for psoriasis patients (first week: 1 tablet of the low-strength formulation; second week: 2 tablets of the low-strength formulation; third week: 3 tablets of the low-strength formulation; following weeks: starting with 1 tablet of the high-strength formulation per week up to a maximum dose of 6 high-strength tablets in the ninth week).

Regular laboratory investigations including serum creatinine, blood urea and nitrogen, serum glutamic oxaloacetic transaminase, serum glutamic pyruvic transaminase, γ -glutamyl transpeptidase, uric acid, lactate dehydrogenase, alkaline phosphatase, choline esterase, bilirubin, electrolytes, urine chemistry and complete haematological values with differential blood count were done.

Outcome

Before, during and after therapy the patients were assessed by two investigators for clinical improvement. The colour and the elevation of the skin lesions were assessed by a visual analogue scale reaching from 0 to 120. Means and standard deviations before and after treatment were calculated. Remission was defined as complete clearance of all lesions, partial remission as reduction of elevation and redness. The statistical analysis of the data was done using the t test; p < 0.05 was considered significant.

Results

Three out of the 8 patients showed a remission, 4 a partial remission and 1 patient remained unchanged. The colour decreased from 80.1 ± 15.1 to 50 ± 31.8 (p < 0.01) and the elevation from 81.5 ± 23.2 to 37.75 ± 32.6 (p < 0.05) on the visual analogue scale. The duration of treatment varied between 1 and 8 months (mean: 4.3 ± 2.4 months). The patients with a total remission took the tablets for a longer time (mean: 6.2 ± 3.4 months) than those with a partial remission (mean: 3.3 ± 2.1 months). First signs of amelioration were seen after the third week of therapy with the low-strength formulation. The maximum intake of the high-strength tablets varied between 1 and 6 tablets. The patients with a total remission took more tablets (mean: 5.3 ± 1.2 tablets, range 4–6 tablets) than those with a partial remission (mean: 2.0 ± 1.2 tablets, range 1–3 tablets).

Unwanted side-effects were seen in 6 out of the 8 patients, mainly diarrhoea, dizziness, nausea, flush and stomach pain. Because of these side-effects, 4 patients (No. 1, 2, 3 and 8) discontinued the therapy (fig. 1, 2; table 1).

Table 1. Characteristics of patients (all female) with disseminated granuloma annulare undergoing systemic therapy with FAE

Patient No.	Age years	Duration of disease	Previous treatments	Maximum daily in-take of Fumaderm tablets	Duration of treatment months	Side-effects	Outcome
1	72	8 months	topical steroids, acupuncture	2	3	diarrhoea, dizziness	unchanged
2	19	10 years	topical vitamin E	1	3	nausea	partial remission
3	65	1 year	oral vitamin C	3	3	dizziness	partial remission
4	54	3 months	topical steroids	6	7	diarrhoea	remission
5	35	3 years	none	4	3.5	none	remission
6	62	7 years	systemic steroids	6	8	none	remission
7	42	39 years	topical steroids, UVA-1 therapy	3	6	flush	partial remission
8	61	13 years	topical steroids, PUVA therapy	1	1	stomach pain	partial remission

Discussion

Administration of FAE induced a significant reduction of colour and elevation in patients with disseminated granuloma annulare. The most striking effect with complete remission was seen in those patients taking 4 or more tablets of the high-strength formulation. These results are partly in concordance with the 2 published case reports about treatment of disseminated granuloma annulare with FAE. One 40-year-old woman received a maximum of 3 high-strength tablets, and the skin lesions improved after a 3-month therapy [1]. Another 64-year-old woman showed an almost complete remission after 5 weeks of treatment with 3 low-strength FAE tablets [2]. Similar doses and durations of treatment with FAE did not induce a total remission in all our patients (No. 2, 3, 7, 8), but an amelioration was seen in all but one patient (No. 1).

Granuloma annulare is a granulomatous skin disease of unknown origin with typical histological features. The granulomatous infiltrate is characterized by the palisading infiltration of mononuclear cells around degraded collagen fibres and mucin infiltration. The composition of the mononuclear infiltrate is variable, but T lymphocytes (mostly CD4+ cells) have been found in significant numbers. It could be shown that the high local production of interleukin 2 might play an important role in the non-specific attraction of T cells to the granulomatous site [3].

A number of plants contain fumaric acid, e.g. fumatory or earth smoke (*Fumaria officinalis*). As the enteral absorption of fumaric acid itself is very low, esters of fumaric acid are used for therapy. FAE have immunomodulatory properties with positive therapeutic effects in patients with psoriasis vulgaris [4–7]. As mode of action,

among others, an inhibition of lymphocyte proliferation and cytokine secretion is discussed. FAE appear to shift a T-helper-cell-1-directed immune response (characterized by interferon γ and interleukin 12 secretion) towards a T helper cell 2 type of immune response (characterized by interleukin 4 and interleukin 5 secretion) [8–10]. Granuloma annulare has been suggested to represent a delayed-type hypersensitivity reaction [11]. Interestingly other granulomatous skin diseases such as annular elastolytic giant cell granuloma, necrobiosis lipoidica and recalcitrant cutaneous sarcoidosis were reported to be effectively treated by FAE [12–14].

Despite amelioration of the skin disease, side-effects led to a withdrawal from FAE treatment in 4 patients. Adverse events of FAE therapy mainly consist of gastrointestinal complaints, which occur in more than two thirds of patients. The symptoms vary from mild stomach upsets, increased frequency of stools and tenesmus, to stomach cramps, tympanites and diarrhoea. Flushing is seen in about one third of patients treated with FAE. Symptoms include a sudden redness of the skin and a sensation of heat lasting between a few minutes and a few hours [5].

Taken together, our data suggest that a high-dose therapy with FAE has favourable effects on disseminated granuloma annulare, but that the gastro-intestinal side-effects of FAE may prevent administration of such doses in several patients.

References

- 1 Kreuter A, Gambichler T, Altmeyer P, Brockmeyer NH: Treatment of disseminated granuloma annulare with fumaric acid esters. *BMC Dermatol* 2002;2:5.
- 2 Schulze-Dirks A, Petzold D: Granuloma annulare disseminatum – Erfolgreiche Therapie mit Fumarsäureester. *Hautarzt* 2001;52:228–230.
- 3 Mempel M, Musette P, Flageul B, Schnopp C, Remling R, Gachelin G, Kourilsky P, Ring J, Abeck D: T-cell receptor repertoire and cytokine pattern in granuloma annulare: Defining a particular type of cutaneous granulomatous inflammation. *J Invest Dermatol* 2002;118:957–966.
- 4 Altmeyer PJ, Matthes U, Pawlak F, Hoffmann K, Frosch PJ, Ruppert P, Wassilew SW, Horn T, Kreysel HW, Lutz G, Barth J, Rietzschel I, Joshi RK: Antipsoriatic effect of fumaric acid derivatives: Results of a multicenter double-blind study in 100 patients. *J Am Acad Dermatol* 1994;30:977–981.
- 5 Mrowietz U, Christophers E, Altmeyer P for the German fumaric acid ester consensus conference: Treatment of severe psoriasis with fumaric acid esters: Scientific background and guidelines for therapeutic use. *Br J Dermatol* 1999;141:424–429.
- 6 Mrowietz U, Christophers E, Altmeyer P and the participants in the German multicenter study: Treatment of psoriasis with fumaric acid esters: Results of a prospective multicentre study. *Br J Dermatol* 1998;138:456–460.
- 7 Gollnick H, Altmeyer P, Kaufmann R, Ring J, Christophers E, Pavel S, Ziegler J: Topical calcipotriol plus oral fumaric acid is more effective and faster acting than oral fumaric acid monotherapy in the treatment of severe chronic plaque psoriasis vulgaris. *Dermatology* 2002;205:46–53.
- 8 Höxtermann S, Nüchel C, Altmeyer P: Fumaric acid esters suppress peripheral CD4- and CD8-positive lymphocytes in psoriasis. *Dermatology* 1998;196:223–230.
- 9 de Jong R, Bezemer AC, Zomerdijk TP, van de Pouw-Kraan T, Ottenhoff TH, Nibbering PH: Selective stimulation of T helper 2 cytokine responses by the anti-psoriasis agent monomethylfumarate. *Eur J Immunol* 1996;26:1067–1074.
- 10 Ockenfels HM, Schultewolter T, Ockenfels G, Funk R, Goos M: The anti-psoriatic agent dimethylfumarate immunomodulates T-cell cytokine secretion and inhibits cytokines of the psoriatic cytokine network. *Br J Dermatol* 1998;139:390–395.
- 11 Fayyazi A, Schweyer S, Eichmeyer B, Herms J, Hemmerlein B, Radzun HJ, Berger H: Expression of IFN γ , coexpression of TNF α and matrix metalloproteinases and apoptosis of T lymphocytes and macrophages in granuloma annulare. *Arch Dermatol Res* 2000;292:384–390.
- 12 Nowack U, Gambichler T, Hanefeld C, Kastner U, Altmeyer P: Successful treatment of recalcitrant cutaneous sarcoidosis with fumaric acid esters. *BMC Dermatol* 2002;2:15.
- 13 Gutzmer R, Breuer K, Kiehl P, Kapp A, Werfel T: Successful therapy of annular elastolytic giant cell granuloma with fumaric acid esters. *Dermatology* 2002;205:421–424.
- 14 Gambichler T, Kreuter A, Freitag M, Pawlak FM, Brockmeyer NH, Altmeyer P: Clearance of necrobiosis lipoidica with fumaric acid esters. *Dermatology* 2003;207:422–424.