

REVIEW

Open Access



Systemic therapy of necrobiotic xanthogranuloma: a systematic review

Lisa Steinhelfer^{1,2,3}, Thomas Kühnel⁴, Herbert Jäggle⁵, Stephanie Mayer⁶, Sigrid Karrer¹, Frank Haubner⁷ and Stephan Schreml^{1*} 

Abstract

Background: Even though a plethora of systemic therapies have been proposed for necrobiotic xanthogranuloma (NXG), there is no systematic review on this topic in literature.

Objective: To review all existing literature on the systemic therapy of NXG in order to identify the most effective therapies.

Methods: All reported papers in the literature were screened for systemic treatments of NXG. Papers without proper description of the therapies, papers describing topical therapy, and articles without assessment of effectiveness were excluded. Subsequently, we analyzed 79 papers and a total of 175 cases.

Results: The most effective treatments for NXG are intravenous immunoglobulins (IVIG), corticosteroids, and combination therapies including corticosteroids.

Conclusions: Corticosteroids and IVIG should therefore be considered first-line treatments in patients with NXG.

Keywords: Necrobiotic xanthogranuloma, Non-Langerhans cell histiocytosis, Systemic therapy, Necrobiotic xanthogranuloma and therapy

Background

Necrobiotic xanthogranuloma (NXG) was first described by Kossard and Winkelmann in 1980 and is a rare non-Langerhans cell histiocytosis with no gender preference. The disease mostly affects patients in the sixth decade of life and is associated with cell proliferative disorders, such as multiple myeloma (MM) or monoclonal gammopathy of undetermined significance (MGUS). The etiopathogenesis of necrobiotic xanthogranuloma is unknown. However, It is conceivable that paraproteins play a role as a trigger or cofactor for granuloma formation [1–4] (more background information in Additional file 1). NXG often initially presents with yellowish or

brownish macules and nodules. As the disease progresses, atrophies, telangiectasias, ulcerations and scars may be present within the lesions [5]. The lesions are usually asymptomatic and often appear in the periorbital area. In a few cases, systemic involvement was found in autopsies [6–8]. The most common extracutaneous localizations comprise the oropharyngeal tract, the bronchi, liver, spleen, lung and heart [9–13]. Histopathologically, NXG is characterized by granulomas in the dermis extending into the subcutaneous fat. Atypical foreign body giant cells of the Touton type are often found [14]. Cholesterol clefts are a hallmark of the disease [15] (also see Additional file 1). Due to the rarity of NXG, mostly case reports and case series exist. A lot of patients with NXG will receive several drugs before getting proper treatment.

*Correspondence: Stephan.schreml@ukr.de

¹ Department of Dermatology, University Medical Center Regensburg, Franz-Josef-Strauß-Allee 11, 93053 Regensburg, Germany
Full list of author information is available at the end of the article



Materials and methods

Eligibility criteria

Studies were included when patients were at least 18 years old and diagnosis was histologically confirmed. We screened cohort studies, case-control studies, case series, case reports and letters that clearly reported the outcome of the respective systemic treatments. As we focused on systematic therapies, papers dealing with topical treatments were excluded. In addition, some articles were removed due to duplicate information. Studies were checked for eligibility by the first author, and then results were reviewed by the last author.

Information sources/study selection

A review by Miguel et al. helped to identify relevant cases from 1980 to 2014. Only patients who had received systemic therapy were included. As a second step, we searched PubMed, Medline and Web of Science databases using the queries “necrobiotic xanthogranuloma and therapy” until 2021. Following the database search, studies were compiled into a single list with all duplicates removed. Further exclusion criteria were studies with aggregated data, an unclear diagnosis, only topical treatment mentioned, no proper description of treatment, or response to treatment not mentioned.

Outcome assessment

The primary outcome was the reported response to systemic treatment in the papers. These were classified as “complete response”, “partial response”, “stable disease” or “progressive disease”. The response to therapy was evaluated by reviewing each patient’s medical record (as reported). Complete response to treatment was used for the absence of all detectable NXG lesions and stable hematological symptoms. Partial response was defined as a decrease in the size or number of NXG lesions and an improvement of the hematological symptoms. Stable disease was defined as no change in the size or number of the NXG lesions and stable hematological symptoms. Progressive disease was defined as an increase in the size or number of the NXG lesions or worsening of the hematological condition. In mixed response scenarios (reduction in size or regression of individual lesions with simultaneous appearance of new lesions), we rated as “progressive disease”. The sole response of cutaneous lesions with simultaneous progression of the hematological condition, or vice versa, were also rated as “progressive disease”.

Results

Study identification

The review by Miguel et al. helped to identify 101 patients [1–3, 14–59]. The additional literature search

yielded 45 records. After removal of duplicates, 39 papers were subject to fulltext-review. 13 records were excluded: 6 did not discuss systemic treatment of NXG, a further 2 did not report any treatment, another study provided ambiguous information on treatment, 3 studies discussed an alternative diagnosis to NXG and another study failed to mention the response to treatment. A total of 26 studies were included based on the above-mentioned criteria. These 26 articles present the therapy options and the course of therapy of 69 patients [4, 60–84]. 5 institutional patients (University Medical Center Regensburg) were included (Table 1, see Additional file 1). We were thus able to assess the outcome of systemic therapies in 79 studies and 175 patients (Fig. 1, representative institutional case in Fig. 2).

Bias and quality assessment

Most of the studies were case reports and some were case series and the sample size of all studies was small. Since a scale for severity of NXG does not exist, clinical response is difficult to classify. In our systematic review, clinical response is essentially based on the individual report of each author. This makes a comparative statements difficult, which is a limitation of the study. All studies were uncontrolled, leading to a high risk of confounding. Due to the lack of randomization, the risk of selection bias was high. Risk of reporting bias was high due to lack of blinding. It is difficult to comment on publication bias, however, as the main part of evidence is from case reports, the question arises whether ineffective therapies have been published in the same way as effective ones.

Patient demographics

The most common association between NXG and hematologic disorders has been with plasma cell dyscrasias. Of the 175 patients, 95 patients had paraproteinemia (55%). The most common subtype was IgG-kappa. 19 of 175 (11%) patients had a malignant condition: Multiple myeloma, in 12 patients (7%), was the most common type. However, Hodgkin lymphoma and chronic lymphatic leukemia (CLL) were also observed. The overall percentage of patients with simultaneous paraproteinemia and/or a malignant condition was 65% (114 patients).

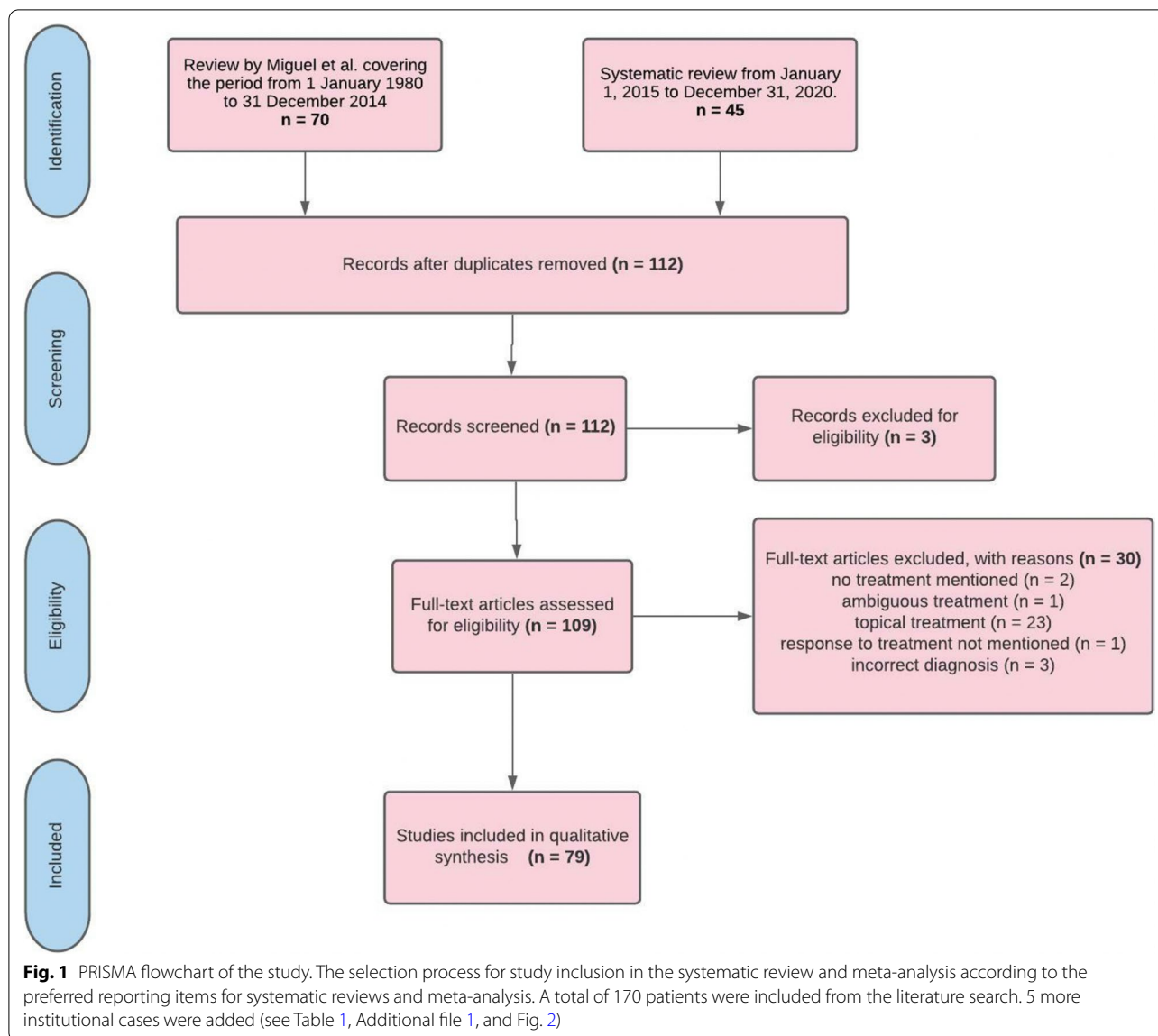
Systemic therapies

Different treatments have been used for NXG with a wide variety of responses, such corticosteroids, IVIG, lenalidomide, cyclophosphamide, chlorambucil, thalidomide, melphalan, infliximab/rituximab, cladribine, bortezomib, vincristine, interferon alpha-2a, dapsone, ibarubicin, adalimumab, etretinate, cyclosporine, mycophenolate-mofetil, clofazimine, minocycline, doxycycline, acitretin, azathioprine and combined therapies (FCR,

Table 1 Clinical data of institutional case reports: For details, see Additional file 1

Case	Age	Cutaneous involvement	Organ involvement (extracutaneous)	Prior treatments	Latest treatment	Response	Follow up
1	59	Extensive ulcerations on both sides of the lower legs with erythematous wound edges	Whitish discoloration of right cornea, left eye sunken back into the orbita, purulent discharge bilaterally	None	Oral corticosteroids (prednisolone)	Partial response	3 months later her condition had deteriorated
2	61	Ulceration with destruction of the auricular lobe on the left ear	Double vision and visual disturbances (due to infiltration of the eye muscles)	(a) Intravenous immunoglobulins (IVIg) (b) Cytoreductive therapy with melphalan	Chlorambucil and oral corticosteroids (prednisolone)	Partial response	> 12 months progression free (survival)
3	72	Generalized cutaneous and subcutaneous lesions	Osseous involvement, mediastinal and hilar lymph node involvement on both sides, bilateral involvement of the lung	(a) Cytoreductive therapy with melphalan (b) lenalidomide in combination with dexamethasone	Dapsone and oral corticosteroids (prednisolone)	Partial response	> 12 months progression free (survival)
4	69	Ulceration of the chest, the neck and the periorbital region	Vestibular and cochlear involvement, olfactory system was also involved	Lenalidomide (stopped because of pronounced leukocytosis)	Lenalidomide (reduced dose of 5 mg/day) and oral corticosteroids (prednisolone)	Stable disease	3 months later her condition had deteriorated
5	67	Bilateral yellowish swelling of both upper and lower eyelid	None	None	Oral corticosteroids (dexamethasone, tapered slowly to Cushing threshold)	Partial response	> 12 months progression free (survival)

Images from Case 2 are given in Fig. 2



RCVP, vincristine/melphalan/cyclophosphamide/prednisolone).

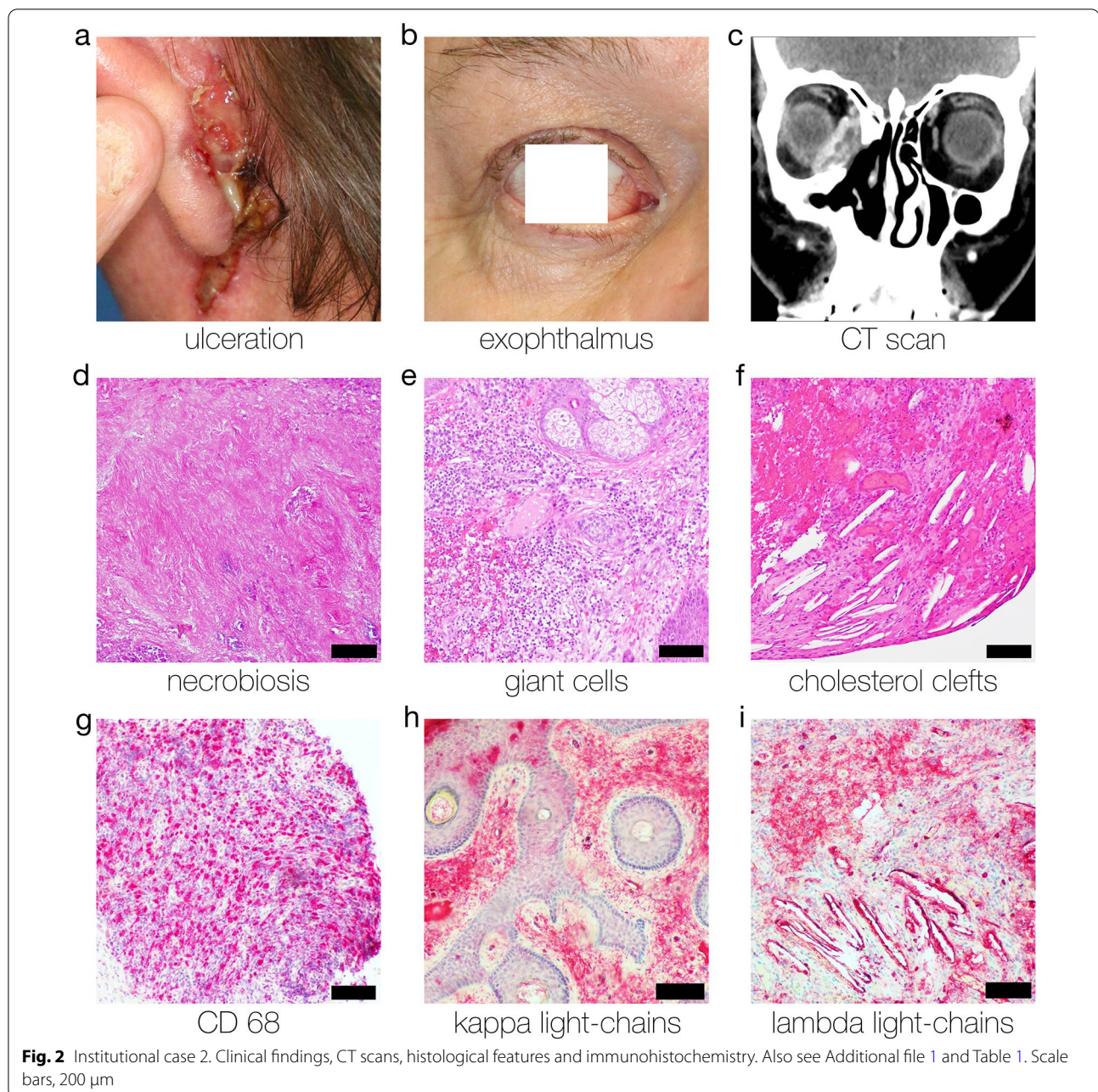
Effect of interventions

The effect of treatments administered are presented in Fig. 3. Corticosteroids were the most frequently used treatment for NXG. Corticosteroids were used in 45 cases. Complete response occurred in 5 patients (11%), and partial response in 9 patients (20%), stable disease was achieved in 16 patients (36%) and progressive disease was observed in 15 patients (33%). The use of IVIG turned out to be the most effective therapy. IVIG were used in 26 patients. Complete response was achieved in 7 patients (27%) and partial response in 14 patients (54%). Two patients exhibited stable disease (8%) and three

patients did not respond to the therapy (11%). Another sufficient therapy option was the use of lenalidomide in combination or without corticosteroids. Complete response was observed in 4 patients (18%) and partial response in 7 patients (32%). Six patients (27%) achieved partial response and no response was noticed in five patients (23%).

The overall response was improvement (complete response and partial response) in 128 patients (73%) and stable disease in 25 patients. 22 (13%) patients showed progress of disease.

Since patient data were collected from individual case reports, follow-up data were only occasionally available. The duration of response was set to be at least the timespan reported in the case reports in case patients



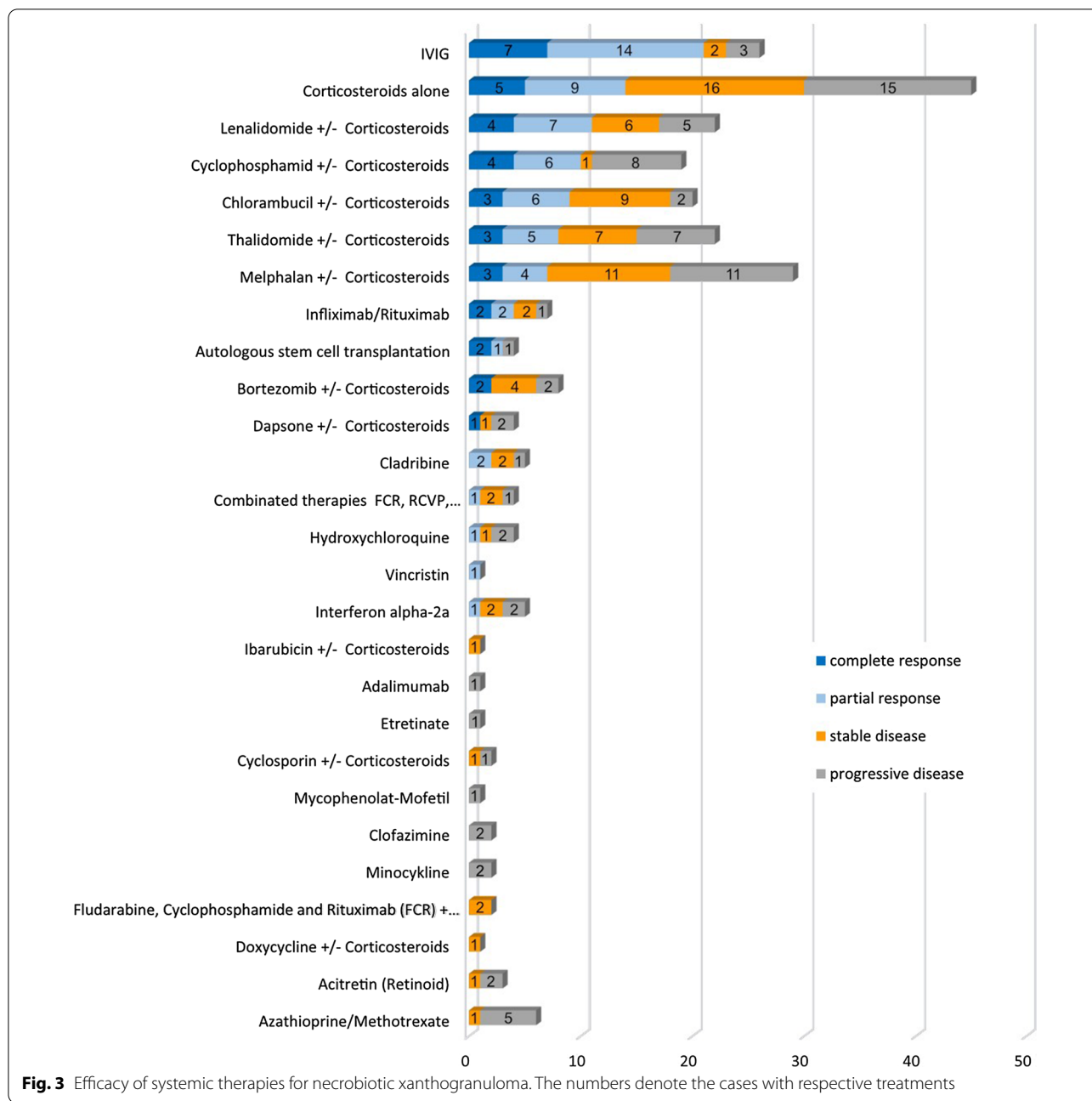
were either lost to follow-up or no other information was given.

Of the 26 patients treated with IVIG, follow-up data were available for 8 patients. The median duration of response (2 patients with complete response and 6 patients with partial response) for the 8 patients was 12 months (range 6–48 months, mean 15.75 months). Furthermore, we wanted to illustrate the follow-up data of the second promising therapy, the use of corticosteroids. Of the 45 patients treated with corticosteroids,

follow-up data were available for 10 patients. The median duration of response (4 patients with complete response, 5 patients with partial response and 1 patients with stable disease) for the 10 patients was 12 months (range 2–24 months, mean 11.9 months).

Discussion

This study provides a systematic review on the systemic treatment of NXG. IVIG had the best response rate (21 of 26 patients [81%] with complete or partial



response), followed by corticosteroids (30 of 45 patients [67%] showed response or stable disease), and lenalidomide in combination, or without corticosteroids (17 of 22 patients [77%]). However, other therapeutic agents were frequently used in combination therapies. It is challenging to draw conclusions regarding the effectiveness of combination treatments due to the low number of reports for each combination. Furthermore, it is difficult to evaluate the response to therapy

as there is no standard rating scale for the severity of NXG. The clinical response or results are based on each author’s individual report. In conclusion, despite the notable limitations of the currently available data (case reports, rating system could be varied, interpretation of case report data), this systematic review suggests that the therapeutic use of IVIG and corticosteroids are the most promising drugs to achieve disease control in NXG. As there are still no clear guidelines in the

therapy of NXG, prospective, comparative, randomized controlled trials would be required to determine the best therapeutic approach. However, this will hardly be feasible due to the low number of cases.

Conclusions

Our study shows that the most effective treatments for NXG are intravenous immunoglobulins (IVIG), corticosteroids, and combination therapies including corticosteroids. Therefore corticosteroids and IVIG should be first-line treatments in patients with NXG.

Supplementary Information

The online version contains supplementary material available at <https://doi.org/10.1186/s13023-022-02291-z>.

Additional file 1. Supplementary information.

Acknowledgements

None.

Authors' contributions

Conceptualization, SS; methodology, LS, SS; formal analysis, LS, SS, writing—original draft preparation, LS and SS; writing—review and editing, TK, HJ, SM, SK, and FH. All authors have read and agreed to the published version of the manuscript.

Funding

Open Access funding enabled and organized by Projekt DEAL. This research received no external funding.

Availability of data materials

Available upon reasonable request.

Declarations

Ethics approval and consent to participate

No identifiable patient data was included. Therefore, no ethics approval was necessary. Patients can not be identified, therefore not applicable.

Consent for publication

Patients can not be identified, therefore not applicable.

Competing interests

The authors have no competing interests.

Author details

¹Department of Dermatology, University Medical Center Regensburg, Franz-Josef-Strauß-Allee 11, 93053 Regensburg, Germany. ²Department of Nuclear Medicine, Technical University Munich, Ismaninger Strasse 22, 81675 Munich, Germany. ³Department of Radiology, Technical University Munich, Ismaninger Strasse 22, 81675 Munich, Germany. ⁴Department of Otorhinolaryngology, University Medical Center Regensburg, Franz-Josef-Strauß-Allee 11, 93053 Regensburg, Germany. ⁵Department of Ophthalmology, University Medical Center Regensburg, Franz-Josef-Strauß-Allee 11, 93053 Regensburg, Germany. ⁶Department of Internal Medicine III, University Medical Center Regensburg, Franz-Josef-Strauß-Allee 11, 93053 Regensburg, Germany. ⁷Department of Otorhinolaryngology, Ludwig Maximilians University Munich, Marchioninistr. 15, 81377 Munich, Germany.

Received: 26 December 2021 Accepted: 14 March 2022

Published online: 24 March 2022

References

- Kossard S, Winkelmann RK. Necrobiotic xanthogranuloma. *Australas J Dermatol.* 1980;21:85–8. <https://doi.org/10.1111/j.1440-0960.1980.tb00148.x>.
- Chave TA, Chowdhury MM, Holt PJ. Recalcitrant necrobiotic xanthogranuloma responding to pulsed high-dose oral dexamethasone plus maintenance therapy with oral prednisolone. *Br J Dermatol.* 2001;144:158–61. <https://doi.org/10.1046/j.1365-2133.2001.03967.x>.
- Silapunt S, Chon SY. Generalized necrobiotic xanthogranuloma successfully treated with lenalidomide. *J Drugs Dermatol.* 2010;9:273–6.
- Dholaria BR, Cappel M, Roy V. Necrobiotic xanthogranuloma associated with monoclonal gammopathy: successful treatment with lenalidomide and dexamethasone. *Ann Hematol.* 2016;95:671–2. <https://doi.org/10.1007/s00277-016-2604-3>.
- Gun D, Demircay Z, Demirkesen C. Necrobiotic xanthogranuloma in a burn scar. *Int J Dermatol.* 2004;43:293–5. <https://doi.org/10.1111/j.1365-4632.2004.01858.x>.
- Umbert I, Winkelmann RK. Necrobiotic xanthogranuloma with cardiac involvement. *Br J Dermatol.* 1995;133:438–43. <https://doi.org/10.1111/j.1365-2133.1995.tb02674.x>.
- Hunter L, Burry AF. Necrobiotic xanthogranuloma: a systemic disease with paraproteinemia. *Pathology.* 1985;17:533–6. <https://doi.org/10.3109/00313028509105517>.
- Frank SB, Weidman AI. Xanthoma disseminatum; an unusual form with extension of xanthomatous changes into muscle. *AMA Arch Derm Syphilol.* 1952;65:88–94. <https://doi.org/10.1001/archderm.1952.01530200092013>.
- Novak PM, Robbins TO, Winkelmann RK. Necrobiotic xanthogranuloma with myocardial lesions and nodular transformation of the liver. *Hum Pathol.* 1992;23:195–6. [https://doi.org/10.1016/0046-8177\(92\)90244-w](https://doi.org/10.1016/0046-8177(92)90244-w).
- Winkelmann RK, Litzow MR, Umbert IJ, Lie JT. Giant cell granulomatous pulmonary and myocardial lesions in necrobiotic xanthogranuloma with paraproteinemia. *Mayo Clin Proc.* 1997;72:1028–33. <https://doi.org/10.4065/72.11.1028>.
- Mehregan DA, Winkelmann RK. Necrobiotic xanthogranuloma. *Arch Dermatol.* 1992;128:94–100.
- Spicknall KE, Mehregan DA. Necrobiotic xanthogranuloma. *Int J Dermatol.* 2009;48:1–10. <https://doi.org/10.1111/j.1365-4632.2009.03912.x>.
- Rose A, Robinson M, Kamino H, Latkowski JA. Necrobiotic xanthogranuloma. *Dermatol Online J.* 2012;18:30.
- Wood AJ, Wagner MV, Abbott JJ, Gibson LE. Necrobiotic xanthogranuloma: a review of 17 cases with emphasis on clinical and pathologic correlation. *Arch Dermatol.* 2009;145:279–84. <https://doi.org/10.1001/archdermatol.2008.583>.
- Hallermann C, Tittelbach J, Norgauer J, Ziemer M. Successful treatment of necrobiotic xanthogranuloma with intravenous immunoglobulin. *Arch Dermatol.* 2010;146:957–60. <https://doi.org/10.1001/archdermatol.2010.236>.
- Miguel D, Lukacs J, Illing T, Elsner P. Treatment of necrobiotic xanthogranuloma—a systematic review. *J Eur Acad Dermatol Venereol.* 2017;31:221–35. <https://doi.org/10.1111/jdv.13786>.
- Chang SE, Lee WS, Lee MW, Choi JH, Sung KJ, Moon KC, Koh JK. A case of necrobiotic xanthogranuloma without paraproteinemia presenting as a solitary tumor on the thigh. *Int J Dermatol.* 2003;42:470–2. https://doi.org/10.1046/j.1365-4362.2003.01716_1.x.
- Codere F, Lee RD, Anderson RL. Necrobiotic xanthogranuloma of the eyelid. *Arch Ophthalmol.* 1983;101:60–3. <https://doi.org/10.1001/archophth.1983.01040010062009>.
- Criado PR, Vasconcellos C, Pegas JR, Lopes LF, Ramos CF, Tebcherani AJ, Valente NY. Necrobiotic xanthogranuloma with lambda paraproteinemia: case report of successful treatment with melphalan and prednisone. *J Dermatolog Treat.* 2002;13:87–9. <https://doi.org/10.1080/095466302317584458>.
- Criton S, Asokan PU, Pailey S, Kuttappan SS, Rodriguez FP. Necrobiotic xanthogranuloma with paraproteinaemia. *Indian J Dermatol Venereol Leprol.* 1996;62:383–5.
- Efebera Y, Blanchard E, Allam C, Han A, Lee S, Munshi N. Complete response to thalidomide and dexamethasone in a patient with necrobiotic xanthogranuloma associated with monoclonal gammopathy:

- a case report and review of the literature. *Clin Lymphoma Myeloma Leuk*. 2011;11:298–302. <https://doi.org/10.1016/j.clml.2011.03.020>.
22. Finan MC, Winkelmann RK. Necrobiotic xanthogranuloma with paraproteinemia. A review of 22 cases. *Medicine (Baltimore)*. 1986;65:376–88. <https://doi.org/10.1097/00005792-198611000-00003>.
 23. Finelli LG, Ratz JL. Plasmapheresis, a treatment modality for necrobiotic xanthogranuloma. *J Am Acad Dermatol*. 1987;17:351–4. [https://doi.org/10.1016/s0190-9622\(87\)70211-4](https://doi.org/10.1016/s0190-9622(87)70211-4).
 24. Flann S, Wain EM, Halpern S, Andrews V, Whittaker S. Necrobiotic xanthogranuloma with paraproteinaemia. *Clin Exp Dermatol*. 2006;31:248–51. <https://doi.org/10.1111/j.1365-2230.2005.02042.x>.
 25. Gacto P, Barrera F, Pereyra JJ, Fernandez-Ortega P. Necrobiotic xanthogranuloma: efficacy of surgery in 2 patients. *Actas Dermosifiliogr*. 2009;100:499–502.
 26. Ghani S, Al Ustwani O, Khalid B, Bogner P, Grassi M, Powell J, Bhat SA. Periorbital necrobiotic xanthogranuloma treated successfully with novel multiple myeloma therapy. *Clin Adv Hematol Oncol*. 2013;11:678–80.
 27. Ghiasi N, Alavi A, Coutts PM, Ghazarian D, Sibbald RG. Necrobiotic xanthogranuloma as an unusual cause of refractive chronic bilateral leg ulceration. *Int J Low Extrem Wounds*. 2012;11:293–5. <https://doi.org/10.1177/1534734612465434>.
 28. Goede JS, Misselwitz B, Taverna C, Schanz U, Dispenzieri A, Hummel Y, Trueb RM, Fehr J. Necrobiotic xanthogranuloma successfully treated with autologous stem cell transplantation. *Ann Hematol*. 2007;86:303–6. <https://doi.org/10.1007/s00277-006-0231-0>.
 29. Hauser C, Schifferli J, Saurat JH. Complement consumption in a patient with necrobiotic xanthogranuloma and paraproteinemia. *J Am Acad Dermatol*. 1991;24:908–11. [https://doi.org/10.1016/0190-9622\(91\)70145-r](https://doi.org/10.1016/0190-9622(91)70145-r).
 30. Holden CA, Winkelmann RK, Wilson Jones E. Necrobiotic xanthogranuloma: a report of four cases. *Br J Dermatol*. 1986;114:241–50. <https://doi.org/10.1111/j.1365-2133.1986.tb02804.x>.
 31. Kawakami Y, Yamamoto T. Letter: necrobiotic xanthogranuloma of extremities in an elderly patient successfully treated with low-dose prednisolone. *Dermatol Online J*. 2011;17:13.
 32. Khan IJ, Azam NA, Sullivan SC, Habboush HW, Christian A. Necrobiotic xanthogranuloma successfully treated with a combination of dexamethasone and oral cyclophosphamide. *Can J Ophthalmol*. 2009;44:335–6. <https://doi.org/10.3129/09-021>.
 33. Liszewski W, Wisniewski JD, Safah H, Boh EE. Treatment of refractory necrobiotic xanthogranulomas with extracorporeal photopheresis and intravenous immunoglobulin. *Dermatol Ther*. 2014;27:268–71. <https://doi.org/10.1111/dth.12135>.
 34. Luck J, Layton A, Noble BA. Necrobiotic xanthogranuloma with orbital involvement. *J R Soc Med*. 1992;85:357–8.
 35. Macfarlane AW, Verbov JL. Necrobiotic xanthogranuloma with paraproteinaemia. *Br J Dermatol*. 1985;113:339–43. <https://doi.org/10.1111/j.1365-2133.1985.tb02087.x>.
 36. Machado S, Alves R, Lima M, Leal I, Massa A. Cutaneous necrobiotic xanthogranuloma (NXG)-successfully treated with low dose chlorambucil. *Eur J Dermatol*. 2001;11:458–62.
 37. Meyer S, Szeimies RM, Landthaler M, Hohenleutner S. Cyclophosphamide-dexamethasone pulsed therapy for treatment of recalcitrant necrobiotic xanthogranuloma with paraproteinemia and ocular involvement. *Br J Dermatol*. 2005;153:443–5. <https://doi.org/10.1111/j.1365-2133.2005.06737.x>.
 38. Naghashpour M, Setoodeh R, Moscinski L, Bergier G, McCardle T, Glass F, Sokol L. Nonnecrobiotic necrobiotic xanthogranuloma as an initial manifestation of paraproteinemia and small lymphocytic lymphoma in a patient with Sjogren syndrome. *Am J Dermatopathol*. 2011;33:855–7. <https://doi.org/10.1097/DAD.0b013e3182051fce>.
 39. Oumeish OY, Oumeish I, Tarawneh M, Salman T, Sharaiha A. Necrobiotic xanthogranuloma associated with paraproteinemia and non-Hodgkin's lymphoma developing into chronic lymphocytic leukemia: the first case reported in the literature and review of the literature. *Int J Dermatol*. 2006;45:306–10. <https://doi.org/10.1111/j.1365-4632.2006.02575.x>.
 40. Plotnick H, Taniguchi Y, Hashimoto K, Negendank W, Tranchida L. Periorbital necrobiotic xanthogranuloma and stage I multiple myeloma. Ultrastructure and response to pulsed dexamethasone documented by magnetic resonance imaging. *J Am Acad Dermatol*. 1991;25:373–7. [https://doi.org/10.1016/0190-9622\(91\)70208-j](https://doi.org/10.1016/0190-9622(91)70208-j).
 41. Rayner SA, Duncombe AS, Keefe M, Theaker J, Manners RM. Necrobiotic xanthogranuloma occurring in an eyelid scar. *Orbit*. 2008;27:191–4. <https://doi.org/10.1080/01676830701804057>.
 42. Reddy VC, Salomao DR, Garrity JA, Baratz KH, Patel SV. Periorbital and ocular necrobiotic xanthogranuloma leading to perforation. *Arch Ophthalmol*. 2010;128:1493–4. <https://doi.org/10.1001/archophthalmol.2010.254>.
 43. Reeder CB, Connolly SM, Winkelmann RK. The evolution of Hodgkin's disease and necrobiotic xanthogranuloma syndrome. *Mayo Clin Proc*. 1991;66:1222–4. [https://doi.org/10.1016/s0025-6196\(12\)62473-2](https://doi.org/10.1016/s0025-6196(12)62473-2).
 44. Rose GE, Patel BC, Garner A, Wright JE. Orbital xanthogranuloma in adults. *Br J Ophthalmol*. 1991;75:680–4. <https://doi.org/10.1136/bjo.75.11.680>.
 45. Rubinstein A, Wolf DJ, Granstein RD. Successful treatment of necrobiotic xanthogranuloma with intravenous immunoglobulin. *J Cutan Med Surg*. 2013;17:347–50. <https://doi.org/10.2310/7750.2013.13012>.
 46. Ryan E, Warren LJ, Szabo F. Necrobiotic xanthogranuloma: response to chlorambucil. *Australas J Dermatol*. 2012;53:e23–25. <https://doi.org/10.1111/j.1440-0960.2010.00710.x>.
 47. Saeki H, Tomita M, Kai H, Ohno Y, Le Pavoux A, Kadono T, Tsunemi Y, Sakurai N, Asano Y, Tamaki K. Necrobiotic xanthogranuloma with paraproteinemia successfully treated with melphalan, prednisolone and skin graft. *J Dermatol*. 2007;34:795–7. <https://doi.org/10.1111/j.1346-8138.2007.00387.x>.
 48. Shah KC, Poonnoose SI, George R, Jacob M, Rajshekhar V. Necrobiotic xanthogranuloma with cutaneous and cerebral manifestations. Case report and review of the literature. *J Neurosurg*. 2004;100:1111–4. <https://doi.org/10.3171/jns.2004.100.6.1111>.
 49. Spraul CW, Wagner P, Lang GK. Bilateral necrobiotic xanthogranuloma of the eyelids with associated paraproteinemia: case report and review of literature. *Klin Monbl Augenheilkd*. 2002;219:55–8. <https://doi.org/10.1055/s-2000-23502>.
 50. Sutton L, Sutton S, Sutton M. Treatment of necrobiotic xanthogranuloma with 2-chlorodeoxyadenosine. *Skinmed*. 2013;11:121–3.
 51. Szalat R, Pirault J, Fermand JP, Carrie A, Saint-Charles F, Olivier M, Robillard P, Frisdal E, Villard EF, Cathebras P, et al. Physiopathology of necrobiotic xanthogranuloma with monoclonal gammopathy. *J Intern Med*. 2014;276:269–84. <https://doi.org/10.1111/joim.12195>.
 52. Torabian SZ, Fazel N, Knuttel R. Necrobiotic xanthogranuloma treated with chlorambucil. *Dermatol Online J*. 2006;12:11.
 53. Ugurlu S, Bartley GB, Gibson LE. Necrobiotic xanthogranuloma: long-term outcome of ocular and systemic involvement. *Am J Ophthalmol*. 2000;129:651–7. [https://doi.org/10.1016/s0002-9394\(99\)00469-9](https://doi.org/10.1016/s0002-9394(99)00469-9).
 54. Valentine EA, Friedman HD, Zamkoff KW, Streeten BW. Necrobiotic xanthogranuloma with IgA multiple myeloma: a case report and literature review. *Am J Hematol*. 1990;35:283–5. <https://doi.org/10.1002/ajh.2830350414>.
 55. Venencie PY, Le Bras P, Toan ND, Tcherna G, Delfraissy JF. Recombinant interferon alfa-2b treatment of necrobiotic xanthogranuloma with paraproteinemia. *J Am Acad Dermatol*. 1995;32:666–7. [https://doi.org/10.1016/0190-9622\(95\)90370-4](https://doi.org/10.1016/0190-9622(95)90370-4).
 56. Venencie PY, Puissant A, Verola O, Kerneis Y, Marchat C, Le Bras P, D'Agay MF, Danon F, Valensi F, Turpin G. Necrobiotic xanthogranuloma with myeloma. A case report. *Cancer*. 1987;59:588–92. [https://doi.org/10.1002/1097-0142\(19870201\)59:3%3c588::aid-cnrc2820590339%3e3.0.co;2-c](https://doi.org/10.1002/1097-0142(19870201)59:3%3c588::aid-cnrc2820590339%3e3.0.co;2-c).
 57. Wells J, Gillespie R, Zardawi I. Case of recalcitrant necrobiotic xanthogranuloma. *Australas J Dermatol*. 2004;45:213–5. <https://doi.org/10.1111/j.1440-0960.2004.00099.x>.
 58. Westermann G, August C, Bonsmann G, Rahn KH, Kisters K. Necrobiotic xanthogranuloma with skin and liver amyloidosis. *Med Klin (Munich)*. 2001;96:50–4. <https://doi.org/10.1007/pl00002153>.
 59. Ziemer M, Wedding U, Sander CS, Elsner P. Necrobiotic xanthogranuloma-rapid progression under treatment with melphalan. *Eur J Dermatol*. 2005;15:363–5.
 60. Dellatorre G, Miqueloto JK. Necrobiotic xanthogranuloma. *JAMA Dermatol*. 2020;156:696. <https://doi.org/10.1001/jamadermatol.2020.0897>.
 61. Gonzales JA, Haemel A, Gross AJ, Acharya NR. Management of uveitis and scleritis in necrobiotic xanthogranuloma. *J Ocul Pharmacol Ther*. 2017;33:325–33. <https://doi.org/10.1089/jop.2016.0135>.

62. Goyal A, O'Leary D, Vercellotti G, Miller D, McClave P. Intravenous immunoglobulin for treatment of necrobiotic xanthogranuloma. *Dermatol Ther.* 2019;32: e12744. <https://doi.org/10.1111/dth.12744>.
63. Guchlerner M, Brockmann MA, Pitz S. Periocular necrobiotic xanthogranuloma with mono- and biconal gammopathy. *Klin Monbl Augenheilkd.* 2020;237:41–5. <https://doi.org/10.1055/a-1032-8516>.
64. Henning C, Meyers S, Swift R, Eades B, Bussell L, Spektor TM, Berenson JR. Efficacy of topical use crisaborole 2% ointment for treatment of necrobiotic xanthogranuloma associated with multiple myeloma. *Clin Lymphoma Myeloma Leuk.* 2020;20:e492–5. <https://doi.org/10.1016/j.clml.2020.03.016>.
65. Higgins LS, Go RS, Dingli D, Kumar SK, Rajkumar SV, Dispenzieri A, Buadi FK, Lacy MQ, Lust JA, Kapoor P, et al. Clinical features and treatment outcomes of patients with necrobiotic xanthogranuloma associated with monoclonal gammopathies. *Clin Lymphoma Myeloma Leuk.* 2016;16:447–52. <https://doi.org/10.1016/j.clml.2016.04.009>.
66. Keorochana N, Klanarongran K, Satayasontorn K, Chaiannuay S. Necrobiotic xanthogranuloma scleritis in a case of granulomatosis with polyangiitis (Wegener's granulomatosis). *Int Med Case Rep J.* 2017;10:323–8. <https://doi.org/10.2147/IMCRJ.S145943>.
67. Klingner M, Hansel G, Schonlebe J, Wollina U. Disseminated necrobiotic xanthogranuloma. *Hautarzt.* 2016;67:902–6. <https://doi.org/10.1007/s00105-016-3839-6>.
68. Lee HJ, Kim JM, Kim GW, Kim HS, Kim MB, Ko HC. Necrobiotic xanthogranuloma treated with a combination of oral methylprednisolone and cyclosporin. *J Dermatol.* 2017;44:1190–1. <https://doi.org/10.1111/1346-8138.13648>.
69. Lopes S, Gomes N, Cesar A, Barros AM, Pinheiro J, Azevedo F. An exuberant case of necrobiotic xanthogranuloma. *Indian Dermatol Online J.* 2020;11:83–6. https://doi.org/10.4103/idoj.IDOJ_74_19.
70. Lukacs J, Goetze S, Elsner P. Periocular necrobiotic xanthogranuloma successfully treated with intravenous immunoglobulin. *Acta Derm Venereol.* 2017;97:754–5. <https://doi.org/10.2340/00015555-2626>.
71. Mahendran P, Wee J, Chong H, Natkunarajah J. Necrobiotic xanthogranuloma treated with lenalidomide. *Clin Exp Dermatol.* 2018;43:345–7. <https://doi.org/10.1111/ced.13293>.
72. Mello RB, Vale E. Necrobiotic xanthogranuloma associated with smoldering multiple myeloma: satisfactory response to cyclophosphamide, dexamethasone, and thalidomide. *Bras Dermatol.* 2019;94:337–40. <https://doi.org/10.1590/abd1806-4841.20198500>.
73. Nambudiri VE, McLaughlin C, Lo TC, Zembowicz A, Moschella S. Successful multimodality treatment of recalcitrant necrobiotic xanthogranuloma using electron beam radiation and intravenous immunoglobulin. *Clin Exp Dermatol.* 2016;41:179–82. <https://doi.org/10.1111/ced.12719>.
74. Nelson CA, Zhong CS, Hashemi DA, Ashchyan HJ, Brown-Joel Z, Noe MH, Imadojemu S, Micheletti RG, Vleugels RA, Wanat KA, et al. A multicenter cross-sectional study and systematic review of necrobiotic xanthogranuloma with proposed diagnostic criteria. *JAMA Dermatol.* 2020;156:270–9. <https://doi.org/10.1001/jamadermatol.2019.4221>.
75. Nguyen BD. Hepatobiliary and pancreatic: hepatic necrobiotic xanthogranuloma. *J Gastroenterol Hepatol.* 2017;32:1667. <https://doi.org/10.1111/jgh.13858>.
76. Olson RM, Harrison AR, Maltry A, Mokhtazadeh A. Periorbital necrobiotic xanthogranuloma successfully treated with intravenous immunoglobulin. *Case Rep Ophthalmol.* 2018;9:70–5. <https://doi.org/10.1159/000485913>.
77. Pedrosa AF, Ferreira O, Calistru A, Mota A, Baudrier T, Sarmiento JA, Bettencourt H, Azevedo F. Necrobiotic xanthogranuloma with giant cell hepatitis, successfully treated with intravenous immunoglobulins. *Dermatol Ther.* 2015;28:68–70. <https://doi.org/10.1111/dth.12211>.
78. Rodriguez O, Meyers C, Weiss BM, Elenitsas R, Rosenbach M. Necrobiotic xanthogranuloma treated with topical nitrogen mustard (Meclorethamine). *JAMA Dermatol.* 2016;152:589–90. <https://doi.org/10.1001/jamadermatol.2015.5151>.
79. Sagiv O, Thakar SD, Morrell G, Tetzlaff MT, Esmaeli B. Rituximab monotherapy is effective in treating orbital necrobiotic xanthogranuloma. *Ophthalmic Plast Reconstr Surg.* 2018;34:e24–7. <https://doi.org/10.1097/IOP.0000000000000988>.
80. Sfeir JG, Zogala RJ, Popii VB. Hypercalcemia in necrobiotic xanthogranuloma: first reported case and insight into treatment. *J Bone Miner Res.* 2017;32:784–7. <https://doi.org/10.1002/jbmr.3047>.
81. Truong K, Venning V, Wain T, Chou S, Fernandez-Penas P. Successful treatment of highly refractory necrobiotic xanthogranuloma with peginterferon alfa-2a. *Clin Exp Dermatol.* 2020. <https://doi.org/10.1111/ced.14523>.
82. Vu K, Gupta R, Frater J, Atkinson J, Ranganathan P. A 55-year-old man with periorbital and inguinal masses, pericarditis, and pleuritis. *Arthritis Care Res (Hoboken).* 2017;69:730–6. <https://doi.org/10.1002/acr.22843>.
83. Wei YH, Cheng JJ, Wu YH, Liu CY, Hung CJ, Hsu JD, Hsiao YP. Necrobiotic xanthogranuloma: response to dapsone. *Dermatol Ther.* 2015;28:7–9. <https://doi.org/10.1111/dth.12179>.
84. Wruhs M, Feldmann R, Sawetz I, Breier F, Steiner A. Necrobiotic xanthogranuloma in a patient with multiple myeloma. *Case Rep Dermatol.* 2016;8:350–3. <https://doi.org/10.1159/000452826>.

Publisher's Note

Springer Nature remains neutral with regard to jurisdictional claims in published maps and institutional affiliations.

Ready to submit your research? Choose BMC and benefit from:

- fast, convenient online submission
- thorough peer review by experienced researchers in your field
- rapid publication on acceptance
- support for research data, including large and complex data types
- gold Open Access which fosters wider collaboration and increased citations
- maximum visibility for your research: over 100M website views per year

At BMC, research is always in progress.

Learn more biomedcentral.com/submissions

