




The Predictive Value of Early Postoperative MRI-Based Bone Marrow Parameters for Mid-Term Outcome after MACI with Autologous Bone Grafting at the Knee

CARTILAGE
 July-September 2022: 1–12
 © The Author(s) 2022
 DOI: 10.1177/19476035221093061
journals.sagepub.com/home/CAR


Matthias Jung¹ , Stefan Ruschke², Dimitrios C. Karampinos², Christian Holwein³ , Thomas Baum⁴, Alexandra S. Gersing^{2,5}, Fabian Bamberg¹, and Pia M. Jungmann¹ 

Abstract

Objective. The aim of this study was to longitudinally determine the prognostic value of early postoperative quantitative 3T-MRI (magnetic resonance imaging) parameters of subchondral bone marrow for 2-year clinical and MRI outcome after matrix-associated autologous chondrocyte implantation (MACI) with autologous bone grafting (ABG) at the knee. **Design.** Consecutive subjects who received MACI with ABG for treatment of focal osteochondral defects received MRI follow-up 3, 6, 12, and 24 months postoperatively. Quantitative MRI included bone marrow edema-like lesion (BMEL) volume measurements and single-voxel magnetic resonance spectroscopy (MRS; $n = 9$) of the subchondral bone marrow. At 2-year follow-up, morphological MRI outcome included MOCART (magnetic resonance observation of cartilage repair tissue) 2.0 scores. Clinical outcomes were assessed using Lysholm scores. **Results.** Among a total of 18 subjects (mean age: 28.7 ± 8.4 years, $n = 14$ males) with defects at the medial or lateral ($n = 15$ and $n = 3$, respectively) condyle, mean BMEL volume decreased from 4.9 cm^3 at 3 months to 2.0 cm^3 at 2-year follow-up ($P = 0.040$). MRS-based bone marrow water T2 showed a decrease from 20.7 ms at 1-year follow-up to 16.8 ms at 2-year follow-up ($P = 0.040$). Higher BMEL volume at 6 months correlated with lower 2-year Lysholm ($R = -0.616$, $P = 0.015$) and MOCART 2.0 scores ($R = -0.567$, $P = 0.027$). Larger early postoperative BMEL volumes at 3 months ($R = -0.850$, $P = 0.007$) and 6 months ($R = -0.811$, $P = 0.008$) correlated with lower MRS-based unsaturated lipid fractions at 2-year follow-up. Furthermore, patients with early postoperative bony defects showed worse MOCART 2.0 ($P = 0.044$) and Lysholm scores ($P = 0.017$) after 24 months. **Conclusion.** Low subchondral BMEL volume and optimal restoration of the subchondral bone at early postoperative time points predict better 2-year clinical and MRI outcomes after MACI with ABG.

Keywords

magnetic resonance imaging, MR spectroscopy, bone marrow, cartilage, arthroscopic surgery, athletic injuries

Introduction

Several surgical cartilage repair techniques have been developed for the treatment of patients with symptomatic osteochondral defects to prevent the onset of early osteoarthritis (OA).¹ Significant involvement of the subchondral bone requires restoration of the bony defect. Therefore, a combination of matrix-associated autologous chondrocyte implantation (MACI) and additional autologous bone grafting (ABG) was introduced, resulting in good clinical and radiological outcomes.^{2–6} Quantitative magnetic resonance imaging (MRI) techniques such as T2 relaxation time measurements have been shown to provide relevant information about water and collagen content in native hyaline cartilage.^{7,8} T2 relaxation time measurements are also used for

¹Department of Diagnostic and Interventional Radiology, Medical Center—University of Freiburg, Faculty of Medicine, University of Freiburg, Freiburg, Germany

²Department of Diagnostic and Interventional Radiology, School of Medicine, Technical University of Munich, Munich, Germany

³Department of Orthopaedic Sports Medicine, Klinikum Rechts der Isar, Technical University of Munich, Munich, Germany

⁴Department of Neuroradiology, Klinikum Rechts der Isar, School of Medicine, Technical University of Munich, Munich, Germany

⁵Department of Neuroradiology, University Hospital, LMU Munich, Munich, Germany

Corresponding Author:

Matthias Jung, Department of Diagnostic and Interventional Radiology, Medical Center—University of Freiburg, Faculty of Medicine, University of Freiburg, Hugstetter Strasse 55, 79106 Freiburg, Germany.
 Email: matthias.jung@uniklinik-freiburg.de



Creative Commons Non Commercial CC BY-NC: This article is distributed under the terms of the Creative Commons Attribution-NonCommercial 4.0 License (<https://creativecommons.org/licenses/by-nc/4.0/>) which permits non-commercial use, reproduction and distribution of the work without further permission provided the original work is attributed as specified on the SAGE and Open Access pages (<https://us.sagepub.com/en-us/nam/open-access-at-sage>).

the assessment of cartilage repair tissue. As cartilage and the subchondral bone are thought to interact as a functional unit, postoperative integrity of the subchondral bone may be crucial for optimal cartilage repair tissue maturation.^{9,10}

After cartilage repair surgery, bone marrow (BM) edema-like lesions (BMELs) are regularly observed, but their clinical relevance and pathogenesis still remain uncertain. Magnetic resonance spectroscopy (MRS) is a noninvasive method that may provide additional information about the biochemical water-fat composition of BM *in vivo*.^{6,11-13} Global T2 relaxation times have also been obtained from subchondral BM using imaging-based methods.^{14,15} However, the value of global T2 is unclear due to a mixture of signals from fat, water, granulation tissue, necrosis, and vessels contributing to the total MR signal.¹⁶ Single-voxel MRS not only enables the extraction of the fat fraction and unsaturated lipid fraction of BM (BMunsat) but also provides T2 values (MRS T2) for only the pure water signal.

Previously, we reported that early postoperative subchondral trabecular bone parameters correlated with T2 relaxation times of the cartilage repair tissue and with the qualitative WORMS score (Whole-Organ Magnetic Resonance Imaging Score) but not with the semi-quantitative MOCART (magnetic resonance observation of cartilage repair tissue) score in a series of patients who received MACI with ABG.⁵ However, an updated version of the MOCART score has recently been introduced to take into account changes of the subchondral bone.¹⁷ Moreover, analyses of the subchondral BMEL volume over time and MRS assessment of the subchondral BM were not included in that study. Therefore, the purpose of this secondary analysis of the case series was to evaluate the longitudinal changes of BMEL volume and MRS parameters of the subchondral bone and their associations with MR morphological and clinical outcomes after MACI with ABG of the knee.

Materials and Methods

Subjects

The study was approved by the local Institutional Review Board (Ethics Commission of the School of Medicine, Technical University of Munich). All procedures performed in studies involving human participants were in accordance with the ethical standards of the institutional and/or national research committee and with the 1964 Helsinki Declaration and its later amendments or comparable ethical standards. Informed consent was obtained from all individual participants included in the study. Inclusion and exclusion criteria were described previously.⁵ In a total of 18 patients included in this study, MRI and standardized clinical assessment were performed preoperatively and after 3, 6, 12, and 24 months postoperatively.

Surgery

All subjects included in this study received MACI with ABG either at the medial ($n = 15$) femoral condyle or at the lateral femoral condyle ($n = 3$). The 2-step surgical procedure and postoperative regimen were described in detail in our previous publication.⁵

MRI

MRI of the knee was performed at a 3.0 T MR scanner (Ingenia, Philips Healthcare, Best, The Netherlands) using a dedicated 16-channel knee coil (Medical Advances, Milwaukee, WI, USA). MR parameters are shown in **Table 1**. At the postoperative time points, 2-dimensional (2D) multi-slice multi-echo spin echo (MESE) T2-weighted (w) sequences were acquired in a sagittal plane for T2-mapping to perform a quantitative analysis of cartilage composition.¹⁸ Six echoes at TE = 10, 20, 30, 40, 50, and 60 ms were acquired. The first echo at TE = 10 ms was excluded to minimize effects from stimulated echo signal on calculated T2 values.¹⁹⁻²¹ In a subset of our cohort ($n = 9$), multi-TE single-voxel Stimulated Echo Acquisition Mode (STEAM) MRS was performed with TR = 2,500 ms, TM = 16 ms, TE = 11/15/20/25 ms, voxel size = $10 \times 10 \times 10 \text{ mm}^3$, number of samples = 4,096, scan time 1:20 min, 4 phase cycles in 8 averages, and spectral bandwidth = 5000 Hz at 12 and 24 months postoperatively. Spectroscopy signal quantification was performed using a time-domain-based approach²² with a joint-series T2-constrained fitting²³ of a 10-fat-peaks model implemented with MATLAB's Levenberg-Marquardt algorithm.

Morphological MR Assessment

MR images were evaluated semi-quantitatively by 2 radiologists (M.J. and P.M.J.). Semi-quantitative Area Measurement And DEpth Underlying Structures (AMADEUS) score was used for preoperative morphological assessment as previously described.^{24,25} Total AMADEUS score ranges from 0 (*severe defect*) to 100 (*no osteochondral defect*). Additional International Cartilage Repair Society (ICRS) grading was performed.²⁶

The MOCART 2.0 score was used for postoperative morphological description of the cartilage repair area that includes the parameters "Volume fill of cartilage defect" (0-20 points), "Integration into adjacent cartilage" (0-15 points), "Surface of the repair tissue" (0-10 points), "Structure of the repair tissue" (0-10 points), "Signal intensity of the repair tissue" (0-10 points), "Bony defect or bony overgrowth" (0-10 points), and "Subchondral changes" (0-20 points).¹⁷ A score of 100/100 represents optimal findings. The radiologists were blinded for clinical information

Table 1. MR Pulse Sequence Parameters.

Sequence	IM-w TSE	IM-w TSE	IM-w TSE	T1-w TSE	MESE T2
Additional features	2D	2D	2D	2D	2D
Plane	Cor	Sag	Tra	Sag	Sag
TE (ms)	44	44	40	13	10, 20, 30, 40, 50, 60
TR (ms)	3,363	4,202	5,456	785	2,200
Field of view (mm)	140	140	150	140	140
Slice thickness (mm)	3	3	3	3	2.5
In-plane resolution (mm ²)	0.4 × 0.4	0.4 × 0.4	0.4 × 0.4	0.4 × 0.4	0.4 × 0.4
Flip angle (°)	90	90	90	90	90
Number of slices	24	30	36	28	30 (per echo)
Slice distance (mm)	3.6	3.6	3.3	3.6	2.5
Echo train length	9	9	11	3	5
Bandwidth per pixel (Hz)	187	187	201	143	251
Phase encoding direction	Col	Col	Row	Col	Col
Number of averages	2	2	2	1	1
Acquisition time (min)	04:50	04:50	5:42	03:06	05:33
Fat saturation	Yes	Yes	Yes	No	No

MR = magnetic resonance; IM = intermediate; w = weighted; TSE = turbo spin echo; MESE = multi-echo spin echo; 2D = 2-dimensional; Cor = coronal; Sag = sagittal; Tra = transverse; Col = column.

and results of quantitative MRI. The evaluation of bony defects was based on the subscore “Bony defect or bony overgrowth” from the MOCART 2.0 score. This subscore was dichotomized into the presence of a bony defect (subscore ≤ 5 points) or the absence of a bony defect (subscore = 10 points).

Quantitative MR Assessment

Using a mono-exponential non-negative least squares fit analysis, T2 relaxation time maps were calculated pixel-wise from 2D T2 MESE images. The segmentation of artifact free cartilage was performed by one trained radiology resident (M.J.) and supervised by one experienced radiologist (P.M.J.). Areas with chemical shift artifacts were avoided. Two individual areas were segmented: (1) MACI cartilage repair tissue site (CRT2) and (2) cartilage of the posterior condyle (reference cartilage T2). “Relative CRT2” was calculated as “CRT2” divided by “reference cartilage T2” (Relative CRT2 = CRT2/reference cartilage T2). Subchondral BMELs were segmented on consecutive slices on sagittal IM-w TSE sequences by one trained radiology resident (M.J.) and supervised by one experienced radiologist (P.M.J.), and BMEL volume was calculated. Single-voxel MRS was acquired at the subchondral BM, at the central femoral condyle, and at identical sites of the contralateral condyle. BMunsat measured as the olefinic signal (at 5.28 ppm) divided by the methyl signal (at 0.90 ppm), and spectroscopic water T2 relaxation times (MRS T2) were calculated from the single-voxel MRS data. The radiologists were blinded for clinical information and results of morphological MRI.

Clinical Evaluation

Postoperative clinical outcome was captured at each time point (3, 6, 12, and 24 months after surgery) using the modified Lysholm knee score, resulting in a 100-point scale (the clinical results were considered excellent if the Lysholm knee score was >90 points; good, 84-90 points; sufficient, 65-83 points; and poor, <65 points) and the Tegner activity level using a 10-point scale (0 = sick leave or disability because of severe knee pain; 10 = competitive sports, e.g., soccer, no knee problems).^{27,28}

Statistical Analysis

Statistical processing was performed with SPSS, version 27.0 (IBM, Armonk, NY, USA) by two authors (M.J. and P.M.J.). All tests were performed based on a 2-sided 0.05 level of significance. Normal distribution of the data was assessed using Kolmogorov-Smirnov and Shapiro-Wilk tests. Paired *t* tests were used to assess the longitudinal changes of parametric parameters. Unpaired *t* tests were used for the comparison of parametric parameters between independent groups. Wilcoxon signed-rank tests were used to assess the longitudinal changes of nonparametric parameters. Mann-Whitney *U* test was performed for the comparison of nonparametric parameters between independent groups. Medians, means, and standard deviations (SDs); mean differences between groups; and lower and upper 95% confidence intervals (CIs) with standard error of the mean (SEM) were calculated. Spearman’s rank correlation coefficients were obtained to assess the correlations of quantitative parameters with semi-quantitative clinical

parameters and semi-quantitative imaging parameters, respectively. To determine the accuracy of BMEL volumes in predicting an excellent Lysholm score after 24 months, receiver operating characteristic (ROC) analyses were conducted and the area under the curve (AUC) was determined. Optimal cutoff values were determined using the Youden Index. Corresponding sensitivities and specificities were calculated. A multivariate linear regression model was used to assess possible predictive quantitative and semi-quantitative imaging parameters for the clinical outcome after 24 months.

Reproducibility Measurements

Good intra- and inter-reader reproducibility was reported previously for our research group.^{5,6}

Results

Patient Characteristics

The analyzed subjects ($n = 18$; $n = 14$ males, $n = 4$ females) had a mean age of 28.7 ± 8.4 years (mean \pm SD). The mean body mass index (BMI) was 25.0 ± 4.5 kg/m². In 12/18 cases, surgery had been performed at the right knee (left knee, 6/18 cases). MACI with ABG was performed for osteochondral defects at the medial femoral condyle in 15/18 subjects (lateral femoral condyle, 3/18 cases). The mean defect area was 5.3 ± 2.5 cm². Additional high tibial osteotomy (HTO) was performed in 7/18 cases for correction of varus deformity $>2^\circ$. Lysholm score significantly improved from 75.3 ± 12.9 (mean \pm SD) after 3 months to 87.9 ± 5.6 after 6 months, to 92.4 ± 5.2 after 12 months, and to 94.2 ± 4.4 at 24 months ($P < 0.05$ from 3 months to all time points). There was a statistically significant step-wise improvement of Tegner scores from 3 to 6 months ($Z = -2.43$, $P = 0.015$), from 6 to 12 months ($Z = -2.33$, $P = 0.020$), and from 12 to 24 months ($Z = -2.59$, $P = 0.038$).

Pre- and Postoperative Morphological MR Assessment

Preoperative MR images were available in 17/18 cases. Preoperative ICRS score was grade 4 in all subjects. Total AMADEUS scores ranged from 0 to 50 with a mean score of 22.9 ± 17.7 . AMADEUS grades I, II, III, and IV were present in 0, 0, 5, and 12 cases, respectively. Total AMADEUS scores, AMADEUS grades, or AMADEUS subscores did not correlate with any radiologic or clinical outcome parameters ($P > 0.05$).

Postoperatively, the mean MOCART 2.0 score was 68.8 ± 13.5 at 3 months follow-up. There was a statistically significant increase (improvement) of MOCART 2.0 score between 3 and 6 months (80.6 ± 11.2 , $P = 0.003$). The

further increase of MOCART 2.0 scores between 6 and 12 months (84.1 ± 12.4 , $P = 0.178$) and between 12 and 24 months (85.6 ± 11.5 , $P = 0.401$) was not statistically significant.

We reported previously that the overall radiological outcome 24 months after MACI with ABG was good to excellent.⁵ While underfilling was found in $n = 6$ patients after 3 months, and $n = 3$ patients after 6 months, only 1 patient showed persisting underfilling after 12 and 24 months. The presence of underfilling at any postoperative follow-up time point did not show a statistically significant correlation with Lysholm scores after 24 months ($P > 0.05$). In our cohort, all of the detected bony defects were already present at the first follow-up time point at 3 months after surgery. No new bony defect occurred at 6, 12, or 24 months follow-up. In 5/6 cases, the bony defect persisted 24 months after MACI with ABG. Only in 1 patient that showed a bony defect at 3 and 6 months, a normal subchondral bone was found at 24 months (patient C in **Fig. 1**).

After 24 months, MOCART 2.0 scores were significantly lower (worse) in patients with bony defects than in patients without bony defects at 3 months follow-up (77.5 ± 11.3 vs. 90.8 ± 8.6 , respectively; mean difference \pm SEM = 13.3 ± 5.8 ; 95% CI = 0.4-26.3; $P = 0.044$) and at 6 months follow-up (74.2 ± 7.4 vs. 92.2 ± 7.5 , respectively; mean difference \pm SEM = 18.1 ± 3.9 ; 95% CI = 9.5-26.6; $P < 0.001$). Furthermore, Lysholm scores after 24 months were significantly lower (worse) in patients with bony defects than in patients without bony defects at 3 months follow-up (92.2 ± 4.4 vs. 98.0 ± 2.3 , respectively; mean difference \pm SEM = 5.8 ± 2.0 ; 95% CI = 1.3-10.4; $P = 0.017$), and there was a statistical trend toward a lower Lysholm score at 24 months in the presence of bony defect at 6 months follow-up (92.2 ± 4.4 vs. 96.8 ± 3.8 , respectively; mean difference \pm SEM = 4.6 ± 2.1 ; 95% CI = 0.01-9.21; $P = 0.05$). The difference in the total MOCART 2.0 score between patients with an excellent Lysholm score (>90 points) and patients with a Lysholm score ≤ 90 points at 24 months was statistically significant at 12 months (89.0 ± 10.5 vs. 75.8 ± 11.6 , respectively; mean difference \pm SEM = 13.2 ± 5.6 ; 95% CI = 1.1-25.3; $P = 0.035$) and at 24 months follow-up (90.0 ± 8.2 vs. 78.3 ± 13.3 , respectively; mean difference \pm SEM = 11.7 ± 5.3 ; 95% CI = 0.3-23.1; $P = 0.046$) (**Fig. 2**).

T2 Cartilage

CRT2 values were significantly higher in the cartilage repair area than were the reference values at all follow-up time points (all P s $< .005$; **Table 2**). The mean relative CRT2 value at 3 months was 1.55 ± 0.27 . A slight increase of relative CRT2 at 6 months was not statistically significant (1.62 ± 0.25 , $P = 0.13$). Relative CRT2 decreased significantly between 6 and 12 months (1.39

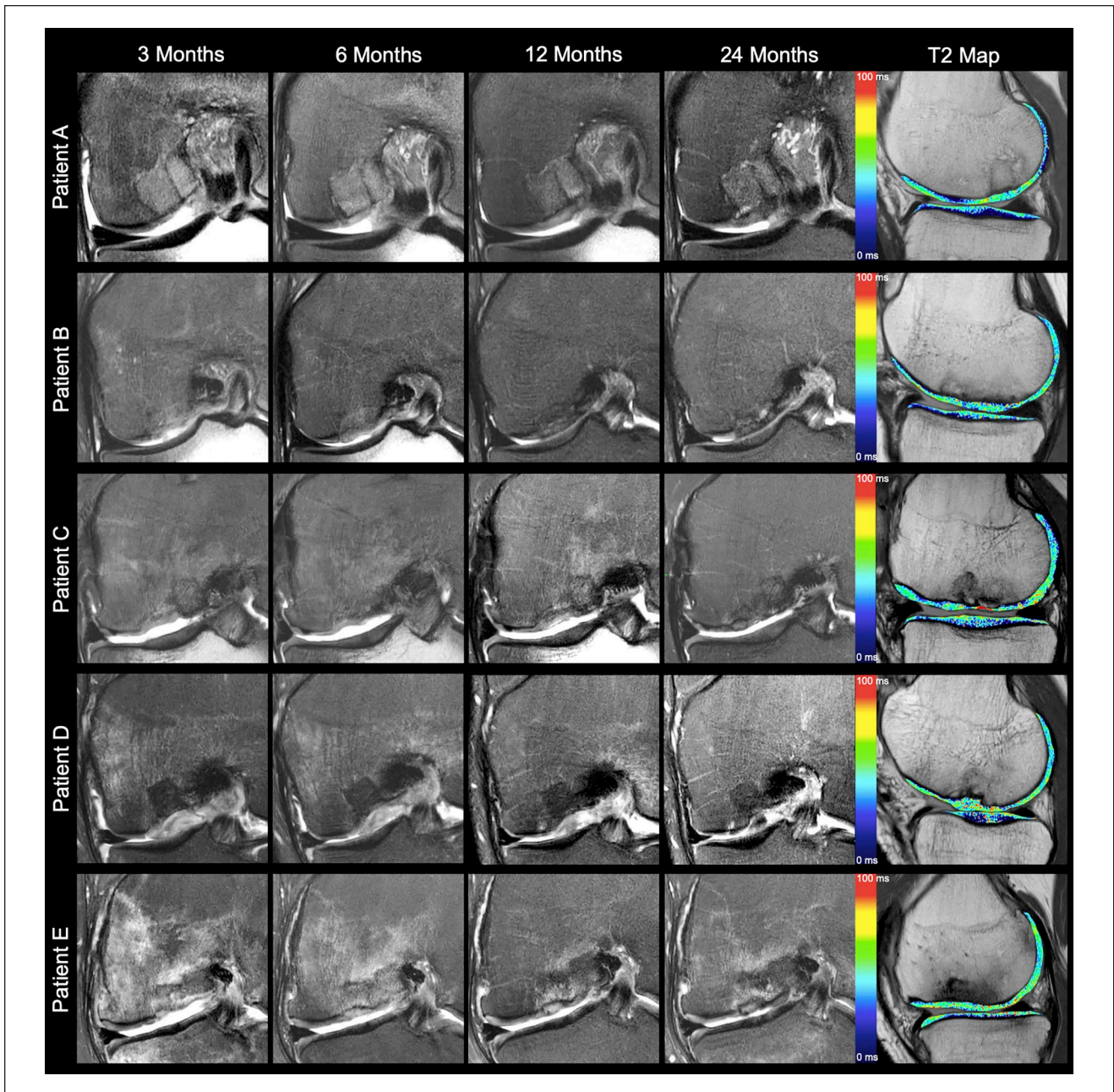


Figure 1. Coronal intermediate-weighted images with fat saturation over time and sagittal T2 relaxation time maps at 24 months after matrix-associated chondrocyte implantation and autologous bone grafting (patients A and B, Lysholm Score ≥ 95). Morphological images demonstrate optimal restoration of the subchondral bone without a bone marrow edema-like lesion (MOCART 2.0 score, ≥ 95). T2 values of the cartilage repair tissue are normalized at 24 months (patient C, Lysholm Score = 90). Morphological images depict a bony defect at 3 and 6 months follow-up. Only in this patient, a normalized subchondral bone was found at 24 months (MOCART 2.0 score, 95) after the presence of an early postoperative bony defect. T2 values remain prolonged (patients D and E, Lysholm score ≤ 90). Early postoperative bony defects persist at all follow-up time points (MOCART 2.0 score, 70). Large BMEL declines over time in patient D but persists at all follow-up time points in patient E. T2 values of the cartilage repair area remain prolonged in patient D. MOCART = magnetic resonance observation of cartilage repair tissue; BMEL = bone marrow edema-like lesion.

± 0.20 , $P = 0.008$). Moreover, a further decrease was found in relative CRT2 24 months after MACI with ABG

(1.23 ± 0.27 , $P = 0.021$). After 24 months, relative CRT2 was significantly higher in patients with bony

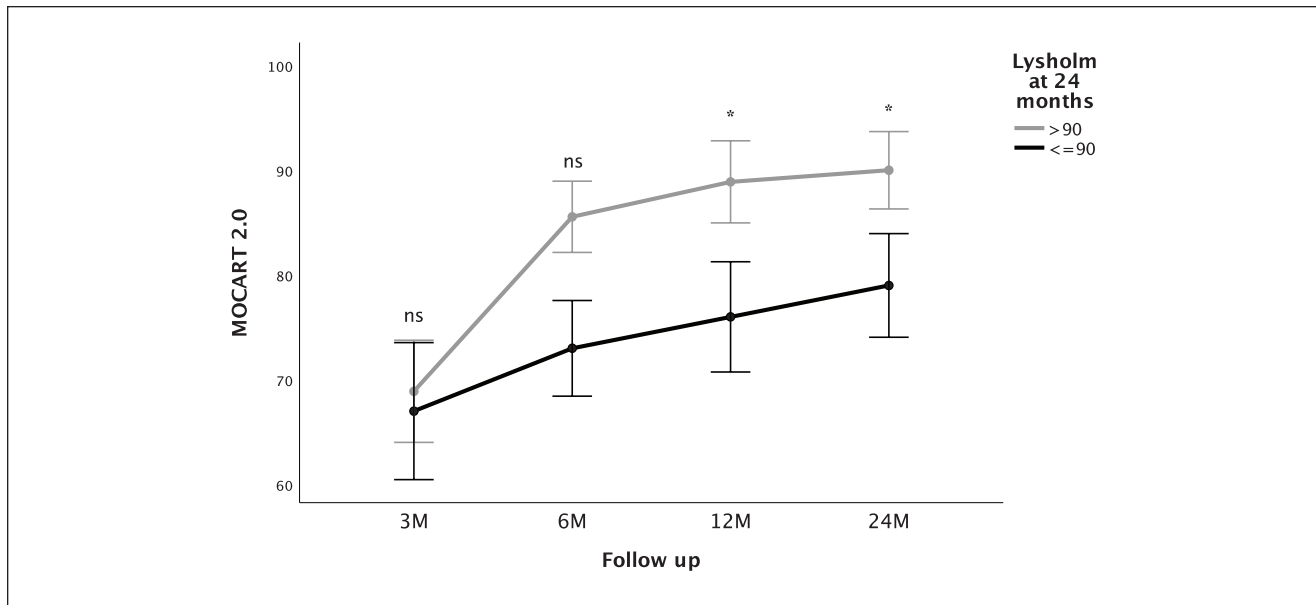


Figure 2. MOCART 2.0 scores (mean \pm SE) at different follow-up time points in patients with Lysholm scores >90 points and ≤ 90 at 24 months, respectively. Patients with excellent Lysholm scores after 24 months show higher MOCART 2.0 from 6 months on. MOCART = magnetic resonance observation of cartilage repair tissue; ns = not significant; M = months. Asterisks indicate statistically significant differences.

Table 2. CRT2 Values (Milliseconds) of the Cartilage Repair Area and the Reference Area at Different Postoperative Follow-Up Time Points.

Follow-Up	Cartilage Repair Area (Mean \pm SD)	Reference Area (Mean \pm SD)	P Value	Mean Difference \pm SEM (95% CI)
3 months	61.8 \pm 12.2	39.7 \pm 3.4	<0.001	22.0 \pm 2.8 (16.1-28.0)
6 months	64.6 \pm 10.8	39.7 \pm 4.3	<0.001	24.8 \pm 2.5 (19.5-30.1)
12 months	54.5 \pm 9.1	39.2 \pm 4.1	<0.001	15.3 \pm 2.0 (11.2-19.5)
24 months	51.4 \pm 11.7	41.8 \pm 4.6	0.003	9.6 \pm 2.7 (3.8-15.4)

Bold values indicate $P < 0.05$.

CRT2 = cartilage repair tissue site T2 value; SEM = standard error of the mean; CI = confidence interval.

defects than in patients without bony defects at 6 months follow-up (1.43 ± 0.29 vs. 1.13 ± 0.18 , respectively; mean difference \pm SEM = 0.30 ± 0.12 ; 95% CI = 0.04-0.56; $P = 0.029$), but not at 3 months follow-up ($P = 0.092$). There was a statistically significant difference of relative CRT2 between patients with total MOCART 2.0 scores ≥ 90 points (1.11 ± 0.18) and patients with total MOCART 2.0 scores < 90 points (1.39 ± 0.29 ; mean difference \pm SEM = -0.27 ± 0.12 ; 95% CI = -0.53 to 0.02 , $P = 0.038$) at 24 months. CRT2 values did not show a statistically significant correlation with Lysholm scores after 24 months ($P > 0.05$).

Longitudinal Assessment of BMELs

Correlations between BMEL volumes and clinical scores, and quantitative and qualitative MRI outcome parameters,

are shown in **Table 3**. The mean BMEL volume at 3 months after MACI with ABG was 4.8 ± 4.3 cm³ (median = 4.1 cm³). The stepwise decrease of the BMEL volume from 3 to 6 months (mean \pm SD = 3.9 ± 3.8 cm³, median = 2.9 cm³), from 6 to 12 months (mean \pm SD = 2.7 ± 3.3 cm³, median = 1.4 cm³), and from 12 to 24 months (mean \pm SD = 2.0 ± 2.4 cm³, median = 0.8 cm³) was not statistically significant (all P s > 0.05).

However, BMEL volume decreased significantly between 3 and 12 months ($Z = -2.1$, $P = 0.04$), and between 3 and 24 months ($Z = -2.1$, $P = 0.04$) after MACI with ABG. Higher quantitative CRT2 values 24 months after MACI with ABG were significantly correlated with higher BMEL volumes at 6 months ($R = 0.649$, $P = 0.009$), at 12 months ($R = 0.561$, $P = 0.024$), and at 24 months ($R = 0.563$, $P = 0.023$). Furthermore, there was a statistical significance for the correlation of lower (worse) MOCART 2.0

Table 3. The Association Between BMELs Volume at Different Time Points and Clinical/Radiological Outcome Parameters at 24 Months.

	BMEL at 3 Months		BMEL at 6 Months		BMEL at 12 Months		BMEL at 24 Months	
	R	P Value	R	P Value	R	P Value	R	P Value
CRT2 ^a	0.521	0.056	0.649	0.009	0.561	0.024	0.563	0.023
MOCART 2.0 ^a	-0.471	0.090	-0.550	0.034	-0.619	0.011	-0.545	0.029
Lysholm ^a	-0.539	0.047	-0.555	0.032	-0.324	0.221	-0.106	0.697
Tegner ^a	-0.135	0.645	-0.030	0.915	0.096	0.724	0.187	0.487

Bold values indicate $P < 0.05$.

BMELs = bone marrow edema-like lesions; CRT2 = cartilage repair tissue site T2 value; MOCART = magnetic resonance observation of cartilage repair tissue.

^aIndicates 24 months follow-up time points.

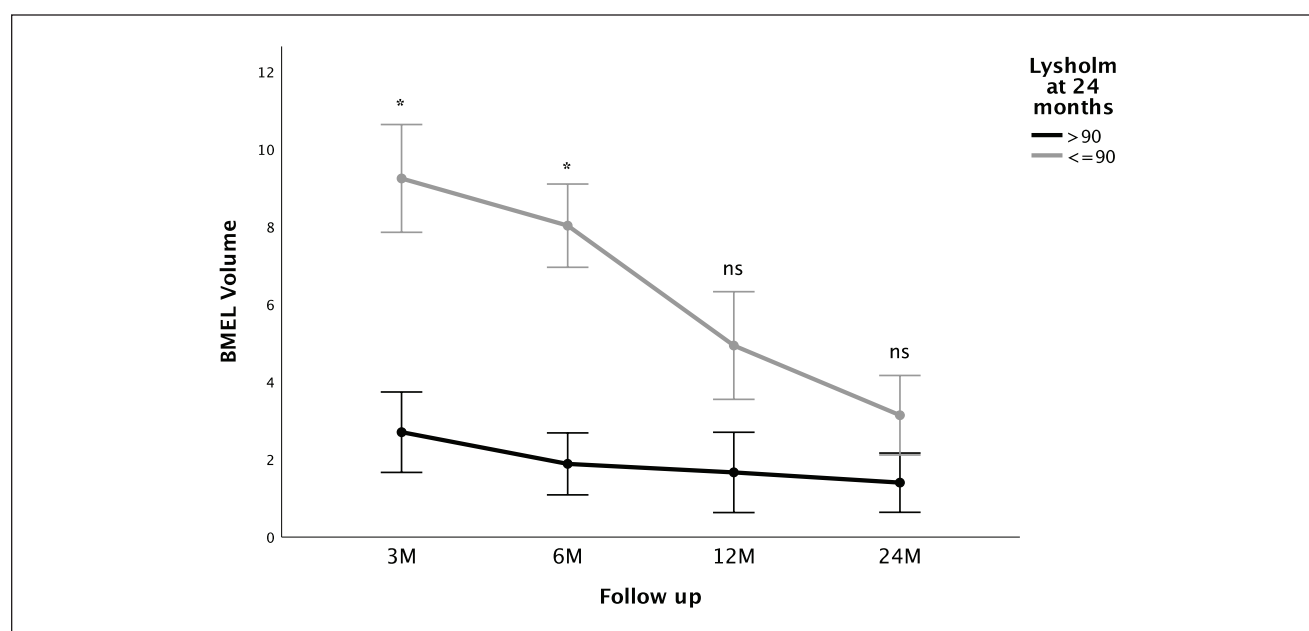


Figure 3. BMEL volumes (mean \pm SE) at different follow-up time points in patients with Lysholm scores >90 points and ≤ 90 at 24 months, respectively. Patients with excellent Lysholm scores after 24 months show significantly higher BMEL volume early postoperative at 3 and 6 months. BMEL = bone marrow edema-like lesion; ns = not significant; M = months. Asterisks indicate statistically significant differences.

scores at 24 months with higher BMEL volumes at 6 months ($R = -0.550$, $P = 0.034$), at 12 months ($R = -0.619$, $P = 0.011$), and at 24 months ($R = -0.545$, $P = 0.029$). Patients with persisting bony defects 24 months after surgery had significantly higher BMEL volumes at 3 months follow-up than patients without a bony defect (median = 8.6 cm^3 vs. 1.8 cm^3 , $Z = -2.2$, $P = 0.029$). Regarding clinical correlations, lower (worse) Lysholm scores at 24 months were significantly correlated with higher BMEL volumes at 3 months ($R = -0.539$, $P = 0.047$) and at 6 months ($R = -0.555$, $P = 0.032$), but not at 12 or 24 months ($P > 0.05$). Furthermore, those patients with excellent Lysholm scores (>90 points) 24 months after surgery showed significantly

lower BMEL volumes at 3 months follow-up ($Z = -2.5$, $P = 0.012$) and at 6 months follow-up ($Z = -2.4$, $P = 0.018$) (Fig. 3).

The accuracy in predicting an excellent Lysholm score (>90) after 24 months was excellent for BMEL volume at 3 months (AUC = 0.91, $P = 0.014$, 95% CI = 0.75-1.0) and good for BMEL volume at 6 months (AUC = 0.87, $P = 0.018$, 95% CI = 0.67-1.0). Considering sensitivity and specificity as equally important, optimal cutoff values for the prediction of an excellent Lysholm score at 24 months follow-up were found for a BMEL volume of $\leq 7.1 \text{ cm}^3$ at 3 months with a sensitivity of 89% and a specificity of 80%, and for a BMEL volume of $\leq 7.0 \text{ cm}^3$ at 6 months with a

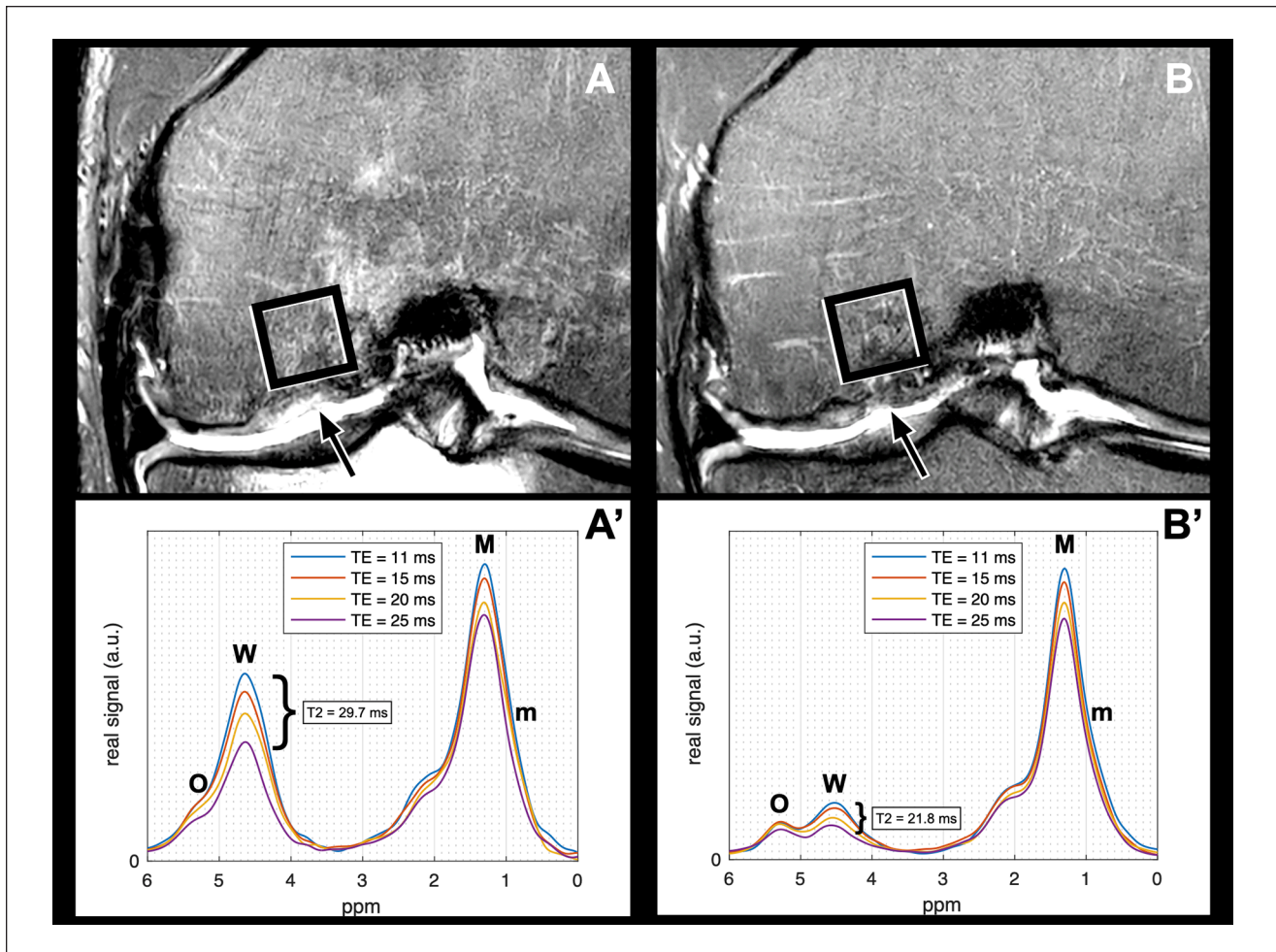


Figure 4. Visualization of the decrease of MRS T2 from 12 months (**A, A'**) to 24 months (**B, B'**) after MACI with ABG. (**A, B**) Coronal intermediate-weighted fat-saturated turbo spin echo (TE) sequences and (**A', B'**) MRS data of subchondral bone marrow. (**A**) BMEL in a patient with underfilling, a bony defect, and pain 12 months after MACI with ABG. (**B**) Decreased size of BMEL volume in the same patient at 24 months follow-up. Quantitative MRS analysis shows a decrease of MRS T2 after 24 months (**B'**) when compared with 12 months follow-up (**A'**). MRS = magnetic resonance spectroscopy; MACI = matrix-associated autologous chondrocyte implantation; ABG = autologous bone grafting; M = methylene signal (1.30 ppm); m = methyl signal (0.90 ppm); O = olefinic signal (5.28 ppm); W = water signal (4.67 ppm). Arrows mark the cartilage repair site. Square shows the position of the voxel ($10 \times 10 \times 10 \text{ mm}^3$) used for spectroscopic analysis.

sensitivity of 100% and a specificity of 67%. When implementing BMEL volume and the presence of a bony defect at 6 months follow-up in a multivariate linear regression model with the outcome parameter Lysholm score at 24 months, BMEL volume at 6 months was found to be an independent statistically significant predictor for clinical outcome ($B = -0.62$, $P = 0.035$) but not the presence of a bony defect ($B = -1.46$, $P = 0.166$). No significant associations were found between BMEL volumes and the Tegner activity scores ($P > 0.05$).

MRS of the Subchondral Bone

MRS of the subchondral bone was available in a subset of 9/18 patients at 12 and 24 months follow-up. There

was a statistically significant decrease found in MRS T2 from 12 to 24 months after MACI with ABG ($20.7 \pm 5.9 \text{ ms}$ vs. $16.8 \pm 5.6 \text{ ms}$, respectively; mean difference \pm SEM = $3.9 \pm 1.5 \text{ ms}$; 95% CI = $0.2\text{-}7.6 \text{ ms}$; $P = 0.040$; **Fig. 4**). There was a statistical significance for the correlation of lower BMunsat 24 months after surgery with higher BMEL volumes at 3 months ($R = -0.850$, $P = 0.007$), at 6 months ($R = -0.811$, $P = 0.008$), and at 12 months follow-up ($R = -0.727$, $P = 0.027$). Those patients with excellent Lysholm scores (>90 points) at 24 months follow-up showed a trend for higher BMunsat than patients with Lysholm scores ≤ 90 points ($43.4\% \pm 8.0\%$ vs. $27.3\% \pm 13.6\%$, respectively; mean difference \pm SEM = $16.1\% \pm 7.2\%$; 95% CI = $-1.0\%\text{-}33.3\%$; $P = 0.061$).

Discussion

In this study, advanced quantitative MRI techniques were applied 3, 6, 12, and 24 months postoperatively in a series of patients after MACI with ABG of the knee. MRI analyses focused on single-voxel MRS and BMEL volume measurements of the subchondral BM, morphologic MRI findings, and CRT2 measurements of the cartilage repair tissue. Higher early postoperative BMEL volumes at 3 and/or 6 months were associated with different imaging and clinical outcome parameters at 24 months: higher CRT2 values, lower BMunsat, and worse MR morphological (MOCART 2.0) and worse clinical (Lysholm) outcomes. The presence of early postoperative bony defects was significantly, or by trend, associated with the following parameters at 24 months: higher relative CRT2 values, lower BMunsat, worse MR morphological, and worse clinical outcomes. These early postoperative bony defects showed a limited potential for full restoration of the subchondral bone integrity over time. Therefore, this study indicates that early postoperative qualitative and quantitative MRI parameters including bony defects and BMEL volume measurements are associated with cartilage repair tissue quality, radiological, and clinical outcome 24 months after MACI with ABG.

T2 relaxometry mapping is a quantitative MRI technique that provides biochemical information about water and collagen content of hyaline cartilage. Previous studies have shown correlations of T2 relaxation time measurements with cartilage matrix degeneration, cartilage loss, and OA.^{19,29} Recently, quantitative MRI techniques have been increasingly used for noninvasive biochemical assessment of cartilage repair tissue, but their validity in the evaluation of the fibrous and hyaline-like cartilage containing repair tissue remains unclear.^{1,8,30-32} Studies have demonstrated that early postoperative after MACI, CRT2 values are initially higher than T2 values of native hyaline cartilage and subsequently decrease during follow-up.^{33,34} In line, relative CRT2 values stepwise decreased over 24 months in our cohort, indicating cartilage repair tissue maturation. In our previous study, we reported no significant association between the MOCART score and CRT2 values at 2-year follow-up.⁵ However, in the present study, the updated version of the MOCART score was used for MR morphological assessment of the cartilage repair area. In contrast to the original version, integrity of the subchondral bone is weighted more heavily in the updated 100-point scoring system.^{17,35} In the present study, higher CRT2 values were associated with worse MOCART 2.0 scores, suggesting that the updated MOCART 2.0 score better reflects cartilage repair tissue quality, possibly due to the emphasis on the subchondral bone and its role in cartilage repair tissue nutrition and maturation.

In a previous cross-sectional study, we showed that bony defects were associated with higher T2 relaxation times of the cartilage repair tissue at 2.5 years after surgery.⁶ Interestingly, in this longitudinal study, already the presence of postoperative bony defects early after MACI with ABG (3 and/or 6 months) predicted higher 24 months CRT2 values and worse 24 months clinical and MR morphological outcomes. In addition, these early postoperative subchondral bony defects persisted in 5/6 cases throughout the 2-year follow-up. These results indicate that early postoperative subchondral bony defects (1) may have a limited self-restoration potential after osteochondral surgery, (2) may lead to insufficient nutrition and maturation of the cartilage repair tissue, and (3) may be associated with worse MR morphological and clinical outcome. In contrast to cartilage repair tissue underfilling that (in our cohort) showed the potential to improve predominantly throughout the first postoperative year due to cartilage repair tissue growth, no postoperative growth/filling of the subchondral bone seems to occur. This indicates that full restoration of the subchondral bony defect should be addressed intraoperatively to achieve optimal postoperative proliferation and maturation of the overlying cartilage repair tissue matrix. Yet, overall clinical and MR morphological outcome was good to excellent at the 2-year follow-up, and in line with previous studies, there was a significant improvement of clinical and radiologic scores over time.^{36,37}

However, a high overall prevalence of subchondral BMEL was found during follow-up and persisting BMEL was present in 56.3% of our cohort 24 months after surgery. Several studies have described large numbers of patients with BMEL after cartilage repair surgery, with a prevalence of up to 47% at 12 months follow-up, and 61.5% and 73.1% at mid-term (22-36 months) and long-term (96-194 months) follow-up, respectively.³⁸⁻⁴³ While previous studies reported associations of BMEL with knee pain,^{5,6,44,45} some postoperative follow-up studies after cartilage repair surgery found no correlation of BMEL with poor clinical outcomes.^{40,41,46,47} In this prospective study, larger early postoperative BMEL was associated with worse clinical outcome after 24 months, and BMEL volume measurements showed good to excellent accuracy in predicting the clinical outcome at 2-year follow-up after MACI with ABG (optimal cutoff at 6 months: $\leq 7.0 \text{ cm}^3$). These different observations may partly be explained by the additional osseous transplantation in our cohort. For instance, Niemeyer *et al.*⁴⁰ specifically excluded patients with deep preoperative subchondral bony defects. It is speculated that an insufficient protection of the subchondral bone from mechanical loads may lead to the presence of BMEL after cartilage repair surgery.^{46,48} In our cohort, patients with persisting bony defects showed larger BMEL volumes early postoperatively and worse cartilage repair tissue quality after 24 months. However, it still remains uncertain, whether changes of the subchondral

bone lead to insufficient cartilage repair tissue proliferation, or whether BMEL is the result of biomechanical stress caused by insufficient cartilage repair tissue and subchondral bone quality.

Despite signal alterations of subchondral BMEL on morphologic MRI indicate edema, histologic studies have found little true edema but non-characteristic abnormalities, including BM fibrosis, BM necrosis, and trabecular abnormalities.^{49,50} MRS is a noninvasive method to quantitatively assess the biochemical water-fat composition of BM *in vivo*.¹⁶ In particular, MRS allows the quantification of unsaturation levels among triglycerides. So far, only a few studies have used MRS for quantitative analyses of the BM at the knee joint.^{6,11-13,51} In a previous study, we reported that MRS may be used as a sensitive method to detect edema or water in BMEL.⁶ In line with these findings, we here report a significant decrease in MRS-based T2 relaxation times of water from 12 to 24 months in subset of 9/18 after MACI with ABG, consistent with the decrease of BMEL volume over time. Furthermore, those patients with larger early postoperative BMEL showed lower BMunsat at 2-year follow-up. Similar biochemical changes of the fat component of the subchondral bone have previously been described in patients with OA of the knee.^{6,11,51} In addition, those patients with worse Lysholm scores had lower BMunsat. Kim *et al.*⁵² showed that even after cartilage repair, the risk for a progression of radiographic OA increases from 5 years after surgery on. Thus, MRS detecting low BMunsat may be an additional biomarker for degenerative changes of the subchondral bone at an early time point. However, larger long-term longitudinal cohort studies are needed to support this hypothesis.

In our previous study, we showed a correlation of early postoperative subchondral trabecular bone parameters with T2 relaxation times of the cartilage repair tissue.⁵ In the present study, we specifically focused on the evaluation of quantitative subchondral BMEL volume and MRS assessment of the subchondral BM over time. This study is a secondary analysis of our prospective cohort.⁵ Thus, statistical power calculations do not apply for the current analysis because they were based on the original study design. In part, absent significant findings may therefore be explained due to the relatively small number of patients ($n = 18$). However, it must be noted that MACI with ABG was only introduced during recent years, and the sample size is similar to that in previously conducted studies.^{2,3} Still, further prospective studies with larger cohorts are needed to evaluate the exact role of subchondral bone parameters longitudinally. Another limitation of this study is that advanced MRI was only performed postoperatively, and preoperative MRI scans were evaluated only morphologically. Yet, in line with a previous study, postoperative outcomes were not correlated with preoperative semi-quantitative AMADEUS (sub-) scores.⁶ These results further support the hypothesis that

very good postoperative results may be achieved regardless of the preoperative defect size. A further limitation of the study is that quantitative MRS was only available in a subset of our cohort, which consecutively limits statistical power. However, it must be emphasized that even in this small sample size, significant biochemical changes of the fat component that have previously been described in patients with OA were found in patients with larger early postoperative BMEL. MRS parameters may therefore provide additional information regarding early degenerative changes that may become apparent at a later time point on morphological MRIs. Further prospective studies are needed to evaluate the exact value of MRS in predicting OA.

In summary, T2 relaxation time, BMEL volume, and single-voxel MRS of the BM provided quantitative measurements of cartilage repair tissue and adjacent subchondral bone after MACI with ABG. This study found 2 main MRI findings that may be assessed at 6 months after surgery and that are predictive for worse 2-year clinical and MRI outcome after osteochondral repair: (1) early postoperative bony defects that show a limited self-restoration potential and (2) large early postoperative BMEL volumes (cutoff at 6 months: $\leq 7.0 \text{ cm}^3$). In this context, quantitative MRS including MRS T2 and BMunsat may serve as a non-invasive method to detect early degenerative BM changes after MACI with ABG. In conclusion, the complete intraoperative restoration and the early postoperative integrity of the subchondral bone (no bony defect, small BMEL volume) may be essential for the proper nutrition and maturation of the overlying cartilage repair tissue, resulting in optimal cartilage repair tissue quality and clinical outcome 24 months after osteochondral repair.

Authors' Note

The study was performed at the Department of Diagnostic and Interventional Radiology, School of Medicine, Technical University of Munich, Germany.

Acknowledgments and Funding

The author(s) disclosed receipt of the following financial support for the research, authorship, and/or publication of this article: M.J. was funded by the Berta-Ottenstein-Programme for Clinician Scientists, Faculty of Medicine, University of Freiburg. P.M.J. was funded by the Berta-Ottenstein-Programme for Advanced Clinician Scientists, Faculty of Medicine, University of Freiburg.




Declaration of Conflicting Interests

The author(s) declared no potential conflicts of interest with respect to the research, authorship, and/or publication of this article.

Ethical Approval

The ethical approval was obtained from the Ethics Commission of the Faculty of Medicine, Technical University of Munich, Germany.

ORCID iDs

Matthias Jung  <https://orcid.org/0000-0002-1124-4284>
 Christian Holwein  <https://orcid.org/0000-0002-1655-1435>
 Pia M. Jungmann  <https://orcid.org/0000-0003-2198-3678>

References

- Jungmann PM, Gersing AS, Baumann F, Holwein C, Braun S, Neumann J, et al. Cartilage repair surgery prevents progression of knee degeneration. *Knee Surg Sports Traumatol Arthrosc.* 2019;27(9):3001-13.
- Minas T, Ogura T, Headrick J, Bryant T. Autologous chondrocyte implantation “sandwich” technique compared with autologous bone grafting for deep osteochondral lesions in the knee. *Am J Sports Med.* 2018;46(2):322-32.
- Ogura T, Merkely G, Bryant T, Winalski CS, Minas T. Autologous chondrocyte implantation “segmental-sandwich” technique for deep osteochondral defects in the knee: clinical outcomes and correlation with magnetic resonance imaging findings. *Orthop J Sports Med.* 2019;7(5):2325967119847173.
- Ochs BG, Muller-Horvat C, Albrecht D, Schewe B, Weise K, Aicher WK, et al. Remodeling of articular cartilage and subchondral bone after bone grafting and matrix-associated autologous chondrocyte implantation for osteochondritis dissecans of the knee. *Am J Sports Med.* 2011;39(4):764-73.
- Gersing AS, Holwein C, Suchowierski J, Feuerriegel G, Gassert FT, Baum T, et al. Cartilage T2 relaxation times and subchondral trabecular bone parameters predict morphological outcome after matrix-associated autologous chondrocyte implantation with autologous bone grafting. *Am J Sports Med.* 2020;48(14):3573-85.
- Jung M, Karampinos DC, Holwein C, Suchowierski J, Diallo TD, Gersing AS, et al. Quantitative 3-T magnetic resonance imaging after matrix-associated autologous chondrocyte implantation with autologous bone grafting of the knee: the importance of subchondral bone parameters. *Am J Sports Med.* 2021;49(2):476-86.
- Liess C, Lusse S, Karger N, Heller M, Gluer CC. Detection of changes in cartilage water content using MRI T2-mapping in vivo. *Osteoarthritis Cartilage.* 2002;10(12):907-13.
- Jungmann PM, Baum T, Bauer JS, Karampinos DC, Erdle B, Link TM, et al. Cartilage repair surgery: outcome evaluation by using noninvasive cartilage biomarkers based on quantitative MRI techniques? *Biomed Res Int.* 2014;2014:840170.
- Goldring SR, Goldring MB. Changes in the osteochondral unit during osteoarthritis: structure, function and cartilage-bone crosstalk. *Nat Rev Rheumatol.* 2016;12(11):632-44.
- Imhof H, Sulzbacher I, Grampp S, Czerny C, Youssefzadeh S, Kainberger F. Subchondral bone and cartilage disease: a rediscovered functional unit. *Invest Radiol.* 2000;35(10):581-8.
- Li X, Ma BC, Bolbos RI, Stahl R, Lozano J, Zuo J, et al. Quantitative assessment of bone marrow edema-like lesion and overlying cartilage in knees with osteoarthritis and anterior cruciate ligament tear using MR imaging and spectroscopic imaging at 3 Tesla. *J Magn Reson Imaging.* 2008;28(2):453-61.
- Tufts LS, Shet K, Liang F, Majumdar S, Li X. Quantification of bone marrow water and lipid composition in anterior cruciate ligament-injured and osteoarthritic knees using three-dimensional magnetic resonance spectroscopic imaging. *Magn Reson Imaging.* 2016;34(5):632-7.
- Wang L, Salibi N, Chang G, Bencardino JT, Babb JS, Rokito A, et al. Evaluation of subchondral bone marrow lipids of acute anterior cruciate ligament (ACL)-injured patients at 3 T. *Acad Radiol.* 2014;21(6):758-66.
- Pai A, Li X, Majumdar S. A comparative study at 3 T of sequence dependence of T2 quantitation in the knee. *Magn Reson Imaging.* 2008;26(9):1215-20.
- Teruel JR, Burghardt AJ, Rivoire J, Srikkum W, Noworolski SM, Link TM, et al. Bone structure and perfusion quantification of bone marrow edema pattern in the wrist of patients with rheumatoid arthritis: a multimodality study. *J Rheumatol.* 2014;41(9):1766-73.
- Karampinos DC, Ruschke S, Dieckmeyer M, Diefenbach M, Franz D, Gersing AS, et al. Quantitative MRI and spectroscopy of bone marrow. *J Magn Reson Imaging.* 2018;47(2):332-53.
- Schreiner MM, Raudner M, Marlovits S, Bohndorf K, Weber M, Zalaudek M, et al. The MOCART (magnetic resonance observation of cartilage repair tissue) 2.0 knee score and atlas. *Cartilage.* 2021;13:571S-587S.
- Peterfy CG, Schneider E, Nevitt M. The osteoarthritis initiative: report on the design rationale for the magnetic resonance imaging protocol for the knee. *Osteoarthritis Cartilage.* 2008;16(12):1433-41.
- Baum T, Joseph GB, Karampinos DC, Jungmann PM, Link TM, Bauer JS. Cartilage and meniscal T2 relaxation time as non-invasive biomarker for knee osteoarthritis and cartilage repair procedures. *Osteoarthritis Cartilage.* 2013;21(10):1474-84.
- Smith HE, Mosher TJ, Dardzinski BJ, Collins BG, Collins CM, Yang QX, et al. Spatial variation in cartilage T2 of the knee. *J Magn Reson Imaging.* 2001;14(1):50-5.
- Maier CF, Tan SG, Hariharan H, Potter HG. T2 quantitation of articular cartilage at 1.5 T. *J Magn Reson Imaging.* 2003;17(3):358-64.
- Ruschke S, Weidlich D, Wu M, Hoch A, Karampinos DC. Single-voxel short-TR multi-TI multi-TE (SHORTIE) STEAM for water-fat magnetic resonance spectroscopy. *Proc Int Soc Magn Reson Med.* 2019;27:4230.
- Dieckmeyer M, Ruschke S, Cordes C, Yap SP, Kooijman H, Hauner H, et al. The need for T(2) correction on MRS-based vertebral bone marrow fat quantification: implications for bone marrow fat fraction age dependence. *NMR Biomed.* 2015;28(4):432-9.
- Jungmann PM, Welsch GH, Brittberg M, Trattng S, Braun S, Imhoff AB, et al. Magnetic resonance imaging score and classification system (AMADEUS) for assessment of preoperative cartilage defect severity. *Cartilage.* 2017;8(3):272-82.
- Runer A, Jungmann P, Welsch G, Kummel D, Impellizzeri F, Preiss S, et al. Correlation between the AMADEUS score and preoperative clinical patient-reported outcome measurements (PROMs) in patients undergoing matrix-induced autologous chondrocyte implantation (MACI). *J Orthop Surg Res.* 2019;14(1):87.
- Roos EM, Engelhart L, Ranstam J, Anderson AF, Irrgang JJ, Marx RG, et al. ICRS recommendation document: patient-reported outcome instruments for use in patients with articular cartilage defects. *Cartilage.* 2011;2(2):122-36.

27. Tegner Y, Lysholm J. Rating systems in the evaluation of knee ligament injuries. *Clin Orthop Relat Res.* 1985;198:43-9.
28. Lysholm J, Gillquist J. Evaluation of knee ligament surgery results with special emphasis on use of a scoring scale. *Am J Sports Med.* 1982;10(3):150-4.
29. Jungmann PM, Kraus MS, Nardo L, Liebl H, Alizai H, Joseph GB, *et al.* T(2) relaxation time measurements are limited in monitoring progression, once advanced cartilage defects at the knee occur: longitudinal data from the osteoarthritis initiative. *J Magn Reson Imaging.* 2013;38(6):1415-24.
30. Gersing AS, Feuerriegel G, Holwein C, Suchowierski J, Karampinos DC, Haller B, *et al.* T2-relaxation time of cartilage repair tissue is associated with bone remodeling after spongiosa-augmented matrix-associated autologous chondrocyte implantation. *Osteoarthritis Cartilage.* 2019;27(1):90-8.
31. Blackman AJ, Smith MV, Flanigan DC, Matava MJ, Wright RW, Brophy RH. Correlation between magnetic resonance imaging and clinical outcomes after cartilage repair surgery in the knee: a systematic review and meta-analysis. *Am J Sports Med.* 2013;41(6):1426-34.
32. Ebert JR, Robertson WB, Woodhouse J, Fallon M, Zheng MH, Ackland T, *et al.* Clinical and magnetic resonance imaging-based outcomes to 5 years after matrix-induced autologous chondrocyte implantation to address articular cartilage defects in the knee. *Am J Sports Med.* 2011;39(4):753-63.
33. Welsch GH, Trattng S, Hughes T, Quirbach S, Olk A, Blanke M, *et al.* T2 and T2* mapping in patients after matrix-associated autologous chondrocyte transplantation: initial results on clinical use with 3.0-Tesla MRI. *Eur Radiol.* 2010;20(6):1515-23.
34. Trattng S, Mamisch TC, Welsch GH, Glaser C, Szomolanyi P, Gebetsroither S, *et al.* Quantitative T2 mapping of matrix-associated autologous chondrocyte transplantation at 3 Tesla: an in vivo cross-sectional study. *Invest Radiol.* 2007;42(6):442-8.
35. Domayer SE, Welsch GH, Dorotka R, Mamisch TC, Marlovits S, Szomolanyi P, *et al.* MRI monitoring of cartilage repair in the knee: a review. *Semin Musculoskelet Radiol.* 2008;12(4):302-17.
36. Ebert JR, Fallon M, Wood DJ, Janes GC. A prospective clinical and radiological evaluation at 5 years after arthroscopic matrix-induced autologous chondrocyte implantation. *Am J Sports Med.* 2017;45(1):59-69.
37. Gursoy S, Akkaya M, Simsek ME, Gursoy M, Dogan M, Bozkurt M. Factors influencing the results in matrix-associated autologous chondrocyte implantation: a 2-5 year follow-up study. *J Clin Med Res.* 2019;11(2):137-44.
38. Dhollander AA, Huyse WC, Verdonk PC, Verstraete KL, Verdonk R, Verbruggen G, *et al.* MRI evaluation of a new scaffold-based allogenic chondrocyte implantation for cartilage repair. *Eur J Radiol.* 2010;75(1):72-81.
39. Henderson I, Francisco R, Oakes B, Cameron J. Autologous chondrocyte implantation for treatment of focal chondral defects of the knee—a clinical, arthroscopic, MRI and histologic evaluation at 2 years. *Knee.* 2005;12(3):209-16.
40. Niemeyer P, Porichis S, Steinwachs M, Erggelet C, Kreuz PC, Schmal H, *et al.* Long-term outcomes after first-generation autologous chondrocyte implantation for cartilage defects of the knee. *Am J Sports Med.* 2014;42(1):150-7.
41. Niethammer TR, Valentin S, Gulecyuz MF, Rossbach BP, Ficklscherer A, Pietschmann MF, *et al.* Bone marrow edema in the knee and its influence on clinical outcome after matrix-based autologous chondrocyte implantation: results after 3-year follow-up. *Am J Sports Med.* 2015;43(5):1172-9.
42. Takahashi T, Tins B, McCall IW, Richardson JB, Takagi K, Ashton K. MR appearance of autologous chondrocyte implantation in the knee: correlation with the knee features and clinical outcome. *Skeletal Radiol.* 2006;35(1):16-26.
43. Calvi M, Curti M, Ossola C, Duvia M, Angeretti MG, Ronga M, *et al.* Knee articular cartilage injury treatment with matrix-induced autologous chondrocyte implantation (MACI): correlation at 24 and 120 months between clinical and radiological findings using MR arthrography. *Skeletal Radiol.* 2021;50:2079-90.
44. Felson DT, Niu J, Guermazi A, Roemer F, Aliabadi P, Clancy M, *et al.* Correlation of the development of knee pain with enlarging bone marrow lesions on magnetic resonance imaging. *Arthritis Rheum.* 2007;56(9):2986-92.
45. Torres L, Dunlop DD, Peterfy C, Guermazi A, Prasad P, Hayes KW, *et al.* The relationship between specific tissue lesions and pain severity in persons with knee osteoarthritis. *Osteoarthritis Cartilage.* 2006;14(10):1033-40.
46. Filardo G, Kon E, Di Martino A, Perdisa F, Busacca M, Tentoni F, *et al.* Is the clinical outcome after cartilage treatment affected by subchondral bone edema. *Knee Surg Sports Traumatol Arthrosc.* 2014;22(6):1337-44.
47. Vasiliadis HS, Danielson B, Ljungberg M, McKeon B, Lindahl A, Peterson L. Autologous chondrocyte implantation in cartilage lesions of the knee: long-term evaluation with magnetic resonance imaging and delayed gadolinium-enhanced magnetic resonance imaging technique. *Am J Sports Med.* 2010;38(5):943-9.
48. Marcacci M, Andriolo L, Kon E, Filardo G. Bone marrow edema and results after cartilage repair. *Ann Transl Med.* 2015;3(10):132.
49. Zanetti M, Bruder E, Romero J, Hodler J. Bone marrow edema pattern in osteoarthritic knees: correlation between MR imaging and histologic findings. *Radiology.* 2000;215(3):835-40.
50. Bergman AG, Willen HK, Lindstrand AL, Pettersson HT. Osteoarthritis of the knee: correlation of subchondral MR signal abnormalities with histopathologic and radiographic features. *Skeletal Radiol.* 1994;23(6):445-8.
51. Wang L, Salibi N, Chang G, Vieira RL, Babb JS, Krasnokutsky S, *et al.* Assessment of subchondral bone marrow lipids in healthy controls and mild osteoarthritis patients at 3T. *NMR Biomed.* 2012;25(4):545-55.
52. Kim JK, Vaidya R, Lee SK, Yu J, Park JY, Ro DH, *et al.* Clinical and radiological changes after microfracture of knee chondral lesions in middle-aged Asian patients. *Clin Orthop Surg.* 2019;11(3):282-90.