

# CT-fusion-guided transseptal puncture in a patient with atrial fibrillation and absent right superior vena cava



Felix Bourier, MD, Sonia Ammar, MD, Tilko Reents, MD, Gabriele Hessling, MD, Isabel Deisenhofer, MD, FHRS

*From the Department of Electrophysiology, German Heart Center Munich, Technische Universitaet Munich, Munich, Germany.*

## Introduction

Pulmonary vein isolation (PVI) is the standard treatment option in interventional electrophysiological therapy of atrial fibrillation. Three-dimensional (3D) mapping systems are commonly employed to guide PVI procedures. This report demonstrates how 3D mapping systems may be applied beyond their standard use to facilitate transseptal puncture and PVI in a case of challenging cardiac anatomy.

## Case report

A 77-year-old woman with a history of symptomatic paroxysmal atrial fibrillation was referred for PVI. The preprocedural computed tomographic (CT) angiography (Somatom Definition Flash; Siemens AG, Munich, Germany) revealed a persistent left superior vena cava (PLSVC) with an absent right superior vena cava (ARSVC) and an otherwise normal anatomy. The CARTO 3 segmentation tool (Biosense Webster, Diamond Bar, CA) was used to create a 3D reconstruction of the left atrium (LA), the right atrium (RA), the PLSVC, the aorta, and the spine (Figure 1). Because of ARSVC, the usual positioning of the transseptal needle in the right vena cava superior to perform a pull-down maneuver into the fossa ovalis was impossible. A deflectable sheath (Agilis; St Jude Medical, St Paul, MN) was placed in the PLSVC, and angiograms (30° right

anterior oblique [RAO] and 60° left anterior oblique [LAO] view) were acquired by injecting contrast agent through the deflectable sheath. The CARTO3 Univu module was then used to overlay the segmented 3D anatomy onto RAO and LAO fluoroscopic views. Then, CARTO3 was used to register the overlaid anatomy to the fluoroscopic angiograms. Both the spine and the PLSVC angiogram served as registration landmarks. For registration, the 3D reconstructed spine and PLSVC were congruently aligned to their fluoroscopic counterparts in RAO and LAO views; Figure 2 depicts this step for the PLSVC. Once registration was performed, the overlay visualization was automatically updated to altered C-Arm angulations and table shifts. An octopolar mapping catheter (Bard Electrophysiology EP XT; Boston Scientific, Marlborough, MA) was placed in the PLSVC. The deflectable sheath, including the dilatator and the transseptal needle (BRK1; St Jude Medical), was positioned in the RA at the estimated position of the fossa ovalis. The RAO and LAO views with overlaid 3D anatomy in CARTO Univu verified the position of the needle at a suitable puncture site (Figure 3). Transseptal puncture was performed without problems, a guide-wire was placed in the left superior pulmonary vein, and the transseptal sheath was then advanced into the LA. Subsequently, the radiofrequency ablation catheter (Thermocool SF; Biosense Webster) was guided into the LA by CARTO Univu without any use of fluoroscopy. PVI was achieved en bloc for the left and right pulmonary veins at an antral level. The procedure time was 87 minutes, with a fluoroscopy time of 4 minutes, a dose area product 308 cGycm<sup>2</sup>, and a radiofrequency time of 20 minutes. After 6 months of follow-up, there was no recurrence of atrial fibrillation.

**KEYWORDS** Atrial fibrillation; Transseptal puncture; Electrophysiology mapping; Overlay; Persistent left superior vena cava

**ABBREVIATIONS** 3D = 3-dimensional; ARSVC = absent right superior vena cava; CT = computed tomographic; LA = left atrium; LAO = left anterior oblique; PLSVC = persistent left superior vena cava; PVI = pulmonary vein isolation; RA = right atrium; RAO = right anterior oblique (Heart Rhythm Case Reports 2015;1:323–325)

Conflicts of interest: All authors declare no conflicts of interest. **Address reprint requests and correspondence:** Dr Felix Bourier, Department of Electrophysiology, German Heart Center Munich, Lazarettstraße, 36, 80636 Munich, Germany. E-mail address: fbouier@gmail.com.

## Discussion

PLSVC is the most common congenital thoracic venous anomaly, with a prevalence of 0.5% in the general population.<sup>1,2</sup> Among PLSVC patients, 20% are additionally

### KEY TEACHING POINTS

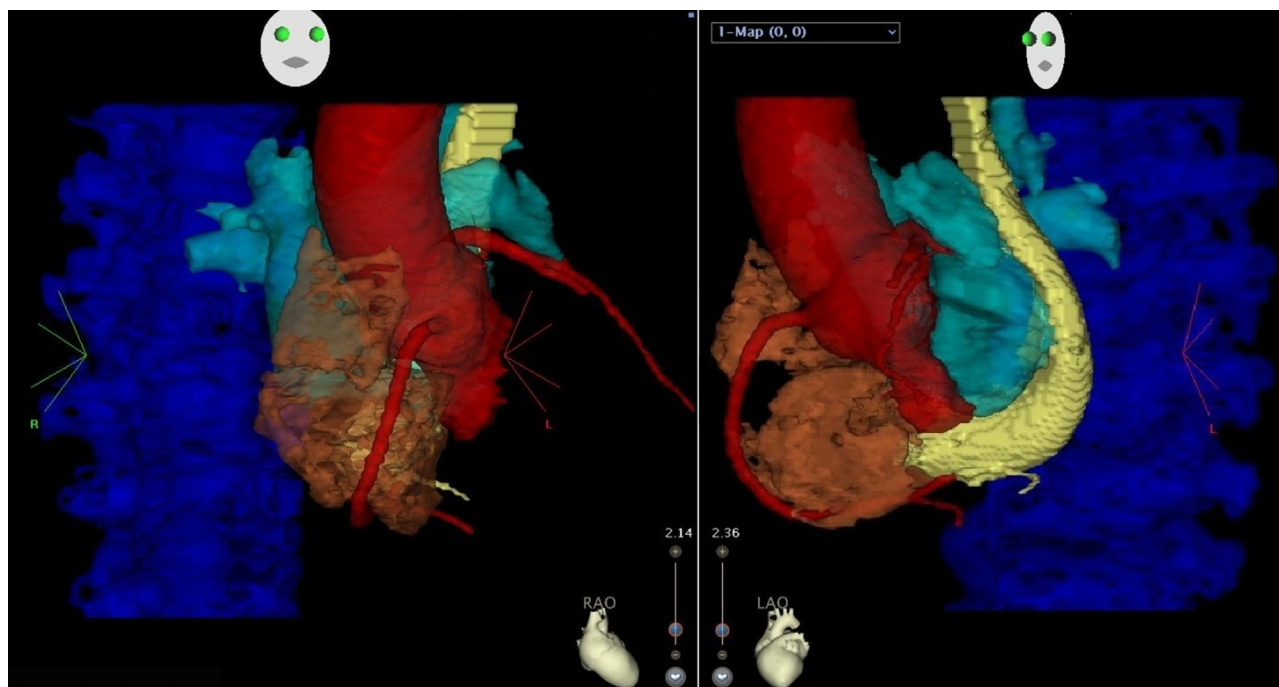
- Awareness of cardiac anatomic abnormalities in preprocedural imaging prior to an ablation procedure is essential to the success of the procedure.
- Fusing 3-dimensional segmentation of computed tomography or magnetic resonance imaging data sets with conventional fluoroscopy results is an effective method to help visualize challenging cardiac anatomy.
- The 3-dimensional computed tomography–anatomy scan overlay technique offers a new approach to guide transseptal puncture.

affected by an ARSVC,<sup>3</sup> which makes the common standard approach of transseptal puncture impossible. Previous studies showed that 3D overlay registration (created out of standardly preprocedurally acquired 3D slice imaging) in

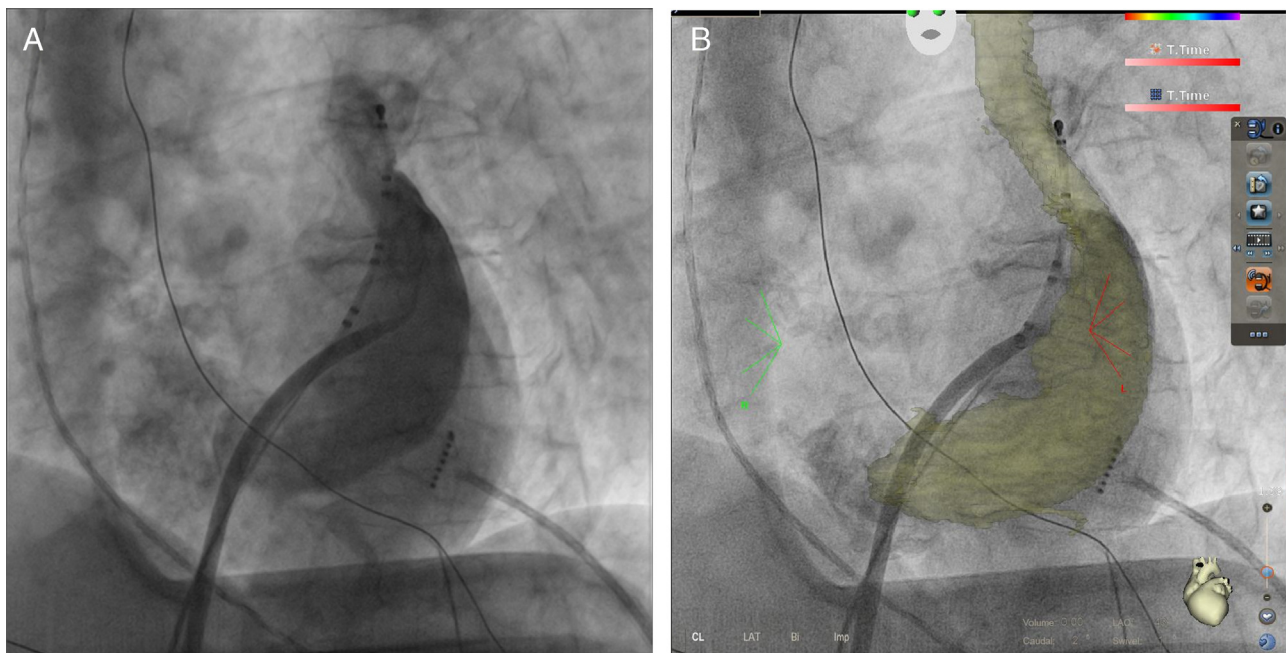
PVI procedures<sup>4</sup> and the CARTO3 system itself<sup>5</sup> operate at high levels of accuracy. In our case, we used the technique to visualize biatrial anatomy, which enabled us to perform a transseptal puncture without complications. The 3D overlay approach directly integrates all relevant anatomic structures into fluoroscopy. Intracardiac echocardiography could have been an alternative imaging method to guide transseptal puncture in this case. Intracardiac echocardiography offers a direct real-time view onto the atrial septum and the LA on a separate monitor and is known to reliably and safely obtain transseptal access as well.<sup>6</sup>

### Conclusions

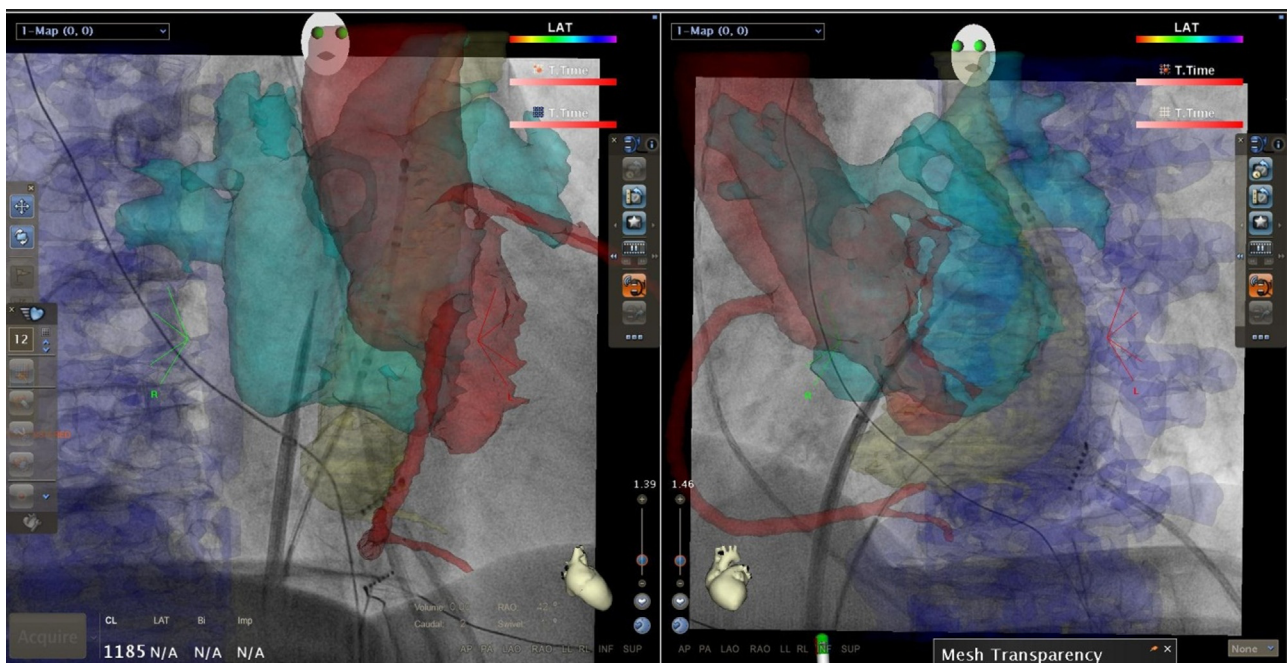
This case report demonstrates how transseptal puncture can be facilitated by overlaying segmented 3D anatomic images onto real-time fluoroscopic imaging in a patient with PLSVC and ARSVC. Our approach does not require any relevant additional efforts. It saves fluoroscopy time and increases the safety of the procedure.



**Figure 1** Right anterior oblique (RAO) and left anterior oblique (LAO) views of the segmented computed tomography data set in CARTO3. The left atrium is displayed in light blue, the right atrium in brown, the persistent left superior vena cava in yellow, the aorta in red, and the spine in blue.



**Figure 2** A: The image shows a left anterior oblique fluoroscopic view of the spine, a diagnostic catheter placed in the persistent left superior vena cava (PLSVC), and an angiogram of the PLSVC using the deflectable sheath. B: The segmented PLSVC is registered in this image.



**Figure 3** Right anterior oblique (RAO) and left anterior oblique (LAO) views of the overlaid 3-dimensional anatomy in CARTO3 Univu at the moment of transseptal puncture. The aorta and the spine served, respectively, as anterior and posterior landmarks for the puncture. A standard quadrupolar mapping catheter was placed in the persistent left superior vena cava. The transseptal needle, the dilator, and the deflectable sheath were advanced into the left atrium. The aorta and the spine served, respectively, as anterior posterior landmarks for the puncture.

## References

- Goyal SK, Punnam SR, Verma G, Ruberg FL. Persistent left superior vena cava: a case report and review of literature. *Cardiovasc Ultrasound* 2008;6:1–4.
- Lenox CC, Zuberhuhler JR, Park SC, Neches WH, Mathews RA, Fricker FJ, Bahnsen HT, Siewers RD. Absent right superior vena cava with persistent left superior vena cava: implications and management. *Am J Cardiol* 1980;45:117–122.
- Konecky N, Freedberg RS, McCauley D, Kronzon I. Absent right and persistent left superior vena cava without other congenital anomaly: a rare combination diagnosed by transesophageal echocardiography. *J Am Soc Echocardiogr* 1995;8:761–766.
- Bourier F, Vukajlovic D, Brost A, Hornegger J, Strobel N, Kurzidim K. Pulmonary vein isolation supported by MRI-derived 3D-augmented biplane fluoroscopy: a feasibility study and a quantitative analysis of the accuracy of the technique. *J Cardiovasc Electrophysiol* 2013;24:113–120.
- Bourier F, Fahrig R, Wang P, Santangeli P, Kurzidim K, Strobel N, Moore T, Hinkel C, Al-Ahmad A. Accuracy assessment of catheter guidance technology in electrophysiology procedures. *J Cardiovasc Electrophysiol* 2014;25:74–83.
- Daoud EG, Kalbfleisch SJ, Hummel JD. Intracardiac echocardiography to guide transseptal left heart catheterization for radiofrequency catheter ablation. *J Cardiovasc Electrophysiol* 1999;10:358–363.