

Longitudinal Retinal Changes in MOGAD

Frederike Cosima Oertel, MD, PhD ^{1,2,3#} Elias S. Sotirchos, MD ^{4#}
 Hanna G. Zimmermann, PhD ^{1,2} Seyedamirhosein Motamedi, PhD ^{1,2}
 Svenja Specovius, MSc,^{1,2} Eva Susanna Asseger, MD,^{1,2} Claudia Chien, PhD,^{1,2}
 Lawrence Cook, PhD,⁵ Eleni Vasileiou, MD ⁴ Angeliki Filippatou, MD ⁴
 Peter A. Calabresi, MD ⁴ Shiv Saidha, MBBCh,⁴ Lekha Pandit, MD, PhD ⁶
 Anitha D'Cunha, PhD,⁶ Olivier Outteryck, MD, PhD,⁷ H el ene Z ephir, MD, PhD ⁷
 Sean Pittock, MD ⁸ Eoin P. Flanagan, MBBCh,⁸ M. Tariq Bhatti, MD,⁸ Paulus S. Rommer, MD,⁹
 Gabriel Bsteh, MD, PhD ⁹ Tobias Zrzavy, MD, PhD ⁹ Tania Kuempfel, MD ¹⁰
 Orhan Aktas, MD,¹¹ Marius Ringelstein, MD ^{11,12} Philipp Albrecht, MD ¹¹
 Ilya Aizenberg, MD,^{13,14} Thivya Pakeerathan,^{13,14} Benjamin Khier, MD ¹⁵ Lilian Aly, MD ¹⁵
 Nasrin Asgari, MD, PhD,¹⁶ Kerstin Soelberg, MD,¹⁷ Romain Marignier, MD, PhD ¹⁸
 Caroline Froment Tilikete, MD,¹⁸ Alvaro Cobo Calvo, MD, PhD,^{18,19}
 Pablo Villoslada, MD, PhD ²⁰ Bernardo Sanchez-Dalmau, MD, PhD,²⁰
 Elena H. Martinez-Lapiscina, MD, PhD,²⁰ Sara Llufr u, MD,²⁰ Ari J. Green, MD,³
 Michael R. Yeaman, MD, PhD,^{21,22} Terry J. Smith, MD,^{23,24} Alexander U. Brandt, MD ^{1,2,25}
 John Chen, MD, PhD,^{8,26†} Friedemann Paul, MD ^{1,2,27†} and Joachim Havla, MD,^{10,28†}

with the GJCF International Clinical Consortium for NMOSD and the CROCTINO study group

View this article online at [wileyonlinelibrary.com](https://onlinelibrary.wiley.com/doi/10.1002/ana.26440). DOI: 10.1002/ana.26440

Received Aug 24, 2021, and in revised form Jun 9, 2022. Accepted for publication Jun 10, 2022.

Address correspondence to Dr Paul, Charit -Universit tsmedizin Berlin, Charit platz 1, 10117 Berlin, Germany. E-mail: friedemann.paul@charite.de

[#]These authors contributed equally to this work and should be considered co-first authors.

[†]These authors contributed equally to this work and should be considered co-last authors.

From the ¹Experimental and Clinical Research Center, Max Delbr ck Center for Molecular Medicine and Charit  – Universit tsmedizin Berlin, corporate member of Freie Universit t Berlin and Humboldt-Universit t zu Berlin, Berlin, Germany; ²NeuroCure Clinical Research Center, Charit  – Universit tsmedizin Berlin, corporate member of Freie Universit t Berlin and Humboldt-Universit t zu Berlin, Berlin, Germany; ³Department of Neurology, University of California San Francisco, San Francisco, CA; ⁴Department of Neurology, Johns Hopkins University School of Medicine, Baltimore, MD; ⁵Department of Pediatrics, University of Utah, Salt Lake City, UT; ⁶Department of Neurology, KS Hegde Medical Academy, Nitte University, Mangalore, India; ⁷Department of Neuroradiology, CHU Lille, Universit  de Lille, Lille, Hauts-de-France, France; ⁸Department of Neurology, Mayo Clinic, Rochester, MN; ⁹Department of Neurology, Medical University of Vienna, Vienna, Austria; ¹⁰Institute of Clinical Neuroimmunology, Biomedical Center and University Hospital, Ludwig-Maximilians-Universit t M nchen, Munich, Germany; ¹¹Department of Neurology, Medical Faculty, Heinrich Heine University D sseldorf, D sseldorf, Germany; ¹²Department of Neurology, Center for Neurology and Neuropsychiatry, LVR-Klinikum, Heinrich-Heine-University D sseldorf, D sseldorf, Germany; ¹³Department of Neurology, St. Josef Hospital, Ruhr University Bochum, Bochum, Germany; ¹⁴Department of Neurology, I.M. Sechenov First Department of Neurology, I.M. Sechenov First Moscow State Medical University, Moscow, Russia; ¹⁵Department of Neurology, Klinikum rechts der Isar, School of Medicine, Technical University of Munich, Munich, Germany; ¹⁶Departments of Neurology, Lillebaelt & Slagelse Hospitals, Denmark; ¹⁷Institute of Regional Health Research and of Molecular Medicine, University of Southern Denmark, Odense, Denmark; ¹⁸Departments of Neurology, Multiple Sclerosis, Myelin Disorders, and Neuroinflammation, Pierre Wertheimer Neurological Hospital, Hospices Civils de Lyon, Lyon, France; ¹⁹Centre d'Esclerosi M ltiple de Catalunya (Cemcat). Department of Neurology/Neuroimmunology, Hospital Universitari Vall d'Hebron, Universitat Aut noma de Barcelona, Barcelona, Spain; ²⁰Hospital Clinic of Barcelona-Institut d'Investigacions, Biom diques August Pi Sunyer, (IDIBAPS), Barcelona, Spain; ²¹Division of Molecular Medicine, Harbor - University of California at Los Angeles (UCLA) Medical Center, Torrance, CA; ²²Department of Medicine, David Geffen School of Medicine at University of California at Los Angeles (UCLA), Los Angeles, CA; ²³Departments of Ophthalmology and Visual Sciences, Kellogg Eye Center, University of Michigan, Ann Arbor, MI; ²⁴Division of Metabolism, Endocrine, and Diabetes, Department of Internal Medicine, University of Michigan Medical School, Ann Arbor, MI; ²⁵Department of

Objective: Patients with myelin oligodendrocyte glycoprotein antibody (MOG-IgG)-associated disease (MOGAD) suffer from severe optic neuritis (ON) leading to retinal neuro-axonal loss, which can be quantified by optical coherence tomography (OCT). We assessed whether ON-independent retinal atrophy can be detected in MOGAD.

Methods: Eighty patients with MOGAD and 139 healthy controls (HCs) were included. OCT data was acquired with (1) Spectralis spectral domain OCT (MOGAD: $N = 66$ and HCs: $N = 103$) and (2) Cirrus high-definition OCT (MOGAD: $N = 14$ and HCs: $N = 36$). Macular combined ganglion cell and inner plexiform layer (GCIPL) and peripapillary retinal nerve fiber layer (pRNFL) were quantified.

Results: At baseline, GCIPL and pRNFL were lower in MOGAD eyes with a history of ON (MOGAD-ON) compared with MOGAD eyes without a history of ON (MOGAD-NON) and HCs ($p < 0.001$). MOGAD-NON eyes had lower GCIPL volume compared to HCs ($p < 0.001$) in the Spectralis, but not in the Cirrus cohort. Longitudinally (follow-up up to 3 years), MOGAD-ON with ON within the last 6–12 months before baseline exhibited greater pRNFL thinning than MOGAD-ON with an ON greater than 12 months ago ($p < 0.001$). The overall MOGAD cohort did not exhibit faster GCIPL thinning compared with the HC cohort.

Interpretation: Our study suggests the absence of attack-independent retinal damage in patients with MOGAD. Yet, ongoing neuroaxonal damage or edema resolution seems to occur for up to 12 months after ON, which is longer than what has been reported with other ON forms. These findings support that the pathomechanisms underlying optic nerve involvement and the evolution of OCT retinal changes after ON is distinct in patients with MOGAD.

ANN NEUROL 2022;92:476–485

Patients with myelin oligodendrocyte glycoprotein antibody (MOG-IgG) associated disease (MOGAD) often suffer from severe and recurrent optic neuritis (ON) episodes, which can lead to significantly impaired visual acuity and visual quality of life.^{1–4} In neuropathological studies, MOGAD is characterized by multiple sclerosis (MS)-like pathology, with an immune response directed against myelin and oligodendrocytes leading to complement deposition and inflammatory demyelination.^{3,5–8} Yet, MOGAD is considered a distinct entity from MS. In recent years, it has been shown that ON in MOGAD is often associated with extreme optic disc and retinal nerve fiber layer (RNFL) edema in the acute phase with subsequent marked retinal neurodegeneration.^{2,7,9,10}

Assumptions regarding the dynamics of retinal layer thickness changes following ON in less common etiologies like MOGAD are often made based on studies in MS. In MS, the inner retinal layer thinning appears to be predominantly complete by ~6 months after ON.^{11,12} Furthermore, it has been well established in MS that accelerated progressive inner retinal layer thinning (compared with normal aging) occurs independently of clinical episodes of ON.^{13,14} In an exploratory, longitudinal, multicenter study on the long-term course of adult MOGAD using optical coherence tomography (OCT), we previously observed ON-independent thinning of the peripapillary RNFL (pRNFL) in MOGAD, but no significant thinning was observed in the macular composite ganglion cell and inner plexiform layer (GCIPL).² This phenomenon was mainly detectable in the eyes of patients with relapses (including contralateral ON) shortly before study

entry, but it was unclear when and why this occurred. This could suggest (1) a prolonged neurodegenerative process of the retina after ON, (2) a prolonged time-course of resolution of severe oedema, (3) retinal damage induced by relapse-treatment (such as high-dose steroids), or (4) a combination of these effects.

Hence, we initiated a large international multicenter study of retinal imaging in patients with MOGAD to clarify whether (1) subclinical inner retinal layer thinning independent of ON exists in MOGAD and (2) if previous recent ON >6 months before baseline may account for such findings.

Materials and Methods

Study Design and Population

The study presented here is as an international, multicenter, retrospective, longitudinal study. Cross-sectional and longitudinal analyses of the available data were performed. We enrolled 80 patients with MOGAD and 139 healthy controls (HCs). Some of the patients had already been described in previous cross-sectional^{4, 9, 10} and longitudinal analyses.² Parts of the data were acquired via the Collaborative Retrospective Study on retinal OCT in Neuromyelitis Optica (CROCTINO) study within the Guthy-Jackson Charitable Foundation network.^{15,16} For participating centers and contributors, please refer to Tables S1 and S2, respectively. Inclusion criteria were (1) a diagnosis of MOGAD according to the suggested criteria by Jarius et al¹⁷ with evidence of MOG-IgG as well as clinical MOGAD symptomatology, (2) age of at least 18 years, (3) follow-up (F/U) of at least 1 year between at least 2 examinations, (4) OCT ring scan (pRNFL) and/or macular volume scans with at least 3 mm diameter for each visit, and (5) patients must not have had a clinical episode of ON within 6 months of the baseline scan and during the

Neurology, University of California, Irvine, CA;²⁶Department of Ophthalmology, Mayo Clinic, Rochester, MN;²⁷Department of Neurology, Charité – Universitätsmedizin Berlin, corporate member of Freie Universität Berlin and Humboldt-Universität zu Berlin, Berlin, Germany; and²⁸Data Integration for Future Medicine (DIFUTURE) Consortium, LMU Hospital, Ludwig-Maximilians Universität München, Munich, Germany

Additional supporting information can be found in the online version of this article.

course of the study. The risk of overlooked subclinical ON prior to baseline or subclinical ON during F/U was further minimized by excluding patients with a baseline absolute inter-eye-difference in the pRNFL of $\geq 7 \mu\text{m}$ or a change in the inter-eye difference during follow-up of $\geq 7 \mu\text{m}$, respectively, in accordance with the threshold proposed by Nolan et al¹⁸ – as well as confirmatory using a baseline percentage inter-eye difference in the GCIPL of $\geq 5\%$ (data not shown). Additionally, the presence of clinical/functional data during the F/U period and at the date of OCT acquisition (expanded disability status scale [EDSS], type and number of attacks, treatment, etc.) were recorded. Any other neurological or ophthalmological comorbidities (glaucoma, diabetes mellitus, retinal surgery, retinal disease, and refractive error >6 diopters) potentially influencing OCT results were classified as exclusion criteria. For detection of MOG-IgG serum, serum samples from all patients were analyzed at least once with established cell-based assays at the discretion of the respective center using laboratory cutoffs.¹⁹ Written informed consent was obtained from all patients participating in the study. Local ethics committees approved the study protocol in accordance with the Declaration of Helsinki (1964) as amended.

Optical Coherence Tomography

Data of high-resolution OCT images from 2 different spectral domain (SD) OCT instrument types were included: Spectralis SD-OCT (Heidelberg Engineering, Heidelberg, Germany) from 11 centers and Cirrus HD-OCT (Carl Zeiss Meditec, Dublin, CA) from 2 centers. OCT quality control was performed according to OSCAR-IB criteria.^{20,21} Segmentation and analysis were performed semi-automatically using software provided by the OCT manufacturer and controlled by the responsible OCT experts at the respective centers.

Two cohorts were studied in the present work: (1) the Spectralis SD-OCT cohort (Spectralis cohort), and (2) the Cirrus HD-OCT cohort (Cirrus cohort). All centers using the Spectralis SD-OCT applied the automatic real-time (ART) function for image averaging. In this cohort, pRNFL thickness and volumes of GCIPL and inner nuclear layer (INL) were obtained. GCIPL and INL were calculated as cylinders 3 mm in diameter around the fovea from a macular volume scan (25×30 degrees, 61 vertical B-scans or 20×20 degrees, 25 vertical B-scans). The pRNFL was measured with the eye tracker activated using ring scans around the optic nerve (12 degrees, 1,536 A-scans) or the innermost ring of a star-and-ring scan around the optic nerve (12 degrees, 768 A-scans). For the Cirrus HD-OCT, peripapillary scans were acquired using the Optic Disc Cube 200×200 protocol (which covers a $6 \times 6 \text{ mm}^2$ area centered on the optic disc) and the pRNFL thickness measurements were obtained using the conventional software on the device, as previously described. Macular scans were obtained using the Macular Cube 512×128 Cirrus protocol centered on the fovea, and the GCIPL segmentation and measurement was performed using conventional Cirrus HD-OCT software, which measures the GCIPL thickness in an elliptical annulus around the fovea (the vertical inner and outer radii of 0.5 and 2.0 mm, respectively, that are stretched 20% in the horizontal axis). INL was not available in the Cirrus group.

Statistical Methods

All statistical analyses and graphical representations were performed with R version 4.1.0.²² Statistical significance was established at $p < 0.05$. All parameters are described as mean \pm standard deviation (SD), if not stated otherwise. OCT parameter comparisons were performed using linear mixed effect models for baseline comparisons (with group, age, and sex as fixed effects, and subject and center as random effects), longitudinal within-group analyses (with F/U time, age at baseline, and sex as fixed effects, and the center and [subject/subject-eye] as random effects) and longitudinal between-group comparisons (with [F/U time*group], age at baseline and sex as fixed effects, and center and [subject/subject-eye] as random effects).

Results

Cohort Description and F/U Data

In the Spectralis cohort, we included 66 patients with MOGAD (126 eyes) from 9 centers and 103 HCs (206 eyes) from 6 centers. The Spectralis MOGAD group included 69 (55%) eyes of 43 patients (65%) with a history of ON (MOGAD-ON) with a median of 1 ON per eye (range = 1–5; not available for $N = 1$) and a median of 25 months (interquartile range [IQR] = 11–84 months) from most recent ON to OCT (not available for $N = 7$). Fifty-seven eyes had no history of ON (MOGAD-NON; 45%). Due to different study protocols, F/U data were only available for 86 eyes of 43 patients with MOGAD.

In the Cirrus cohort, we included 14 patients with MOGAD (27 eyes) and 36 HCs (72 eyes) from 2 centers. The Cirrus MOGAD group included 22 (81%) MOGAD-ON eyes of 13 patients with a median of 1 attack (range = 1–6) and a median of 15 months (IQR = 9–23 months) from the time of the most recent ON to OCT. In contrast to the Spectralis cohort, only 5 (17%) eyes were MOGAD-NON. F/U data were available for all patients with MOGAD and HCs. We excluded possible subclinical ON episodes prior to baseline in non-ON eyes based on the inter-eye pRNFL difference (Analyses S1). We had retrospective data on the lesion location of the ON episodes for a subset of our cohort (Table S3). Characteristics are described in further detail for a subset of this cohort in Chen et al 2022.²³ The demographic and clinical characteristics of all included patients are shown in Table 1.

Cross-Sectional Comparisons of OCT Measures between Groups

First, we analyzed group differences at baseline among MOGAD-ON, MOGAD-NON, and HC eyes (Table 2, Figure 1). For both (Spectralis and Cirrus) cohorts, pRNFL and GCIPL thicknesses were significantly lower in MOGAD-ON compared with MOGAD-NON and with HCs. In the Spectralis cohort, INL volume was higher in MOGAD-ON compared with MOGAD-NON and HCs ($p < 0.001$). In both cohorts, eyes that had

TABLE 1. Cohort Description for Patients With MOGAD and HCs for Cirrus (left) and Spectralis Cohort (Right)

	Cirrus cohort		Spectralis cohort	
	HCs	MOGAD	HCs	MOGAD
Subjects, <i>N</i>	36	14	103	66
Eyes, <i>N</i>	72	27	206	126
Age, yr, mean ± SD	44 ± 12	45 ± 14	36 ± 14	38 ± 14
Sex, male, <i>N</i> (%)	13 (36)	5 (36)	41 (40)	32 (49)
Ethnicity, <i>N</i> (%)				
Asian	0 (0)	0 (0)	0 (0)	12 (18)
White	36 (100)	14 (100)	103 (100)	53 (80)
Other or unknown	0 (0)	0 (0)	0 (0)	1 (2)
Follow-up time, mo, median (IQR)	31 (22–36)	27 (13–36)	35 (23–65)	25 (15–36)
Time since disease onset, yr, median (IQR)		3 (1–5)		3 (1–8)
EDSS, median (min-max)		1.5 (1.0–2.0)		2.0 (1.0–2.5)
Patients with a history of ON, <i>N</i> (%)		13 (93)		43 (65)
Eyes with a history of ON, <i>N</i> (%)		22 (81)		69 (55)
Time since last ON, mo, median (IQR)		15 (9–23)		25 (11–84)

EDSS = expanded disability status scale; HCs = healthy controls; IQR = interquartile range; mo = months; MOGAD = myelin oligodendrocyte glycoprotein antibody associated disease; *N* = number; OCT = optical coherence tomography; ON = optic neuritis episode; SD = standard deviation, yr = years.

Table 2. Baseline Comparisons of OCT Thicknesses Among HCs, MOGAD-ON, and MOGAD-NON for the Cirrus and Spectralis Cohorts

	HCs	MOGAD		HCs versus MOGAD-ON			HC versus MOGAD-NON			MOGAD-ON versus MOGAD-NON		
		NON	ON	<i>B</i>	SE	<i>p</i>	<i>B</i>	SE	<i>P</i>	<i>B</i>	SE	<i>P</i>
Cirrus cohort												
<i>N</i>	72	5	22									
pRNFL, μm , mean ± SD	91.9 ± 10.3	98.0 ± 4.4	64.2 ± 13.3	-26.9	3.4	<0.001	6.1	5.3	0.26	-35.2	6.2	<0.001
GCIPL, μm , mean ± SD	81.9 ± 6.2	82.6 ± 7.0	63.3 ± 11.1	-18.5	2.5	<0.001	-0.3	3.4	0.93	-17.6	5.2	0.003
Spectralis cohort												
<i>N</i>	206	57	69									
pRNFL, μm , mean ± SD	99.1 ± 8.9	94.9 ± 12.4	64.3 ± 21.3	-36.0	2.3	<0.001	-4.6	1.7	0.008	-29.5	2.9	<0.001
GCIPL, mm^3 , mean ± SD	0.62 ± 0.05	0.57 ± 0.07	0.43 ± 0.11	-0.18	0.01	<0.001	-0.05	0.01	<0.001	-0.130	0.015	<0.001
INL, mm^3 , mean ± SD	0.27 ± 0.02	0.27 ± 0.03	0.29 ± 0.04	0.03	<0.01	<0.001	-0.01	0.004	0.18	0.019	0.004	<0.001

B = estimate; GCIPL = ganglion cell and inner plexiform layer; HCs = healthy controls; INL = inner nuclear layer; MOGAD-NON = eyes without a history of optic neuritis episode; MOGAD-ON = eyes with a history of optic neuritis episode; MOGAD = myelin oligodendrocyte glycoprotein antibody associated disease; OCT = optical coherence tomography; ON = optic neuritis episode; pRNFL = peripapillary retinal nerve fiber layer thickness; SD = standard deviation; SE = standard error.

experienced a single ON episode (MOGAD-1-ON) had markedly lower pRNFL and GCIPL thicknesses compared with MOGAD-NON. This difference was accentuated in eyes with 2 (MOGAD-2-ON) or >2 episodes (MOGAD-3-ON; Table 3).

When comparing MOGAD-NON eyes with HCs, the Spectralis cohort had a lower GCIPL (MOGAD-NON = $0.57 \pm 0.07 \text{ mm}^3$, HCs = $0.62 \pm 0.05 \text{ mm}^3$, $p < 0.001$) and pRNFL (MOGAD-NON = $94.9 \pm 12.4 \text{ }\mu\text{m}$, HCs = $99.1 \pm 8.9 \text{ }\mu\text{m}$, $p = 0.008$), but the comparisons were not significantly different in the Cirrus cohort. To better understand this effect in the Spectralis cohort, we compared MOGAD-NON eyes with ($N = 12$) and without a history of contralateral ON ($N = 45$). The two groups had comparable GCIPL ($0.57 \pm 0.07 \text{ mm}^3$ for both). Yet, MOGAD-NON eyes with a history of contralateral ON had lower pRNFL

thickness ($90.1 \pm 14.2 \text{ }\mu\text{m}$) compared with MOGAD-NON without a history of contralateral ON ($96.2 \pm 11.7 \text{ }\mu\text{m}$), although the comparison was not statistically significant ($p = 0.20$). Similar findings (but in a lower sample size) were observed in the Cirrus cohort for MOGAD-NON eyes with a history of contralateral ON ($N = 3$, pRNFL = $95.7 \pm 4.0 \text{ }\mu\text{m}$, GCIPL = $79.3 \pm 7.6 \text{ }\mu\text{m}$) compared with MOGAD-NON eyes without a history of contralateral ON ($N = 2$, pRNFL = $101.5 \pm 2.1 \text{ }\mu\text{m}$, GCIPL = $87.5 \pm 0.7 \text{ }\mu\text{m}$).

Longitudinal Analysis of OCT Measure Change

Within the Spectralis cohort, we observed longitudinally significant pRNFL thinning ($p < 0.001$), which was not accompanied by significant progressive GCIPL reduction ($p = 0.86$; Table 4, Figure 2). For the Cirrus cohort, we

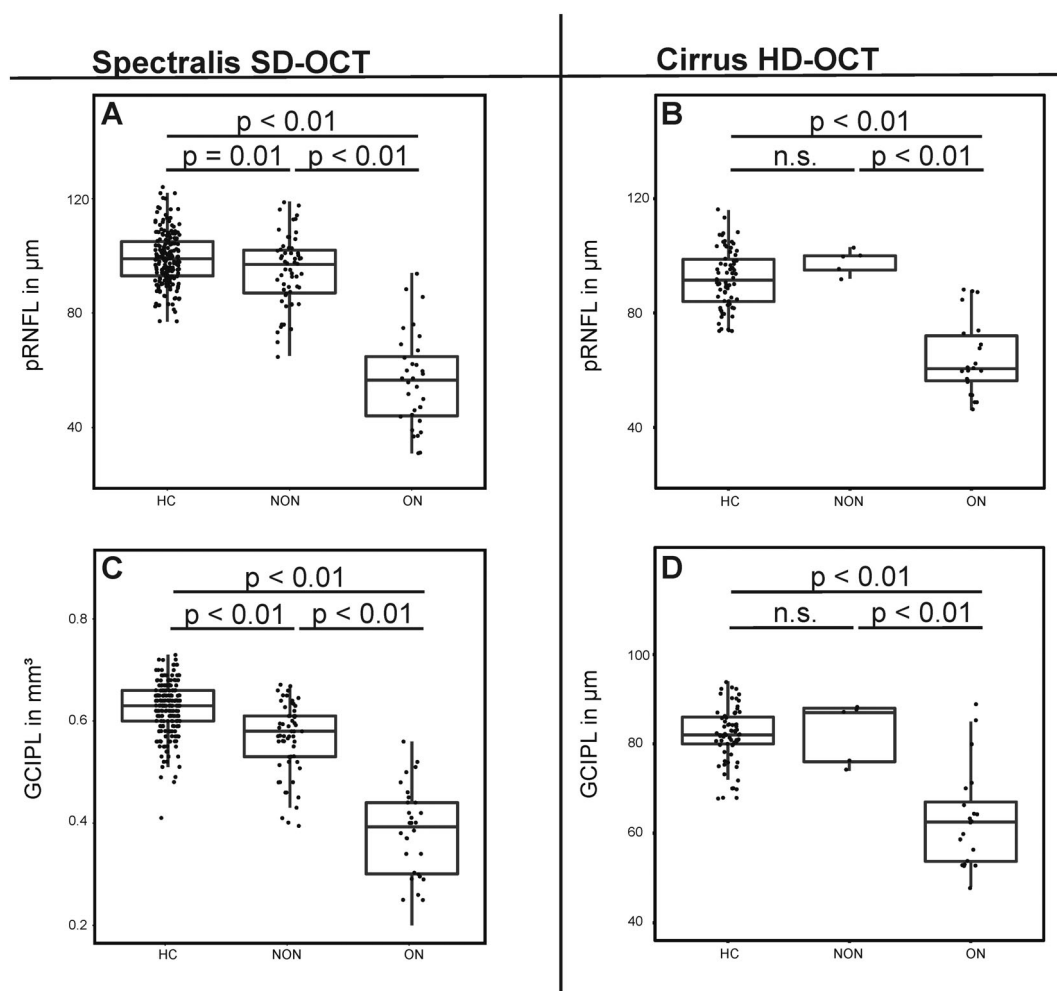


FIGURE 1: Boxplots for baseline OCT thicknesses by group measured by Spectralis (A, C) and Cirrus (B, D) for healthy controls (HCs; left), MOGAD eyes without a history of ON (NON; middle) and MOGAD eyes with a history of ON (ON; right). Boxplots overlaid with individual values as dots display (A) pRNFL (Spectralis), (B) pRNFL (Cirrus), (C) GCIPL (Spectralis), and (D) GCIPL (Cirrus). GCIPL = ganglion cell and inner plexiform layer; HCs = healthy controls; HD-OCT = high-definition optical coherence tomography; MOGAD = myelin oligodendrocyte glycoprotein antibody associated disease; NON = MOGAD eyes without a history of ON; ON = optic neuritis episode; p = p value; pRNFL = peripapillary retinal nerve fiber layer; SD-OCT = spectral domain optical coherence tomography.

Table 3. Baseline Comparisons of OCT Thicknesses Between MOGAD-ON with Different Numbers of ON Episodes for the Cirrus and Spectralis Cohorts

	MOGAD-ON			MOGAD-1-ON versus MOGAD-NON			MOGAD-2-ON versus MOGAD-1-ON			MOGAD-3-ON versus MOGAD-2-ON		
	1	2	≥3	<i>B</i>	SE	<i>p</i>	<i>B</i>	SE	<i>p</i>	<i>B</i>	SE	<i>p</i>
Cirrus cohort												
<i>N</i>	12	3	7									
pRNFL, μm, mean ± SD	68.3 ± 15.0	54.3 ± 7.4	61.3 ± 9.6	-7.6	2.0	0.012	-13.6	3.0	0.02	-4.7	5.3	0.43
GCIPL, μm, mean ± SD	65.8 ± 12.7	54.3 ± 7.1	62.8 ± 6.4	-3.9	1.5	0.044	-10.6	2.5	0.02	-1.0	1.0	0.49
Spectralis cohort												
<i>N</i>	37	19	12									
pRNFL, μm, mean ± SD	72.0 ± 20.1	57.1 ± 19.9	49.4 ± 14.1	-23.4	3.4	<0.001	-11.0	5.5	0.05	-2.9	7.1	0.68
GCIPL, mm ³ , mean ± SD	0.5 ± 0.1	0.4 ± 0.1	0.4 ± 0.1	-0.11	0.02	<0.001	-0.05	0.03	0.07	-0.06	0.04	0.21

B = estimate; GCIPL = ganglion cell and inner plexiform layer; INL = inner nuclear layer; MOGAD-ON = eyes with a history of optic neuritis episode; MOGAD-NON = eyes without a history of optic neuritis episode; MOGAD-1-ON = eyes with a history of 1 optic neuritis episode; MOGAD-2-ON = eyes with a history of 2 optic neuritis episodes; MOGAD-3-ON = eyes with a history of 3 or more optic neuritis episodes; MOGAD = myelin oligodendrocyte glycoprotein antibody associated disease; OCT = optical coherence tomography; ON = optic neuritis episode; pRNFL = peripapillary retinal nerve fiber layer thickness; SD = standard deviation; SE = standard error.

found longitudinally significant pRNFL ($p = 0.001$) and GCIPL thinning ($p = 0.002$) within MOGAD (combining MOGAD-ON and MOGAD-NON). Compared with HCs this progressive thinning was only significant for pRNFL in the Spectralis cohort, but not significantly faster compared with HCs for GCIPL in either cohort or for pRNFL in the Cirrus cohort.

In the Spectralis cohort, relapses other than ON attacks during F/U did not appear to have augmenting influence on rates of pRNFL atrophy (data not shown). Furthermore, we compared MOGAD-ON with an ON

6–12 months before baseline versus MOGAD-ON with an ON >12 months before baseline. In both cohorts, the longitudinal pRNFL thinning was more pronounced in MOGAD-ON with an ON 6–12 months before baseline compared with MOGAD-ON >12 months before baseline (Spectralis: $B = -0.10$, SE = 0.02, $p < 0.001$ |Cirrus: $B = 1.63$, SE = 0.43, $p < 0.001$). GCIPL thinning did only differ between groups in the Cirrus cohort (Spectralis: $B < 0.001$, SE < 0.001, $p = 0.58$ |Cirrus: $B = -0.74$, SE = 0.25, $p = 0.005$). Additional analyses of ON and non-ON eyes from both cohorts can be found in analyses S2.

Table 4. Longitudinal Changes of OCT Thicknesses for the Cirrus and Spectralis Cohorts

	MOGAD (within group)			MOGAD versus HCs		
	<i>B</i>	SE	<i>p</i>	<i>B</i>	SE	<i>p</i>
Cirrus cohort (HCs [$N = 72$] MOGAD [$N = 27$])						
pRNF, μm/yr	-0.371	0.106	0.001	-0.256	0.170	0.13
GCIPL, μm/yr	-0.205	0.063	0.002	-0.045	0.081	0.58
Spectralis cohort (HC [$N = 206$] MOGAD [$N = 86$])						
pRNFL, μm/mo	-0.080	0.012	<0.001	-0.098	0.015	<0.001
GCIPL, mm ³ /mo	<0.001	<0.001	0.86	<0.001	<0.001	0.09
INL, mm ³ /mo	-0.002	0.005	0.65	-0.004	0.004	0.32

B = estimate; GCIPL = ganglion cell and inner plexiform layer; HCs = healthy controls; INL = inner nuclear layer; MOGAD = myelin oligodendrocyte glycoprotein antibody associated disease; OCT = optical coherence tomography; pRNFL = peripapillary retinal nerve fiber layer thickness; SD = standard deviation; SE = standard error.

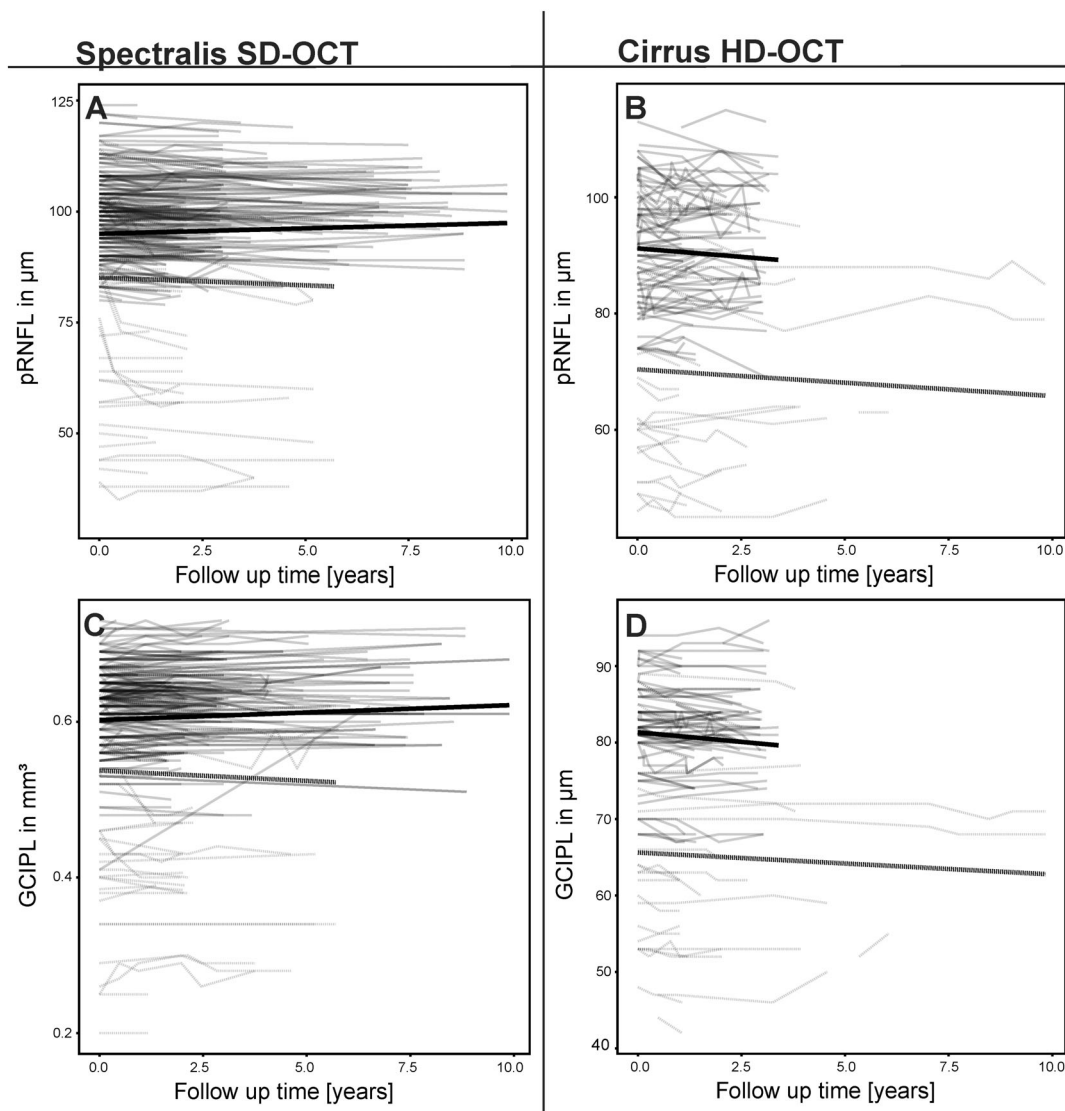


FIGURE 2: Longitudinal OCT thicknesses by group measured by Spectralis (A, C) and Cirrus (B, D) for HCs (continuous black line) and MOGAD (dashed gray line). Lines (thin) for individual eye-based trajectories overlaid with predicted line for mixed linear effect model (thick) for (A) pRNFL (Spectralis), (B) pRNFL (Cirrus), (C) GCIPL (Spectralis), (D) GCIPL (Cirrus). Plotted for maximum F/U for GCIPL. F/U = follow-up; GCIPL = ganglion cell and inner plexiform thickness; HCs = healthy controls; MOGAD = myelin oligodendrocyte glycoprotein antibody associated disease; NON = MOGAD eyes without a history of ON; OCT = optical coherence tomography; pRNFL = peripapillary retinal nerve fiber layer thickness.

Discussion

This analysis aimed to evaluate whether subclinical neuro-axonal degeneration occurs independently of disease activity in MOGAD and found no evidence of subclinical progressive neurodegeneration or of relapse-independent retinal neurodegeneration in patients with MOGAD compared with HCs. In contrast, the analyses suggest a prolonged influence of ON attacks on retinal measurements and a slowed remission of edematous changes that occurs over 12 months after an ON attack. This was confirmed in 2 distinct cohorts with 2 different OCT devices respectively – although to a different extent.

Previous cross-sectional studies have shown conflicting results on whether MOGAD-ON patients have a more favorable outcome regarding neuro-axonal content compared with ON patients with other demyelinating conditions. This is of major interest because it may have direct implications for the use of medication to prevent relapses.^{3,9,10,24,25} Confirming previous reports, we were able to show consistently severe neuroaxonal retinal degeneration after MOGAD-ON. The pRNFL and GCIPL degeneration depended on the number of ONs with higher ON-numbers causing more neuroaxonal damage. Yet, both cohorts showed the greatest decrease in pRNFL and GCIPL after the first ON, whereas subsequent ONs

appeared to lead to less absolute changes.²⁶ These data are in line with the experience with ON in MS and in aquaporin-4-antibody (AQP4-IgG) positive neuromyelitis optica spectrum disorder (NMOSD). An explanation for the different extent of inner retinal layer thinning after initial ON versus subsequent ON attacks is most likely accounted for by a “basement effect” (ie, approaching maximal possible atrophy of the retinal layer, due to other constituents of these layers including glial cells, blood vessels, and extracellular matrix), but more aggressive and early acute therapy or preventative immunotherapy may also contribute.²

In this study, we were able to gain valuable further insights into ON-mediated retinal neuro-axonal degeneration in MOGAD. However, uncertainty remains as to whether ON-independent retinal neuroaxonal degeneration occurs in MOGAD. The Spectralis and Cirrus cohorts showed some longitudinal loss of neuroaxonal tissue, but the rates of change did not differ from HCs. Furthermore, when eyes with ON within 6–12 months of the baseline OCT were excluded, there was no significant longitudinal pRNFL thinning. Considering the influence of potential chiasmal crossover effects and previous ON episodes shown by our analyses, we currently do not assume a neuro-axonal retinal degeneration independent of relapses.² Nevertheless, chiasmal crossover from contralateral ON is considered a rare event in MOGAD-ON and some uncertainty remains.²⁷

Subgroup analyses showed that the group of patients with MOGAD with ON within 6–12 months before baseline exhibited significantly faster pRNFL thinning compared to those with ON >12 months before baseline. The most likely explanation for this finding may be ongoing resolution of pRNFL swelling due to edema and/or ongoing neurodegeneration. Based on our data, we recommend at least 12 months of stable disease before inclusion of participants in OCT studies investigating longitudinal ON-independent change in MOGAD. In addition, our findings support that pRNFL thickness change following MOGAD-ON may follow different kinetics compared to MS.^{12,28,29} In addition, other non-ON relapses during F/U could affect this outcome, for example, via trans-synaptic degeneration or generalized subclinical inflammatory activity.

Our data underscore the previously proposed distinctiveness of MOGAD compared with MS suggesting that the assumptions drawn from MS are not necessarily suitable to explain changes in MOGAD. Our findings are also different from AQP4-IgG positive NMOSD, an astrocytopathy, which has been proposed to have a primary antibody-associated retinopathy supported by animal and clinical studies.^{16,26,30–33} Interestingly, prior studies have reported that longitudinal GCIPL and pRNFL

atrophy occurs in AQP4-IgG positive NMOSD independent of ON attacks,^{16,26,31} which has also been consistently shown in MS.³⁴ This is in contrast to the data presented here in our MOGAD cohort and is supported by the fact that the retina does not contain myelin-producing oligodendrocytes and expression of MOG has not been detected, making primary retinopathy due to MOG-IgG unlikely. Yet, a direct comparison to prove these distinct features of retinal pathology might be valuable in the future.

This international, multicenter, and largest longitudinal OCT analysis in MOGAD to date has overcome previous limitations of smaller studies through collaboration of expert centers worldwide. However, limitations exist: the data were acquired retrospectively and on 2 different OCT devices – with longitudinal HC data not available for all of them. All patients with MOGAD were included regardless of clinical presentation and regime of immunosuppressive treatment. Thus, there is a large heterogeneity of associated clinical phenotypes that improves the generalizability of the results. Due to the rarity of the disease, the sample size is also relatively small, despite being the largest study of this topic to date. As a result, outliers may have a greater impact on the results and the robustness of results, especially longitudinally, might be impacted.

In conclusion, our longitudinal analysis of inner retinal layer thickness changes in MOGAD presented here reflects the heterogeneity of the scientific data with a broad classification of MOGAD-ON. By using 2 OCT devices, we could confirm a relapse-dependent, longitudinal pRNFL decrease in MOGAD up to 12 months after ON. However, we did not find evidence for subclinical relapse-independent neuroaxonal retinal degeneration. This analysis demonstrates a retinal phenotype in MOGAD-ON, which is distinct from AQP4-IgG positive NMOSD and MS. This delineation supports the classification of MOGAD as a distinct disease entity and is a further argument for the creation of MOGAD-specific treatment regimens.³⁵ In preparation of future prospective studies of ON-independent retinal changes, it is recommended to restrict analyses to patients with ON relapses >12 months before baseline to minimize relapse-dependent effects.

Acknowledgments

J.H. and F.C.O. would like to thank Charlotte Bereuter, Angelika Bamberger, and Luise Böhm for their excellent technical support. This study was funded in part by the Guthy-Jackson Charitable Foundation. J.H. is (partially) funded by the German Federal Ministry of Education and Research (Grant Numbers 01ZZ1603[A-D] and

01ZZ1804[A-H] DIFUTURE). F.C.O. received research support by the German Association of Neurology (Deutsche Gesellschaft für Neurologie) in context of this work and would like to thank the American Academy of Neurology (AAN) and the National Multiple Sclerosis Society (NMSS) for their research support. Open Access funding enabled and organized by Projekt DEAL.

Author Contributions

F.C.O., E.S.S., J.C., F.P., and J.H. contributed to the concept and design of the study. H.G.Z., S.M., S.v.S., C.C., L.C., A.J.G., M.R.Y., T.J.S., A.G., A.U.B., E.V., A.F., P.A.C., Sh.S., L.P., A.D.C., O.O., S.P., E.P.F., P.S.R., G.B., T.Z., T.K., O.A., M.R., P.A., I.A., B.K., L.A., N.A., K.S., R.M., C.F.T., A.C.C., P.V., B.S.D., and E.H.M.L. contributed to the acquisition and analysis of data. F.C.O., J.H. and E.S.S. drafted the text and prepared the figures. Other contributors of the CROCTINO study group and their institutional affiliations are included in Table S2.

Potential Conflicts of Interest

A.U.B. is cofounder and shareholder of Nocturne. He is named as inventor on several patent applications regarding OCT image analysis. The other authors have nothing to report.

Data Availability

The data supporting the findings of this study are available within the article and from the corresponding author by reasonable request.

References

- Schmidt F, Zimmermann H, Mikolajczak J, et al. Severe structural and functional visual system damage leads to profound loss of vision-related quality of life in patients with neuromyelitis optica spectrum disorders. *Mult Scler Relat Disord* 2017;11:45–50.
- Oertel FC, Outteryck O, Knier B, et al. Optical coherence tomography in myelin-oligodendrocyte-glycoprotein antibody-seropositive patients: a longitudinal study. *J Neuroinflammation* 2019;16:154.
- Filippatou AG, Mukharesh L, Saidha S, et al. AQP4-IgG and MOG-IgG related optic neuritis-prevalence, optical coherence tomography findings, and visual outcomes: a systematic review and meta-analysis. *Front Neurol* 2020;11:540156.
- Sotirchos ES, Filippatou A, Fitzgerald KC, et al. Aquaporin-4 IgG seropositivity is associated with worse visual outcomes after optic neuritis than MOG-IgG seropositivity and multiple sclerosis, independent of macular ganglion cell layer thinning. *Mult Scler* 2019;1352458519864928:1360–1371.
- Spadaro M, Gerdes LA, Mayer MC, et al. Histopathology and clinical course of MOG-antibody-associated encephalomyelitis. *Ann Clin Transl Neurol* 2015;2:295–301.
- Jarius S, Metz I, König FB, et al. Screening for MOG-IgG and 27 other anti-glial and anti-neuronal autoantibodies in “pattern II multiple sclerosis” and brain biopsy findings in a MOG-IgG-positive case. *Mult Scler* 2016;22:1541–1549.
- Höftberger R, Guo Y, Flanagan EP, et al. The pathology of central nervous system inflammatory demyelinating disease accompanying myelin oligodendrocyte glycoprotein autoantibody. *Acta Neuropathol* 2020;139:875–892.
- Takai Y, Misu T, Kaneko K, et al. Myelin oligodendrocyte glycoprotein antibody-associated disease: an immunopathological study. *Brain* 2020;143:1431–1446.
- Pache F, Zimmermann H, Mikolajczak J, et al. MOG-IgG in NMO and related disorders: a multicenter study of 50 patients. Part 4: afferent visual system damage after optic neuritis in MOG-IgG-seropositive versus AQP4-IgG-seropositive patients. *J Neuroinflammation* 2016;13:282.
- Havla J, Kümpfel T, Schinner R, et al. Myelin-oligodendrocyte-glycoprotein (MOG) autoantibodies as potential markers of severe optic neuritis and subclinical retinal axonal degeneration. *J Neurol* 2017;264:139–151.
- Syc SB, Saidha S, Newsome SD, et al. Optical coherence tomography segmentation reveals ganglion cell layer pathology after optic neuritis. *Brain* 2012;135:521–533.
- Andorrà M, Alba-Arbalat S, Camos-Carreras A, et al. Using acute optic neuritis trials to assess neuroprotective and Remyelinating therapies in multiple sclerosis. *JAMA Neurol* 2020;77:234–244.
- Petzold A, Balcer LJ, Calabresi PA, et al. Retinal layer segmentation in multiple sclerosis: a systematic review and meta-analysis. *Lancet Neurol* 2017;16:797–812.
- Sotirchos ES, Gonzalez Caldito N, Filippatou A, et al. Progressive multiple sclerosis is associated with faster and specific retinal layer atrophy. *Ann Neurol* 2020;87:885–896.
- Specovius S, Zimmermann HG, Oertel FC, et al. Cohort profile: a collaborative multicentre study of retinal optical coherence tomography in 539 patients with neuromyelitis optica spectrum disorders (CROCTINO). *BMJ Open* 2020;10:e035397.
- Oertel FC, Specovius S, Zimmermann HG, et al. Retinal optical coherence tomography in Neuromyelitis Optica. *Neurol Neuroimmunol Neuroinflamm* 2021;8:e1068. Available at: <https://nn.neurology.org/content/8/6/e1068>. Accessed September 15, 2021.
- Jarius S, Paul F, Aktas O, et al. MOG encephalomyelitis: international recommendations on diagnosis and antibody testing. *J Neuroinflammation* 2018;15:134.
- Nolan RC, Galetta SL, Frohman TC, et al. Optimal Intereye difference thresholds in retinal nerve fiber layer thickness for predicting a unilateral optic nerve lesion in multiple sclerosis. *J Neuroophthalmol* 2018;38:451–458.
- Reindl M, Schanda K, Woodhall M, et al. International multicenter examination of MOG antibody assays. *Neurol Neuroimmunol Neuroinflamm* 2020;7:e674.
- Tewarie P, Balk L, Costello F, et al. The OSCAR-IB consensus criteria for retinal OCT quality assessment. *PLoS ONE* 2012;7:e34823.
- Schippling S, Balk LJ, Costello F, et al. Quality control for retinal OCT in multiple sclerosis: validation of the OSCAR-IB criteria. *Mult Scler* 2015;21:163–170.
- R Development Core Team. *R: a language and environment for statistical computing [internet]*. Vienna, Austria: R Foundation for Statistical Computing, 2008 Available at: <http://www.R-project.org>.
- Chen JJ, Sotirchos ES, Henderson AD, et al. OCT retinal nerve fiber layer thickness differentiates acute optic neuritis from MOG antibody-associated disease and multiple sclerosis: RNFL thickening in acute optic neuritis from MOGAD vs MS. *Multiple Sclerosis and Related Disorders* 2022;58:103525. Available at: [https://www.msard-journal.com/article/S2211-0348\(22\)00040-2/fulltext](https://www.msard-journal.com/article/S2211-0348(22)00040-2/fulltext). Accessed January 13, 2022.

24. Sato DK, Callegaro D, Lana-Peixoto MA, et al. Distinction between MOG antibody-positive and AQP4 antibody-positive NMO spectrum disorders. *Neurology* 2014;82:474–481.
25. Akaishi T, Nakashima I, Takeshita T, et al. Different etiologies and prognoses of optic neuritis in demyelinating diseases. *J Neuroimmunol* 2016;299:152–157.
26. Oertel FC, Havla J, Roca-Fernández A, et al. Retinal ganglion cell loss in neuromyelitis optica: a longitudinal study. *J Neurol Neurosurg Psychiatry* 2018;89:1259–1265.
27. Ramanathan S, Prelog K, Barnes EH, et al. Radiological differentiation of optic neuritis with myelin oligodendrocyte glycoprotein antibodies, aquaporin-4 antibodies, and multiple sclerosis. *Mult Scler* 2016;22:470–482.
28. Costello F, Pan Yi, Yeh EA, et al. The temporal evolution of structural and functional measures after acute optic neuritis. *J Neurol Neurosurg Psychiatry* 2015;86:1369–1373.
29. Henderson APD, Altmann DR, Trip AS, et al. A serial study of retinal changes following optic neuritis with sample size estimates for acute neuroprotection trials. *Brain* 2010;133:2592–2602.
30. Felix CM, Levin MH, Verkman AS. Complement-independent retinal pathology produced by intravitreal injection of neuromyelitis optica immunoglobulin G. *J Neuroinflamm* 2016;13:275.
31. Filippatou AG, Vasileiou ES, He Y, et al. Optic neuritis-independent retinal atrophy in Neuromyelitis Optica Spectrum disorder. *J Neuroophthalmol* 2021;42:e40–e47.
32. Sotirchos ES, Saidha S, Byraiah G, et al. In vivo identification of morphologic retinal abnormalities in neuromyelitis optica. *Neurology* 2013;80:1406–1414.
33. Motamedi S, Oertel FC, Yadav SK, et al. Altered fovea in AQP4-IgG-seropositive neuromyelitis optica spectrum disorders. *Neurol Neuroimmunol Neuroinflamm* 2020;7:e805.
34. Balk LJ, Cruz-Herranz A, Albrecht P, et al. Timing of retinal neuronal and axonal loss in MS: a longitudinal OCT study. *J Neurol* 2016;263:1323–1331.
35. Marignier R, Hacoen Y, Cobo-Calvo A, et al. Myelin-oligodendrocyte glycoprotein antibody-associated disease. *Lancet Neurol* 2021;20:762–772.