


# Concentric vs Anteroposterior-Laterolateral Collapse of the Soft Palate in Patients With Obstructive Sleep Apnea

Eli Van de Perck, MD<sup>1,2</sup>, Clemens Heiser, MD, PhD<sup>3</sup>,  
 and Olivier M Vanderveken, MD, PhD<sup>1,2,4</sup>

Otolaryngology-  
 Head and Neck Surgery  
 2022, Vol. 166(4) 782-785  
 © American Academy of  
 Otolaryngology-Head and Neck  
 Surgery Foundation 2021  
 Reprints and permission:  
[sagepub.com/journalsPermissions.nav](http://sagepub.com/journalsPermissions.nav)  
 DOI: 10.1177/01945998211026844  
<http://otojournal.org>  


## Abstract

The presence of complete concentric collapse of the soft palate (CCCp) during drug-induced sleep endoscopy (DISE) has important therapeutic consequences. However, CCCp may present in various, sometimes doubtful, ways due to the complex anatomy of the upper airway. Herein, we aimed to characterize these doubtful variants by reviewing the DISE recordings of patients with obstructive sleep apnea ( $n = 332$ ). We observed in some individuals that the soft palate collapsed in an anteroposterior-laterolateral (AP-LL) way, producing a polygonal shape that was distinct from CCCp. Patients with this collapse pattern ( $n = 29$ ) had a smaller neck circumference and less severe obstructive sleep apnea than patients with CCCp ( $n = 68$ ). The majority of patients with AP-LL collapse ( $n = 19$ ) were originally diagnosed with CCCp. Based on these findings, AP-LL collapse of the soft palate might represent a distinct DISE phenotype that is easily confounded with CCCp.

## Keywords

DISE, sleep endoscopy, OSA, phenotype, upper airway collapse, agreement

Received January 15, 2021; accepted June 1, 2021.

Drug-induced sleep endoscopy (DISE) has become indispensable in clinical practice to evaluate treatment modalities other than positive airway pressure in patients with obstructive sleep apnea (OSA).<sup>1</sup> It provides a real-time, 3-dimensional snapshot of upper airway collapse during a sedative state mimicking sleep. One of the most pivotal findings during DISE is complete concentric collapse of the soft palate (CCCp), which is characterized by a sphincter-like, pinpoint appearance. Patients with this collapse pattern are not eligible for upper airway stimulation and have an increased risk of oral appliance treatment failure.<sup>2,3</sup> However, given the complex anatomy of the upper airway, CCCp can present in various, sometimes doubtful, ways. We observed in some individuals that the soft palate collapsed in an anteroposterior-laterolateral (AP-LL) configuration, producing a distinct triangular or rectangular shape (**Figure 1**).<sup>4</sup> We hypothesized that this AP-LL variant is associated with

different clinical characteristics than CCCp. Therefore, this study sought to distinguish both collapse types in a large cohort of consecutive DISE cases.

## Methods

The study population consisted of adult patients with polysomnographic diagnosis of OSA (apnea-hypopnea index [AHI]  $\geq 5$  events/h) undergoing DISE from July 1, 2018, through February 12, 2020. Ethical approval was waived by the local ethics committee at the University of Antwerp and Antwerp University Hospital in view of the retrospective nature of the study.

DISE was performed in a semidark and silent operating theater with patients lying in the supine position. No decongestants or local anesthetics were given prior to the examination. Artificial sleep was induced by intravenous bolus injection of midazolam (1.5 mg) and maintained by target-controlled infusion of propofol (2.0-3.0  $\mu\text{g/mL}$ ). A standardized scoring system was used to note the presence of upper airway collapse at the level of the soft palate, oropharynx, tongue base, hypopharynx, and epiglottis.<sup>5</sup> Only complete collapse of the soft palate was considered for analysis.

The collapse direction at the level of the soft palate (anteroposterior, concentric, or AP-LL; **Figure 1**) was reassessed by a single examiner (E.V.) who was blinded for patient characteristics. Agreement with a second examiner (O.M.V.) was evaluated by randomly selecting 77 DISE recordings with complete palatal collapse. This sample size was calculated a priori for a precision of 0.15 (halfwidth of 95% CI) and presumed kappa ( $\kappa$ ) of 0.80. Feedback was provided in the first 10 cases, after which all assessments were performed independently.

<sup>1</sup>Faculty of Medicine and Health Sciences, University of Antwerp, Antwerp, Belgium

<sup>2</sup>Department of Otorhinolaryngology-Head and Neck Surgery, Antwerp University Hospital, Edegem, Belgium

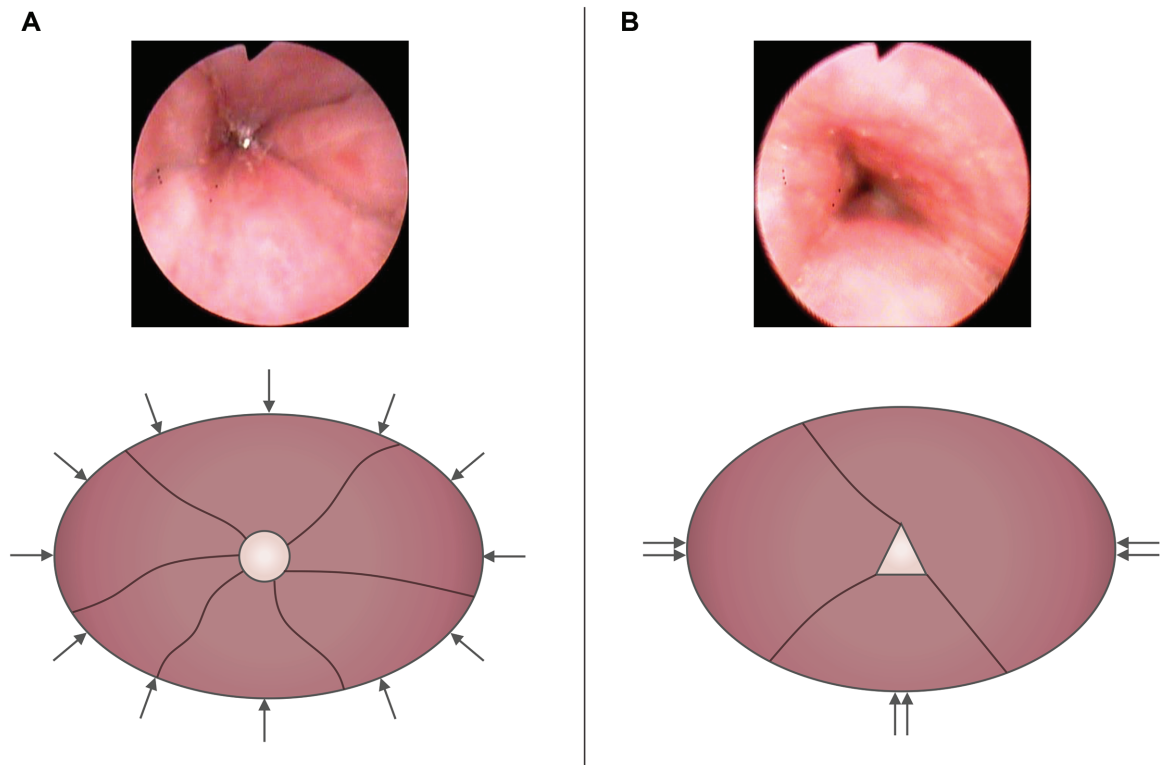
<sup>3</sup>Department of Otorhinolaryngology-Head and Neck Surgery, Klinikum rechts der Isar, Technische Universität München, Munich, Germany

<sup>4</sup>Multidisciplinary Sleep Disorders Centre, Antwerp University Hospital, Edegem, Belgium

## Corresponding Author:

Eli Van de Perck, MD, Department of Otorhinolaryngology-Head and Neck Surgery, Antwerp University Hospital, Drie Eikenstraat 655, Edegem, 2650, Belgium.

Email: [eli.vandeperck@uza.be](mailto:eli.vandeperck@uza.be)



**Figure 1.** Endoscopic example and schematic representation of collapse of the soft palate: (A) complete concentric and (B) anteroposterior-laterolateral collapse.

Categorical variables were summarized as frequencies (percentages) and continuous variables as mean (SD). One-way analysis of variance was conducted to compare clinical characteristics among different palatal collapse types. Interobserver agreement was evaluated by calculating the percentage agreement and Cohen's  $\kappa$  with the corresponding 95% CI. A  $P$  value  $<.05$  was considered statistically significant. All analyses were performed with JMP Pro software (version 14.3; SAS Institute).

## Results

The DISE recordings of 332 consecutive patients were reviewed (257 males, 77.4%; age, 49.4 [11.3] years; body mass index, 28.0 [4.0] kg/m<sup>2</sup>; AHI, 21.5 [16.4] events/h; minimal oxygen saturation, 86.5% [4.8%]). **Table 1** shows the frequency of upper airway collapse during DISE. Tongue base collapse was most common (61.4%), followed by complete palatal collapse (58.4%), oropharyngeal collapse (50.9%), epiglottis collapse (24.4%), and hypopharyngeal collapse (20.5%).

Of the 194 cases with complete palatal collapse, 97 (50.0%) were categorized as anteroposterior, 68 (35.1%) as concentric, and 29 (14.9%) as AP-LL. Clinical characteristics of each collapse type are listed in **Table 2**. Importantly, patients with complete AP-LL collapse had smaller neck circumferences (40.2 [2.7] vs 41.1 [2.9] cm) and less severe OSA (AHI, 20.2 [14.9] vs 29.5 [20.8] events/h) than patients with CCCp.

Among patients with AP-LL collapse, 19 (65.5%) were originally diagnosed with CCCp and 2 (6.9%) with complete anteroposterior collapse. The remaining 8 patients (27.6%)

were classified correctly. The frequency of CCCp decreased from 26.2% to 20.5% following DISE revision.

Assessment of the collapse direction at the level of the soft palate showed strong interobserver agreement ( $\kappa = 0.83$ ; 95% CI, 0.73-0.94;  $P < .001$ ), with 89.6% of cases (69/77; 95% CI, 80.8%-94.6%) being identically classified by the 2 reviewers (**Figure 2**).

## Discussion

The soft palate can collapse in various ways, complicating categorization of DISE findings at this level. This study explored the phenotype of CCCp and identified doubtful variants that generate AP-LL rather than concentric collapse. The latter collapse type was present in a considerable subset of patients. Contrary to CCCp, which results from circumferential upper airway narrowing, AP-LL collapse is characterized by a polygonal shape with few mucosal folds (**Figure 1**). Our results suggest that AP-LL collapse and CCCp are separate entities associated with different clinical characteristics. Distinguishing both collapse types led to a relatively low prevalence of CCCp as compared with previous research.<sup>6</sup>

More than half of patients with AP-LL collapse were initially diagnosed with CCCp. Therefore, this distinction may have important consequences, broadening therapeutic possibilities for some individuals with OSA.<sup>2</sup>

Based on our results, palatal collapse may be regarded as a spectrum of endoscopic patterns stretching from "true CCCp" to (partial) anteroposterior collapse. In our study, patients with AP-LL collapse had similar OSA severity but a

**Table 1.** Drug-Induced Sleep Endoscopy Findings.<sup>a</sup>

	Upper airway collapse		
	None	Partial	Complete
<b>Soft palate</b>			
None	31		
AP		75	97
LL			
Concentric		29	68
AP-LL		3	29
<b>Oropharynx</b>			
None	163		
AP			
LL		88	81
Concentric			
<b>Tongue base</b>			
None	128		
AP		82	122
LL			
Concentric			
<b>Epiglottis</b>			
None	251		
AP		18	56
LL		0	7
Concentric			
<b>Hypopharynx</b>			
None	264		
AP			
LL		46	22
Concentric			

Abbreviations: AP, anteroposterior; LL, laterolateral.

<sup>a</sup>Shaded areas represent collapse types that did not occur.**Table 2.** Comparison of Complete Palatal Collapse Types.

	Collapse type, mean (SD)			P value
	AP (n = 97)	AP-LL (n = 29)	CCCp (n = 68)	
Male sex <sup>a</sup>	75 (77.3)	24 (82.8)	61 (89.7)	.425 <sup>b</sup>
Age, y	51.0 (11.7)	49.3 (9.3)	48.6 (12.3)	.113
Body mass index, kg/m <sup>2</sup>	27.1 (3.7)	28.8 (4.4)	29.3 (4.1)	<.001
Neck circumference, cm	38.8 (3.5)	40.2 (2.7)	41.1 (2.9)	<.001
Events/h				
AHI	22.3 (18.1)	20.2 (14.9)	29.5 (20.8)	.022
OAHI	21.3 (16.8)	18.6 (13.3)	28.1 (19.9)	.016
ODI	15.0 (12.6)	16.3 (12.2)	22.2 (20.8)	.018
SaO <sub>2</sub> , %				
Mean	94.8 (1.3)	94.4 (1.3)	94.2 (1.6)	.016
Minimal	87.1 (3.8)	85.8 (5.0)	84.6 (6.5)	.013

Abbreviations: AHI, apnea-hypopnea index; AP, anteroposterior; CCCp, complete concentric collapse of the soft palate; LL, laterolateral; OAHI, obstructive apnea-hypopnea index; ODI, oxygen desaturation index; SaO<sub>2</sub>, oxygen saturation.<sup>a</sup>No. (%).<sup>b</sup>Fisher exact test.

Rater 2	AP-LL		5	10	
	Concentric		22	1	
	AP	37	1	1	
		Rater 1	AP	Concentric	AP-LL

**Figure 2.** Interobserver agreement for collapse direction at the level of the soft palate. AP, anteroposterior; AP-LL, anteroposterior-laterolateral.

different physique (being heavier) than patients with anteroposterior collapse. AHI and body mass index were highest in patients with CCCp, which is consistent with findings of other studies.<sup>6-8</sup> There exists some evidence that CCCp is a marker for increased pharyngeal collapsibility.<sup>9,10</sup> It is conceivable that AP-LL collapse is an intermediate phenotype that is associated with less severe collapsibility but can transition to CCCp in case of additional weight gain. Therefore, patients with AP-LL collapse might respond better to treatment with upper airway stimulation or oral appliances than patients with CCCp.

Limitations to our study include those inherent to the retrospective design. Additionally, DISE interpretation is subjective and largely dependent of the experience and judgment of the examiner. Since all observations were made by the same individual, the reproducibility of our findings may be limited. However, the agreement with an experienced observer for palatal collapse was high as compared with previous research,<sup>11-13</sup> indicating that AP-LL collapse can be reliably distinguished from other collapse types.

In conclusion, AP-LL collapse of the soft palate might represent a distinct DISE phenotype that is easily confounded with CCCp. This finding should prompt further research on the pathophysiology and therapeutic implications of palatal collapse.

**Author Contributions**

**Eli Van de Perck**, methodology, data collection, statistical analysis, drafting of the manuscript; **Clemens Heiser**, conceptualization, critical revision of the manuscript; **Olivier M. Vanderveken**, conceptualization, methodology, drafting of the manuscript, supervision.

**Disclosures**

**Competing interests:** Eli Van de Perck reports no competing interests. Clemens Heiser was a consultant for Inspire Medical Systems and received research grants from Inspire Medical Systems and

Nyxoah as well as consultancy fees, reimbursement of conference fees, and travel and accommodation expenses from Neuwirth Medical Products, Löwenstein, Jazz Pharma, and Sutter Medizintechnik, outside the submitted work. Olivier M. Vanderveken holds a senior clinical investigator fellowship from the Research Foundation Flanders (1833517N) and reports grants and personal fees from Somnomed, grants and nonfinancial support from Philips, personal fees and other from Inspire, and other from Nyxoah, outside the submitted work.

**Sponsorships:** None.

**Funding source:** None.

**References**

- De Vito A, Carrasco Llatas M, Ravesloot MJ, et al. European position paper on drug-induced sleep endoscopy: 2017 update. *Clin Otolaryngol.* 2018;43(6):1541-1552.
- Vanderveken OM, Maurer JT, Hohenhorst W, et al. Evaluation of drug-induced sleep endoscopy as a patient selection tool for implanted upper airway stimulation for obstructive sleep apnea. *J Clin Sleep Med.* 2013;9(5):433-438.
- Op de Beeck S, Dieltjens M, Verbruggen AE, et al. Phenotypic labelling using drug-induced sleep endoscopy improves patient selection for mandibular advancement device outcome: a prospective study. *J Clin Sleep Med.* 2019;15(8):1089-1099.
- Van de Perck E, Verbruggen AE, Vroegop AV, et al. Standardising drug-induced sleep endoscopy scoring by an expert review panel: our experience in 81 patients. *Clin Otolaryngol.* 2021; 46(4):878-882.
- Vroegop AV, Vanderveken OM, Dieltjens M, et al. Sleep endoscopy with simulation bite for prediction of oral appliance treatment outcome. *J Sleep Res.* 2013;22(3):348-355.
- Vroegop AV, Vanderveken OM, Boudewyns AN, et al. Drug-induced sleep endoscopy in sleep-disordered breathing: report on 1,249 cases. *Laryngoscope.* 2014;124(3):797-802.
- Ravesloot MJ, de Vries N. One hundred consecutive patients undergoing drug-induced sleep endoscopy: results and evaluation. *Laryngoscope.* 2011;121(12):2710-2716.
- Steffen A, Frenzel H, Wollenberg B, König IR. Patient selection for upper airway stimulation: is concentric collapse in sleep endoscopy predictable? *Sleep Breath.* 2015;19(4):1373-1376.
- Lan MC, Hsu YB, Lan MY, et al. The predictive value of drug-induced sleep endoscopy for CPAP titration in OSA patients. *Sleep Breath.* 2018;22(4):949-954.
- Seay EG, Keenan BT, Schwartz AR, Dedhia RC. Evaluation of therapeutic positive airway pressure as a hypoglossal nerve stimulation predictor in patients with obstructive sleep apnea. *JAMA Otolaryngol Head Neck Surg.* 2020;146(8):691-698.
- Vroegop AV, Vanderveken OM, Wouters K, et al. Observer variation in drug-induced sleep endoscopy: experienced versus non-experienced ear, nose, and throat surgeons. *Sleep.* 2013;36(6): 947-953.
- Carrasco-Llatas M, Zerpa-Zerpa V, Dalmau-Galofre J. Reliability of drug-induced sedation endoscopy: interobserver agreement. *Sleep Breath.* 2017;21(1):173-179.
- Bartier S, Blumen M, Chabolle F. Is image interpretation in drug-induced sleep endoscopy that reliable? *Sleep Breath.* 2020; 24(2):677-685.