



Review Article



Clinical review of cerebral venous thrombosis in the context of COVID-19 vaccinations: Evaluation, management, and scientific questions

Kiran T. Thakur^{a,*}, Arina Tamborska^{b,c}, Greta K. Wood^c, Emily McNeill^a, David Roh^a, Imo J. Akpan^d, Eliza C. Miller^a, Alyssa Bautista^a, Jan Claassen^a, Carla Y. Kim^a, Alla Guekht^e, Carlos A. Pardo^h, Olajide Williams^a, David García-Azorín^k, Kameshwar Prasadⁱ, Erich Schmutzhard^j, Benedict D. Michael^f, Sherry H.-Y. Chou^g, Andrea S. Winkler^{l,m}, Tom Solomon^b, Mitchell S. Elkind^a

^a Department of Neurology, Columbia University Irving Medical Center/New York Presbyterian Hospital, New York, NY, USA

^b National Institute for Health Research Health Protection Research Unit in Emerging and Zoonotic Infections, University of Liverpool, Liverpool, UK

^c Institute of Infection, Veterinary and Ecological Science, University of Liverpool, Liverpool, UK

^d Department of Hematology/Oncology, Columbia University Irving Medical Center/New York Presbyterian Hospital, New York, NY, USA

^e Moscow Research and Clinical Center for Neuropsychiatry & Russian National Research Medical University, Moscow, Russia

^f Center for Immunology and Inflammatory Diseases, Massachusetts General Hospital/Harvard University, Boston, MA, USA

^g Department of Critical Care Medicine, Neurology, and Neurosurgery, University of Pittsburgh School of Medicine, Pittsburgh, PA, USA

^h Divisions of Neuroimmunology and Neuroinfectious Disorders & Advanced Clinical Neurology, Johns Hopkins University School of Medicine, Baltimore, MD, USA

ⁱ Rajendra Institute of Medical Sciences, Ranchi 834009, Jharkhand, India

^j Department of Neurology, Division of Neurocritical Care, Medical University Innsbruck, Innsbruck, Austria

^k Headache Unit, Department of Neurology, Hospital Clínico Universitario de Valladolid, Valladolid, Spain

^l Center for Global Health, Department of Neurology, Technical University of Munich, Munich, Germany

^m Centre for Global Health, Institute of Health and Society, University of Oslo, Oslo, Norway

ARTICLE INFO

Keywords:

Cerebral venous thrombosis
COVID-19
Vaccination

ABSTRACT

Background: Vaccine induced immune mediated thrombocytopenia or VITT, is a recent and rare phenomenon of thrombosis with thrombocytopenia, frequently including cerebral venous thromboses (CVT), that has been described following vaccination with adenovirus vaccines ChAdOx1 nCoV-19 (AstraZeneca) and Ad26.COV2-S Johnson and Johnson (Janssen/J&J). The evaluation and management of suspected cases of CVT post COVID-19 vaccination are critical skills for a broad range of healthcare providers.

Methods: A collaborative comprehensive review of literature was conducted among a global group of expert neurologists and hematologists.

Findings: Strategies for rapid evaluation and treatment of the CVT in the context of possible VITT exist, including inflammatory marker measurements, PF4 assays, and non-heparin anticoagulation.

1. Introduction

Recent rare reports of thrombosis with thrombocytopenia, including cerebral venous thromboses (CVT) (also known as cerebral venous sinus thromboses (CVST)), have been described following immunization with adenovirus-vector COVID-19 vaccines ChAdOx1 nCoV-19 (AstraZeneca) and Ad26.COV2-S Johnson and Johnson (Janssen/J&J) [1,2]. These reports may have global effects on vaccine implementation and

present new challenges to vaccine surveillance and safety monitoring worldwide. Adenoviral vaccines have become the preferred vaccine for middle and low income countries as they do not require ultra-cold chain storage requirements and for Ad26.COV2-S specifically, its single dosing schedule [3]. Thus, these vaccines have become the cornerstone for COVID-19 Vaccines Global Access (COVAX), a global initiative to provide equitable access to vaccines, with 500 million doses of Ad26.COV2-S and 170 million doses of ChAdOx1 nCoV-19 booked by the

* Corresponding author at: Division of Critical Care and Hospitalist Neurology, Department of Neurology, Columbia University Irving Medical Center, 177 Fort Washington Avenue, New York, NY, USA.

E-mail address: ktt2115@cumc.columbia.edu (K.T. Thakur).

<https://doi.org/10.1016/j.jns.2021.117532>

Received 1 June 2021; Accepted 3 June 2021

Available online 5 June 2021

0022-510X/© 2021 The Authors.

Published by Elsevier B.V. This is an open access article under the CC BY-NC-ND license

(<http://creativecommons.org/licenses/by-nc-nd/4.0/>).

program [4,5].

Importantly, new onset headache, one of the non-specific but cardinal features of CVT, is seen in up to 67% of individuals during the initial few days after any COVID-19 vaccination [6,7]. Therefore, whilst over-investigation of all patients with a post-vaccination headache is unnecessary and not feasible, both delayed diagnosis and treatment of CVT risk significant individual morbidity and mortality. Correct and timely diagnosis of CVT in post-COVID-19 vaccinated patients, as well as the evaluation and management approach in suspected cases of vaccine-induced immune-mediated thrombocytopenia with thromboses (VITT), are critical skills for a broad range of healthcare providers. Here, we review CVT in the context of possible VITT, provide practical guidance on clinical approaches and explore unanswered mechanistic and management questions regarding the possible relationship between the adenovirus vector COVID-19 vaccinations and VITT.

Overall, CVT is a rare form of stroke (0.5% to 1% of all strokes prior to the COVID-19 pandemic) that occurs when the cerebral venous sinus system or the smaller draining veins are completely or partially occluded [8]. Occlusion of a venous structure causes physiologic backflow in venous drainage, leading to localized brain edema, seizures, and in some cases, brain infarction and/or intracerebral hemorrhage (ICH) [8,9]. CVT can also result in venous hypertension, decreased CSF absorption and consequently, increased intracranial pressure (ICP) [10]. In contrast to arterial strokes, venous strokes are more common in young adults, with a median age of 39 years (range 16–85) and are three times more common in women than men [11]. Predisposing causes of CVT are multiple, including both genetic and non-genetic risk factors [12,13] (Table 1). With regards to the risk of CVT in the context of SARS-CoV-2 infection, a recent report found an incidence of 8.8 per 10,000, with a male predominance and average age of 49 years (95% CI, 36–62 years) [14]. In a review of electronic health record system data from 59 US health centers, the incidence of CVT after COVID-19 was 42.8 per million, which was significantly higher than the incidence in matched patients with influenza and or after SARS-CoV-2 mRNA vaccination, with a relative risk of 3.81 95% CI 1.56–9.41, $P < 0.001$) and 6.67 95% CI 1.98–22.43, $P < 0.001$, respectively [15]. Analysis of the TriNetX global health collaborative clinical research platform including 667,551 COVID-19 patients and 65,796,480 non-COVID-19 patients found the odds of developing CVT were 41 times higher in COVID-19 patients than among non-COVID-19 patients [16]. [Thus, evidence supports SARS-CoV2 infection itself as a significant increased risk of CVT, and thus regional recommendations have emphasized that individuals at risk of

COVID-19 overall benefit from COVID-19 vaccination.

2. Cerebral Venous Thrombosis in the context of SARS-CoV-2 vaccination (Table 2)

As of May 25th 2021, almost 1.5 billion SARS-COV-2 vaccine doses have been administered worldwide, with over 10.3 million doses of Ad26.COVS vaccine given in the US and more than 34 million doses of ChAdOx1 nCOV-19 given in the UK [17–19]. Close monitoring for possible vaccine adverse events following immunization has occurred both during clinical trials, and via public health surveillance systems in the post-marketing period. Reports of thrombotic events to public health surveillance programs prompted recent investigation. After review by the European Medicine Agency (EMA) safety committee on events in the context of ChAdOx1 nCOV-19 vaccine, the EMA concluded that the vaccine may be associated with very rare cases of blood clots associated with thrombocytopenia, though the report emphasized the overall significant benefit of COVID-19 vaccination [20]. On the 4th of April 2021, 169 cases of CVT and 53 cases of splanchnic vein thrombosis post-vaccination were captured by EMA [20]. The number of cases was 4.94 (95% CI: 2.63–8.45) times higher than expected with a case fatality rate (CFR) of 22.6%. Thrombocytopenia was reported in 53.2% of cases though there is a lack of confirmation of platelet values, as well as other risk factors for CVT, in many of the reported cases [21]. On April 22nd, the United Kingdom's Medicines and Healthcare products Regulatory Agency (MHRA) reported 171 major blood clots, with CVT in 77 cases (some overlapping with the cases captured by the EMA), a rate of 7.9 patients per million doses administered [22]. Up to May 12th, overall 309 cases of VITT were reported, of whom 116 had a cerebral venous sinus thrombosis, an overall rate of VITT of 12.3 per million doses and with case fatality rate of 18% [22]. The majority were women under 60 years old, but given differing vaccine distribution across populations, ultimate conclusions regarding age predisposition have not yet been determined [20,22]. The British Society of Hematology has noted that there is no current evidence that individuals with known thrombotic risk factors are at higher risk of developing immune complications related to the ChAdOx1 nCOV-19 vaccine [23].

On April 13th, 50 days after Emergency Use Authorization (EUA) approval for Ad26.COVS vaccine use, the United States (US) Centers for Disease Control and Prevention (CDC) and Federal Drug Administration (FDA) recommended a pause in the use of Ad26.COVS vaccine, in the context of 6 reports of CVT of more than 6.8 million doses administered [24,25]. [24,25]. As of May 7th, the CDC reported 19 or 28 TTS cases with CVT after Ad26.COVS vaccine. Among the 28 cases of TTS, median age was 40 years (range 18–59 years), 22 (79%) were in women. [26] On April 21st, six additional cases of CVT with thrombocytopenia were reported. The 12 cases occurred in women between the ages of 18 and 60 years, with 11 women younger than 50 years old. The cases closely resembled those described after ChAdOx1 nCOV-19 vaccination. Median time from vaccination to symptom onset was 9 days (range 3–15 days), with all received the vaccine prior to the pause. Some cases had concomitant risk factors, including two patients taking combined oral contraceptives, one patient on hormone therapy estradiol patch, one on fertility treatment, 12 obese, three with diabetes, one current malignancy, two with active cigarette smoking use, though none were pregnant or in the post-partum period. All cases were negative for SARS-CoV-2 by nasopharyngeal polymerase chain reaction (PCR) or antigen testing; five individuals had evidence of past SARS-CoV-2 infection, three by history, two by nucleocapsid serology testing only. In the original report of 12 cases, the most common presenting symptom was headache while others had had hemiparesis, aphasia, loss of consciousness, and neglect. Eight patients had other thromboses, including two cases of portal vein thrombosis, six with internal jugular vein thrombosis, and three pulmonary emboli [27]. Several of the cerebral sinuses were affected. Reports describe 10 (53%) of individuals with CVT with evidence of intracerebral hemorrhage, and descriptions of

Table 1

Traditional risk factors associated with CVT.

Traditional Risk factors for CVT [61]
Genetic/acquired thrombophilia
Genetic/acquired thrombophilia (total)
Factor V Leiden thrombophilia
Prothrombin Gly20210A1a mutation
Antithrombin deficiency
Protein S deficiency
Protein C deficiency
Systemic conditions
Malignancy/myeloproliferative disorders
Neuroinflammatory conditions (ie Sarcoidosis, Behcet, SLE)
Antiphospholipid syndrome
Thyroid disease
Obesity
Gender & Sex-specific risk factors
Oral contraceptives
Pregnancy and puerperium
Hormone replacement therapy
Miscellaneous
Dural arteriovenous fistula
Head or neck infections
Anemia
Head trauma

Table 2

Current published reports of cerebral venous thromboses in association with vaccine-induced thrombosis-thrombocytopenia.

Author	Region	Vaccine	Total number of cases	Median Age and Age range	F:M	Time from vaccination to onset (days)	Number of confirmed CVT cases	Comments
Primary Peer-Reviewed Articles								
Greiner et al. 2021 [29]	Germany	ChAdOx1	11	26 (22–49)	9:2	6–16 days	9*	*One additional patient died of intracranial hemorrhage – CVT suspected but not confirmed.
Wolf et al. [72]	Germany	ChAdOx1	3	22, 36, 46	3:0	7–17 days	3	–
Tiede et al. [79]	Germany	ChAdOx1	5	61 (41–67)	5:0	5–11	1	–
Schulz et al. [31]	Norway	ChAdOx1	5	39 (32–54)	4:1	7–10 days	4	–
Scully et al. [32]	United Kingdom	ChAdOx1	23*	46 (21–77)	14:9	6–24 days	13	*One patient did present with thrombocytopenia and bruising but no thrombosis.
Mehta et al. [73]	United Kingdom	ChAdOx1	2	25, 32	0:2	6 days, 9 days	2	One case also included in Scully et al.
Castelli et al. 2021 [74]	Italy	ChAdOx1	1	50	0:1	9 days	1	Both reports relate to the same patient.
Franchini et al. [75]								
D'Agostino et al. [76]	Italy	ChAdOx1	1	54	1:0	12 days	1	–
Jamme et al. [80]	France	ChAdOx1	1	69	1:0	11 days	1	–
See et al. [27]	US	Janssen	12	18–60	12:0	6–15 days	12	Includes case by Muir et al.
Muir et al. [77]	United States	Ad26. COV2-S	1	48	1:0	14 days	1	Included in See et al.
Sadoff et al. [78]	United States	Ad26. COV2-S	1	25	0:1	19 days	1	Phase III trial of Janssen vaccine
Public Health and Regulatory Reports (Cases may overlap with those reported in peer-reviewed articles)								
MHRA [22]	United Kingdom	AZ	309	18–93	169:138	Not reported	116	Include the UK reports
CDC [24]	United States	Janssen	6	18–48	6: 0	6–13 days	6	Includes report by Muir et al.

Abbreviations: AZ = Oxford/AstraZeneca vaccine (ChAdOx1 nCoV-19). CDC = Centers for Disease Control and Prevention. MHRA = Medicines and Healthcare products Regulatory Agency.

cerebral arterial involvement as well. All patients with TTS had thrombocytopenia with platelet nadir levels less than 50,000 in 18 (64%) of individuals, and 24 (86%) positive for platelet factor four (PF4) antibodies [27]. Non-heparin anticoagulants were given in 26 (93%) of individuals with VITT, while heparin was given in 12 (43%), and IVIG in 18 (64%). Three individuals have been reported to die per the latest CDC report. [26] One case in the Ad26.COV2-S phase III clinical trial was reported in a 25 year old male with no significant medical history, who developed fever and headache 9 days after vaccination, had seizure and cerebral hemorrhage on day 19, and was diagnosed with CVT and anti-PF4 positivity on day 21 [28].

CVT events in the context of ChAdOx1 nCoV-19 and Ad26.COV2-S vaccinations have been noted to resemble autoimmune heparin-induced thrombocytopenia (aHIT), as many individuals have been positive for PF4 antibodies [29–32]. PF4 antibodies bridge PF4 tetramers using endogenous non-heparin polyanions; subsequently the antibody portion of the PF4–aHIT-IgG complexes bind Fc gamma receptor of platelets, crosslinking them and triggering platelet activation [29]. Similar to HIT, platelet consumption leads to thrombocytopenia and the continued platelet and monocyte activation increases thrombin generation, resulting in thrombosis. Why adenoviral vector vaccines in particular, which are non-enveloped double stranded DNA vectors may be associated with PF4 antibody production is poorly understood (Table 3). Of note, for Gam-COVID-Vac (Sputnik), another recombinant adenovirus vaccine, clotting events have not been reported to date [33]. One possible mechanism, is that the biodistribution of adenoviral vaccines to the brain, which was seen in animal studies with ChAdOx1 nCoV-19, may trigger spike protein production in the brain and a subsequent autoimmune response with thrombosis [34]. Of note, an observational

Table 3

Some key questions on the assessment and management of confirmed cases.

- Is CVT associated with vaccine-induced immune mediated thrombocytopenia?
- What is the pathophysiological mechanisms of CVT and VITT?
- Are COVID-19 vaccines associated causally with CVT risk?
- Which vaccines are associated with the development of VITT and CVT?
- What is the mechanism for VITT in the context of adenovirus vaccines?
- What is the incidence of VITT?
- What is the incidence of CVT post COVID-19 vaccinations?
- What is the significance for positive PF4 antibodies in these cases?
- What are patient risk factors for the development of VITT and CVT?
- Why does the syndrome appear to cause CVT and abdominal thromboses out of proportion to its effect on limb and pulmonary thrombosis, which are more often involved in other forms of spontaneous venous thrombosis?
- Is VITT a transitory thrombotic event or the unmasking or a long term or chronic prothrombotic condition?
- Can CVT occur in the absence of possible vaccine induced immune thrombocytopenia?
- What is the most effective first line treatment?
- When should thrombectomy be considered in the context of CVT?
- What is the optimal neurosurgical management of CVT cases in the context of possible VIT?
- How should we manage severe cases unresponsive to first line treatments?
- What proportion of patients experience recurrent thrombosis and how to stratify those at the highest risk of recurrence?
- How long should we monitor the patients following discharge and are platelets a sufficient marker of disease activity?
- How long should we continue oral anticoagulation?
- How long should we continue the immunosuppressive treatments for?

study of 492 healthcare workers recently vaccinated with ChAdOx1 nCoV-19 found only 6 cases of anti-PF4 antibodies with all normal platelet counts, highlighting the low prevalence of HIT antibodies after vaccination [35]. Beyond positive PF4 antibodies and thrombocytopenia, laboratory features often include raised D-dimer and disseminated intravascular coagulation (DIC)-like coagulopathy with tendency to hemorrhage [29,30,32].

The uniqueness of the phenotype, the consistent temporal association with the vaccine, and the incidence exceeding expected baseline rates, led EMA and the UK MHRA to determine a possible causal link [20,22]. However, the risks versus benefits of vaccination remain favorable for the majority, particularly in older populations, who appear to be at both higher risks of morbidity and mortality from SARS-CoV2 infection and lower risks of thrombotic events following these vaccines; in particular the benefits appear to outweigh the risks in the context of high infection rates [36] [9,10]. In line with this, multiple countries have modified their vaccination programs. As examples, ChAdOx1 nCoV-19 vaccine became restricted to those aged >40 years in the UK, >55 years in Canada (with some provinces, however, now lowering the bracket to >40), and > 60 years in Germany [37], [38,39]. A randomized controlled clinical of the vaccine in a pediatric population has also been halted [40]. On April 27th, the Advisory Committee on Immunization Practices in the US decided to resume use of Ad26.COV2-S vaccine in all patients over 18, emphasizing the potential impact of restricted use on public health implementation, especially among populations with barriers to vaccines that require a two-dose schedule [41]. The CDC did include a warning for adult women younger than 50, advising this group be made aware of the increased risk of thrombosis and be counseled on other vaccine options that have not shown this risk [42].

A population cohort study of 281,264 Danish and Norwegian individuals aged 18 to 65 who received ChAdOx1 vaccine confirmed a higher-than-expected rate of CVT, with an excess of 2.5 events for every 100,000 vaccines given. The observed rate of venous thromboembolic events also exceeded the expected, particularly in women and in those aged 18–45. However, the overall number of deaths in the studied population was lower than anticipated, which may be due to the 'healthy-worker' effect [43].

3. Clinical presentation

Lack of recognition and index of suspicion commonly results in missed and delayed diagnosis of CVT, in the pre-COVID era. Symptoms reflect the location of the specific sinus or vein affected and frequently, multiple locations may be affected simultaneously. Headache is the most common manifestation of CVT. In the International Study of Cerebral Vein and Dural Sinus Thrombosis, headache was present in 89% of patients [11]. There is no classic pattern of headache associated with CVT; the headache may be generalized or focal, and often progresses over days to weeks [44]. It can fluctuate and severity may vary from mild to unbearable and is most commonly due to increased ICP or hemorrhage. Headache may be accompanied by papilledema and unilateral or bilateral sixth nerve palsies and may be exacerbated by recumbency or Valsalva maneuvers, such as coughing [44]. Isolated headache, without evidence of increased ICP, was present in 17 (14%) of 123 consecutive patients with CVT in one series, demonstrating the need for a high index of suspicion for CVT in patients presenting with headache, particularly if new or otherwise unexplained, and in the appropriate risk factor profile [45,46]. Approximately 1/3 of patients may have isolated intracranial hypertension without focal signs or symptoms [47].

Focal neurological presentations include hemiparesis or aphasia, and seizures, which may be focal or generalized [11]. CVT often presents with bilateral deficits, particularly when the superior sagittal sinus, the most commonly involved venous sinus (62%), is thrombosed [45,48]. This characteristic may help distinguish the focal deficits of CVT from those of more commonly encountered arterial ischemic infarcts and

primary intracerebral hemorrhages. The signs and symptoms of CVT are often progressive over days, whereas the deficit in arterial occlusions tends to be maximal at onset. In one international study, symptom onset was <48 h in about 1/3 of patients, 48 h to 30 days in 56% of patients, and more than 30 days in 7% of patients [45]. Seizures also occur more commonly with CVT (~40%) than with other stroke subtypes [45]. Confusion, stupor, or even coma, may occur in some patients with thrombosis of the internal cerebral veins that drain the thalami and basal ganglia [48]. This presentation may be missed, especially as CT scans may be unrevealing. Finally, other less common syndromes may occur. Thrombosis of the cavernous sinus may lead to proptosis, chemosis, orbital edema, diplopia, ophthalmoplegia, and facial sensory abnormalities due to congestion of the orbit and multiple cranial nerve palsies affecting nerves III, IV, V (ophthalmic and maxillary branches), and VI [49]. Headache, frequently retro-orbital, is also present in most cases. Isolated subarachnoid hemorrhage may also occur, although this is rare (0.8% of patients) [11].

4. Clinical investigation

An initial evaluation protocol for possible thrombosis with immune thrombocytopenia is provided based on available evidence to date. Clinicians should also consult their local clinical and public health agency guidance, as well as those available from national and international associations [50] (Fig. 2). Neuroimaging is required for definitive diagnosis of CVT and should be considered early in a young patient with new unusual headaches, or symptoms according to clinical presentation delineated above with thrombocytopenia 4–28 days after adenovirus SARS-CoV-2 vaccination. In addition to rapidly assessing for thrombocytopenia, additional laboratory testing should include evaluation for coagulopathy labs including d-dimer and testing for COVID-19. Although a non-contrast head CT is normal in up to 30% cases [51,52], it remains a critical initial test that can detect indirect signs of venous thrombus, such as localized or diffuse cerebral edema, infarcts that do not respect arterial territories, and/or hemorrhage. Direct signs of venous thrombus, such as hyperdense sagittal sinus (dense triangle sign) or transverse sinus (cord sign), are subtle and less frequent, and regress after the first 7 to 14 days [53]. CT venograms obtained after administration of IV contrast are the optimal diagnostic tool in the identification of venous filling defects (empty delta sign) and thrombosis of large venous sinuses, particularly in areas or centers without access to MR technology, although defects may only be seen in a third of cases [52]. Brain MRI is more sensitive in the detection of direct and indirect signs of CVT [48,54], in particular when combined with Magnetic Resonance Venogram (MRV) [55,56] (Fig. 1). Though, MRV may also be falsely positive due to flow voids. The appearance of the clot on MRI depends on its age. During the first week, the clot appears isointense on T1-weighted images and hypointense on T2-weight images and Fluid-attenuated inversion recovery (FLAIR), mimicking the normal venous flow signal and can thus appear falsely reassuring. A T2-weighted gradient echo (GRE), or Magnetic Resonance Venogram (MRV) improves diagnostic accuracy in this period, as the intraluminal thrombus appears hypointense [48,55,57]. A contrast-enhanced MRV is more sensitive than time-of-flight MRV, as low-flow areas and hypoplastic sinus can be problematic in the latter [58]. In the second week, the clot appears hyperintense on all sequences. In the chronic phase, the clot signal can be variable, but is typically isointense on T1 weighted imaging, iso-/hyperintense on T2-weighted imaging, and hypointense on T2-gradient echo sequences. In addition to directly identifying the venous clot, indirect signs such as cerebral edema, infarct, and/or hemorrhage can further support the diagnosis, for which diffusion-weighted imaging (DWI) and perfusion-weighted MRI are useful [48]. Conventional angiography is no longer typically required, but may be performed if non-invasive imaging is inconclusive, or if rare isolated cortical venous thrombosis is suspected.

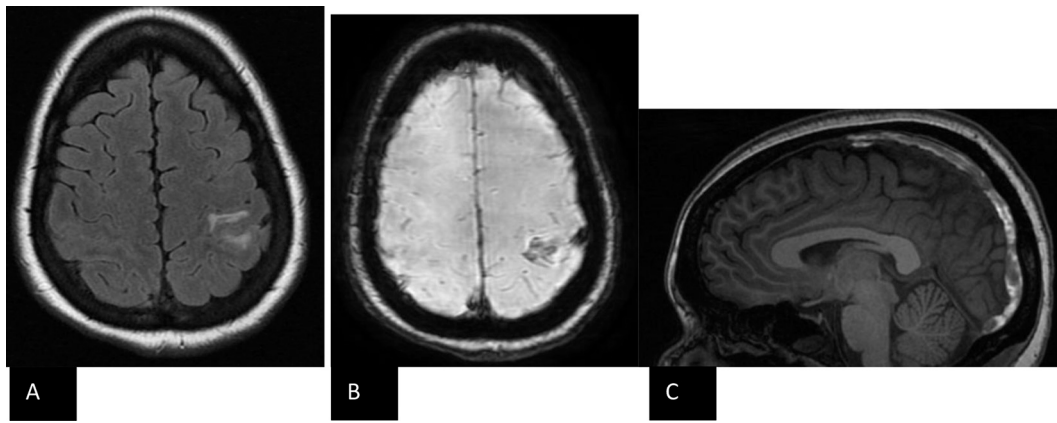


Fig. 1. Neuroimaging in a cerebral venous thrombosis (CVT) case.

A Axial T2/fluid attenuated inversion recovery sequence (FLAIR) magnetic resonance imaging (MRI) showing left anterior parietal hyperintensity.

B Susceptibility weighted imaging (SWI) axial view MRI showing area of low susceptibility signal at left anterior parietal lobe.

C Sagittal T1 post-gadolinium MRI showing early subacute sinus thrombosis involving the superior sagittal sinus and left transverse sinus.

5. Management strategies of possible CVT in the context of VITT

Emerging complexities of CVT with possible VITT prompt multidisciplinary management strategies, including involvement of neurology, hematology, neurosurgery, intensivists and neuro-endovascular teams (Fig. 2) [59,60]. Given that patients may deteriorate rapidly, early communication and transfer to medical centers which incorporate these specialized services is paramount. Management of complications including seizures and elevated intracranial pressure (ICP) is essential to reduce morbidity and mortality risk.

The management strategies are subject to ongoing updates as the knowledge of cases advances rapidly. Many questions regarding CVT in the context of possible VITT remain unanswered (Table 3). Despite our current knowledge gaps, several strategies including immunosuppression, blood product transfusion, non-heparin anticoagulation and neuroradiological and neurosurgical interventions (where indicated), form the foundations of management and differ significantly from the treatment of standard CVT (Fig. 2) [60–62]. Currently, the CDC advises to maintain a high suspicion for symptoms that may indicate an underlying thrombotic event, such as headache, abdominal pain, petechiae, new or easy bruising, shortness of breath, new neurologic symptoms, and leg swelling [28]. In these cases, platelet counts and screening for ITP is advised. In the context of thrombocytopenia, the CDC and British Society for Hematology recommend a PF4 ELISA assay in tandem with consultation with a hematologist. Heparin use is discouraged, unless HIT testing is negative, and provisional guidelines, including guidance from the International Society on Thrombosis and Hemostasis (ISTH), recommend considering non-heparin anticoagulants and high-dose intravenous immunoglobulin (IVIG) [63,64]. The British guidelines additionally recommend abdominal ultrasound for portal or splanchnic vein thromboses [60].

Because of resemblance to aHIT, immunosuppression is the mainstay of treatment and should be given urgently [29,60]. The current recommendations advocate for use of intravenous immunoglobulin (IVIG) as the first line management. Though there is concern for thrombotic risk with IVIG, recent evidence from a meta-analysis and systematic review using adverse event data in randomized controlled trials using IVIG showed a lack of overall increased thromboembolic events with IVIG use [65]. The rationale for IVIG is the rapid inhibition of HIT antibodies and reduction of platelet activation by blocking the platelet Fc receptor. IVIG for HIT is not included in the American Society of Hematology 2018 guidelines, though there have been reports of its successful use, necessitating further investigation [66]. In the context of early VITT, IVIG use may prevent development of thrombosis [67]. Therapeutic plasma exchange can also help in progressive cases or as an

alternative or adjunct to IVIG in severe presentations [60]. Of importance, a recent population-based analysis evaluating the use of IVIG or therapeutic plasma exchange (TPE) in HIT, treatment with TPE or IVIG was associated with increased likelihood of inpatient mortality and major bleeding. Thus, clinicians should work closely with local experts to optimize management strategies [68]. Intravenous and oral corticosteroids have been recommended to bridge the gap if the access to IVIG is delayed, although it is unclear whether there is benefit from adjunctive steroids with IVIG. In regions where there is no access to IVIG or plasma exchange, steroid use should be strongly considered. Further studies are required to evaluate the efficacy of steroid monotherapy, particularly in resource-limited settings.

In some cases, there is DIC, with significantly raised D-dimer and low fibrinogen [29,60]. ISTH guidelines indicated markedly elevated D-dimer levels of greater than 4 times the value for venous thromboembolism exclusion are highly suggestive of VITT and should be treated as such [64]. Serial measurements of liver function tests (LFTs) and coagulation studies should be assessed in all patients with CVT. Fibrinogen levels should be maintained above 1.5 g/L using cryoprecipitate or fibrinogen concentrate [60]. The role of platelet transfusions is more uncertain and should be avoided in the absence of bleeding or need for surgical or other interventional procedures. While platelet transfusions are avoided, rapid progression of some cases with rising ICP may necessitate transfusion to enable neurosurgical intervention [60].

In the absence of clinical trial data, decisions on timing of anticoagulation are complex and best made by a multidisciplinary team, as cases may feature progression of thrombosis with concurrent intracranial bleeding [29,31,32]. For this reason, one should consider introducing anticoagulation as soon as safe to do so, and in cases where the bleeding risks are higher, lower anticoagulation doses should still be considered [60]. Heparin-based anticoagulation should be avoided, though there is a lack of consistent data on outcomes in the context of heparin use in VITT cases [29,32,60]. Alternatives include direct thrombin inhibitors (e.g. argatroban and bivalirudin, if the baseline aPTT is normal), direct oral Xa inhibitors (e.g. apixaban, rivaroxaban) and indirect Xa inhibitors (fondaparinux) [29,32]. Factor Xa level monitoring should be considered. Patients unsuitable for or progressing despite anticoagulation should be considered for direct endovascular treatment approaches [31,69,70]. In severe cases, early discussions should be held with neurosurgical teams, as progression of brain edema and/or hemorrhage may be rapid [31,71]. Recommendations will evolve as epidemiological and clinical understanding of VITT expands. Clinicians should seek advice from local and national public health agencies given this rapidly evolving topic.

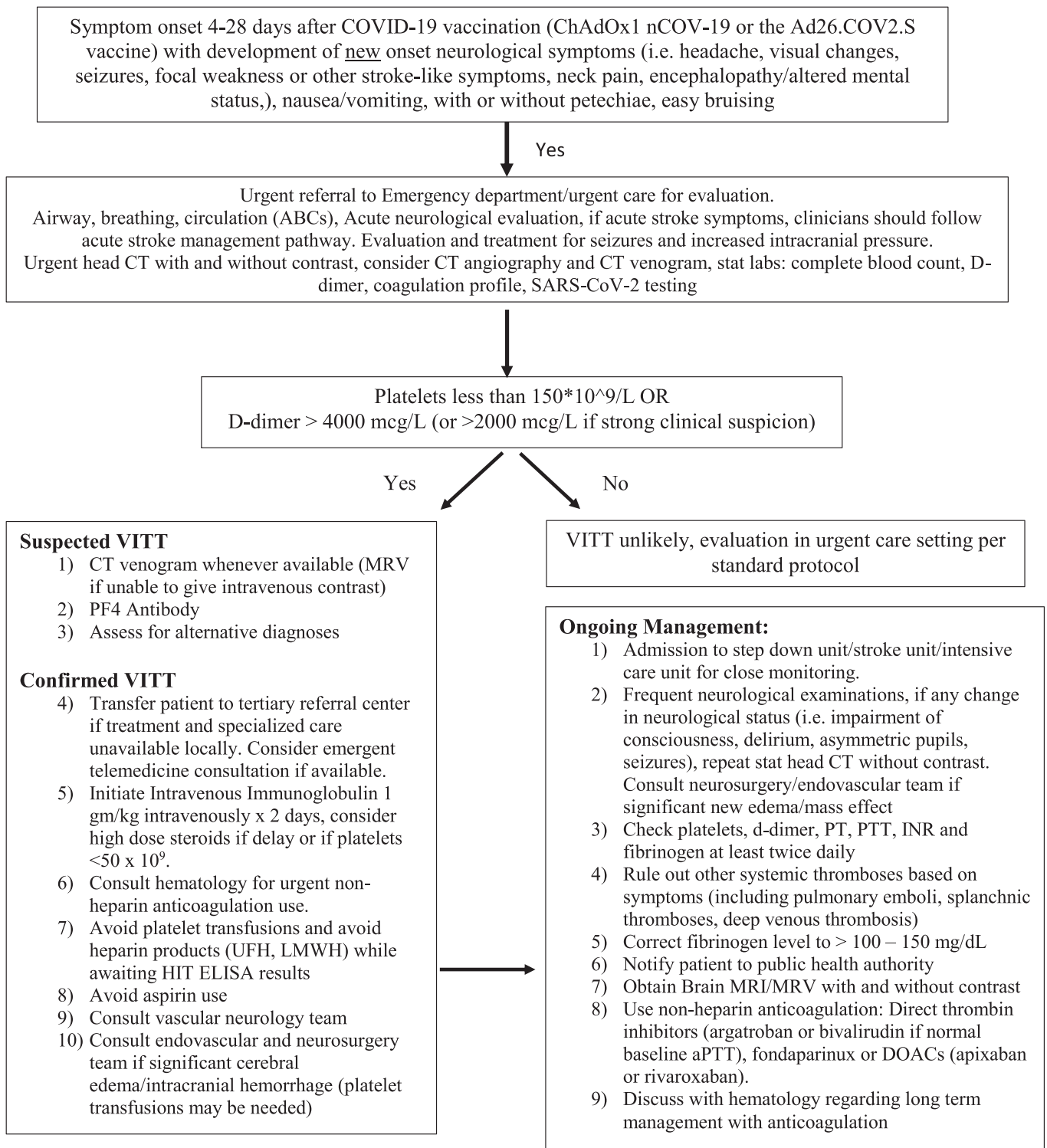


Fig. 2. Evaluation and management algorithm for cerebral venous thromboses in the context of possible vaccine induced thrombocytopenia.

6. Scientific questions and future directions

There are certainly many unanswered questions regarding CVT following SARS-CoV2 vaccination, particularly in association with VITT (Table 3). Further research is required to define the incidence of VITT, potential contributing factors, any early risk factors and management for this rare condition. Identification of the specific component of the adenoviral vaccines that may trigger this syndrome is vital. One key unsolved question is why this syndrome appears to cause CVT and

abdominal thromboses out of proportion to its effect on limb and pulmonary thrombosis, which are more often involved in other forms of spontaneous venous thrombosis.

7. Conclusion

Ongoing close monitoring and reporting of conditions by frontline clinicians is imperative to local and national public health agencies. Strategies for rapid treatment of CVT and VITT-CVT are outlined here,

though information is evolving, and improved understanding of the pathophysiology will further inform future guidance. Working groups in several professional societies and public health agencies, including the World Health Organization, have gathered experts to provide further guidance rapidly. A particular challenge will be around assessment, monitoring, and management for CVT in resource-limited settings, where specialized clinical services, laboratory and imaging capacity, as well as treatments, are very much limited. Beyond diagnosis and management, public health specialists and implementation scientists should explore ways to enhance public and professional education to reduce the impact of CVT on the individual's health and vaccination efforts. It is important to recognize that the risk of CVT from COVID-19 greatly outweighs the risk from COVID-19 vaccines which are overall safe, very effective, and critical to ending the acute phase of this global pandemic.

Author contributions

All authors assisted with writing, editing, and reviewing of the manuscript.

Declaration of Competing Interest

KTT is a member of the World Health Organization (WHO) working group on clinical guidance of VITT in the context of COVID-19 vaccinations, reports funding from the National Institute of Health (NIH) and Center for Disease Control and Prevention (CDC) on neurological conditions in the context of COVID-19 and COVID-19 vaccinations. AT receives funding from the National Institute for Health Research (NIHR) Academic Clinical Fellowship. DR reports funding from the National Blood Foundation, NIH, National Institute of Allergies and Infectious Disease (NIAID), Department of Defense (DOD), and Apellis Pharmaceuticals. ECM reports funding from the NIH, National Institute of Neurological Disorders and Stroke (NINDS), National Institute on Aging (NIA), and the Louis V. Gerstner, Jr. Foundation (Gerstner Scholars Program). JC reports funding from the NINDS and the McDonnell Foundation. AG reports funding from the Russian Scientific Foundation. CAP reports funding from the NIH and Bart McLean Fund for Neuroimmunology Research. DGA reports funding from the Spanish Society of Neurology, Fundación Estudios de Ciencias de la Salud de Castilla y León, Colegio de Médicos de Valladolid, the International Headache Society and the WHO. BDM reports funding from the United Kingdom Research Institute / Medical Research Council (UKRI/MRC) and Wellcome. SHYC reports funding from the NIH, NINDS, National Center for Advancing Translational Sciences (NCATS), and the University of Pittsburgh School of Medicine Dean's Faculty Advancement Award. ASW reports funding from the German Federal Ministry of Education and Research and the European Union (EU). TS was Chair/Co-Chair of the United Kingdom Research and Innovation / National Institute for Health Research COVID-19 Rapid Response and Rolling Funding Initiatives (which funded the development of COVID-19 vaccines), is an Advisor to the UK COVID-19 Therapeutics Advisory Panel and a member of the UK Medicines and Healthcare Products Regulatory Agency COVID-19 Vaccines Benefit Risk Expert Working Group. TS is supported by the National Institute for Health Research (NIHR) Health Protection Research Unit in Emerging and Zoonotic Infections, NIHR Programme Grant for Applied Research, NIHR Global Health Research Group on Brain Infections, the UK Medical Research Council's Global Effort on COVID-19 Programme, and the European Union's Horizon 2020 research and innovation program ZikaPLAN (Preparedness Latin America Network). MSE reports royalties for a chapter on COVID-19 and neurological disease in UpToDate. All other authors declare no competing interests.

Acknowledgements

There is no funding to declare in the creation of this article.

References

- [1] J. Wise, Covid-19: European countries suspend use of Oxford-AstraZeneca vaccine after reports of blood clots, *BMJ*. 372 (2021) n699.
- [2] European Medicines Agency, COVID-19 Vaccine Janssen: EMA Finds Possible Link to Very Rare Cases of Unusual Blood Clots with Low Blood Platelets, Available from: <https://www.ema.europa.eu/en/news/covid-19-vaccine-janssen-ema-finds-possible-link-very-rare-cases-unusual-blood-clots-low-blood>, 2021.
- [3] Organisation WH, WHO LISTS TWO ADDITIONAL COVID-19 Vaccines for Emergency Use and COVAX Roll-out, Available from: <https://www.who.int/news/item/15-02-2021-who-lists-two-additional-covid-19-vaccines-for-emergency-use-and-covax-roll-out>, 2021.
- [4] Organisation WH, WHO Adds Janssen Vaccine to List of Safe and Effective Emergency Tools against COVID-19, Available from: <https://www.who.int/news/item/12-03-2021-who-adds-janssen-vaccine-to-list-of-safe-and-effective-emergency-tools-against-covid-19>, 2021.
- [5] S. Mallapaty, Ewen Callaway, What scientists do and don't know about the Oxford–AstraZeneca COVID vaccine, *Nat. Rev. Neurol.* 592 (7852) (2021) 15–17.
- [6] J. Chapin-Bardales, J. Gee, T. Myers, Reactogenicity following receipt of mRNA-based COVID-19 vaccines, *Jama*. 325 (21) (2021) 2201–2202, <https://doi.org/10.1001/jama.2021.5374> (PMID: 33818592).
- [7] F.P. Polack, S.J. Thomas, N. Kitchin, J. Absalon, A. Gurtman, S. Lockhart, et al., Safety and efficacy of the BNT162b2 mRNA Covid-19 vaccine, *N. Engl. J. Med.* 383 (27) (2020) 2603–2615.
- [8] L. Ulivi, M. Squitieri, H. Cohen, P. Cowley, D.J. Werring, Cerebral venous thrombosis: a practical guide, *Pract. Neurol.* 20 (5) (2020) 356–367.
- [9] H. Li, L. Cui, Z. Chen, Y. Chen, Risk factors for early-onset seizures in patients with cerebral venous sinus thrombosis: a meta-analysis of observational studies, *Seizure*. 72 (2019) 33–39.
- [10] P. Canhão, J.M. Ferro, A.G. Lindgren, M.-G. Bousser, J. Stam, F. Barinagarrementeria, Causes and predictors of death in cerebral venous thrombosis, *Stroke*. 36 (8) (2005) 1720–1725.
- [11] J.M. Ferro, P. Canhão, J. Stam, M.-G. Bousser, F. Barinagarrementeria, Prognosis of cerebral vein and Dural sinus thrombosis, *Stroke*. 35 (3) (2004) 664–670.
- [12] M. Green, T. Styles, T. Russell, C. Sada, E. Jallow, J. Stewart, et al., Non-genetic and genetic risk factors for adult cerebral venous thrombosis, *Thromb. Res.* 169 (2018) 15–22.
- [13] E.F. van Vlijmen, S. Wiewel-Verschuere, T.B. Monster, K. Meijer, Combined oral contraceptives, thrombophilia and the risk of venous thromboembolism: a systematic review and meta-analysis, *J. Thromb. Haemost.* 14 (7) (2016) 1393–1403.
- [14] F. Al-Mufti, K. Amuluru, R. Sahni, K. Bekelis, R. Karimi, J. Ogulnick, et al., Cerebral venous thrombosis in COVID-19: a New York metropolitan cohort study, *AJNR Am. J. Neuroradiol.* (2021), <https://doi.org/10.3174/ajnr.A7134> (Epub ahead of print. PMID: 33888450).
- [15] M. Taquet, Husain Masud, Geddes John Luciano, Harrison Paul Sierra, COVID-19 and Cerebral Venous Thrombosis: A Retrospective Cohort Study of 513,284 Confirmed COVID-19 Cases, 2021.
- [16] A. Hinduja, Nallenalle Krishna, Oteddu Sanjeeva, Kovvuru Sukanthi, Hussein Omar, Impact of cerebral venous sinus thrombosis associated with COVID-19, *J. Neurol. Sci.* 425 (2021) 117448.
- [17] World Health Organisation, WHO Coronavirus (COVID-19) Dashboard, Available from: <https://covid19.who.int/>, 2021.
- [18] CDC, COVID Data Tracker Centers for Disease Control and Prevention, Available from: <https://covid.cdc.gov/covid-data-tracker>, 2021.
- [19] Update Following MHRA and EMA Decisions on AstraZeneca's COVID-19 Vaccine, Available from: <https://covid19.astrazeneca.com/home/latest-news/update-following-mhra-and-ema-decisions-on-astrazenecas-covid-19-vaccine.html>, 2021.
- [20] European Medicines Agency, AstraZeneca's COVID-19 Vaccine: EMA Finds Possible Link to Very Rare Cases of Unusual Blood Clots with Low Blood Platelets, Available from: <https://www.ema.europa.eu/en/news/astrazenecas-covid-19-vaccine-ema-finds-possible-link-very-rare-cases-unusual-blood-clots-low-blood>, 2021.
- [21] PRAC, Signal Assessment Report on Embolic and Thrombotic Events (SMQ) with COVID-19 Vaccine (ChAdOx1-S [recombinant]) – Vaxzevria (previously COVID-19 Vaccine AstraZeneca) (Other Viral Vaccines), 2021. Updated 08 April 2021.
- [22] Medicine & Healthcare products Regulatory Agency, Coronavirus Vaccine - Weekly Summary of Yellow Card reporting, United Kingdom, 2021.
- [23] British Society for Haematology, Letter to MHRA from The Expert Haematology Panel Endorsed by Thrombosis UK 09/04/2021 United Kingdom, Available from: <https://b-s-h.org.uk/media/19537/letter-to-mhra-from-expert-haematology-group-endorsed-by-thrombosis-uk-1300-8th-april-2021.pdf>, 2021.
- [24] Centers for Disease Control and Prevention, Johnson & Johnson/Janssen COVID-19 Vaccine and Cerebral Venous Sinus Thrombosis with Thrombocytopenia - Update for Clinicians on Early Detection and Treatment, Available from: https://emergency.cdc.gov/coca/ppt/2021/041521_slide.pdf, 2021.
- [25] E. Mahase, Covid-19: US suspends Johnson and Johnson vaccine rollout over blood clots, *BMJ*. 373 (2021) n970.
- [26] T. Shimbabukuro, Update: Thrombosis with Thrombocytopenia Syndrome (TTS) Following COVID-19 Vaccination, 2021.
- [27] See I. Su, John R. Lale, Allison, et al., US case reports of cerebral venous sinus thrombosis with thrombocytopenia After Ad26.COV2.S vaccination, March 2 to April 21, 2021, *JAMA*. (2021) e217517, <https://doi.org/10.1001/jama.2021.7517> (Epub ahead of print. PMID: 33929487; PMCID: PMC8087975).
- [28] CDC, Webinar April 15, 2021 - Johnson & Johnson/Janssen COVID-19 Vaccine and Cerebral Venous Sinus Thrombosis with Thrombocytopenia - Update for Clinicians

- on Early Detection and Treatment, Updated 2021-04-26. Available from: https://emergency.cdc.gov/coca/calls/2021/callinfo_041521.asp, 2021.
- [29] A. Greinacher, T. Thiele, T.E. Warkentin, K. Weisser, P.A. Kyrle, S. Eichinger, Thrombotic thrombocytopenia after ChAdOx1 nCoV-19 vaccination, *N. Engl. J. Med.* 384 (22) (2021) 2092–2101, <https://doi.org/10.1056/NEJMoa2104840> (Epub 2021 Apr 9. PMID: 33835769; PMCID: PMC8095372).
- [30] V. Muster, T. Gary, R.B. Raggam, A. Wölfler, M. Brodmann, Pulmonary embolism and thrombocytopenia following ChAdOx1 vaccination, *Lancet* 397 (10287) (2021) 1842, [https://doi.org/10.1016/S0140-6736\(21\)00871-0](https://doi.org/10.1016/S0140-6736(21)00871-0) (Epub 2021 Apr 14. PMID: 33864749).
- [31] N.H. Schultz, I.H. Sørvoll, A.E. Michelsen, L.A. Munthe, F. Lund-Johansen, M. T. Ahlen, et al., Thrombosis and thrombocytopenia after ChAdOx1 nCoV-19 vaccination, *N. Engl. J. Med.* 384 (22) (2021) 2124–2130, <https://doi.org/10.1056/NEJMoa2104882> (Epub 2021 Apr 9. PMID: 33835768; PMCID: PMC8112568).
- [32] M. Scully, D. Singh, R. Lown, A. Poles, T. Solomon, M. Levi, et al., Pathologic antibodies to platelet factor 4 after ChAdOx1 nCoV-19 vaccination, *N. Engl. J. Med.* (2021), <https://doi.org/10.1056/NEJMoa2105385> (Epub ahead of print. PMID: 33861525; PMCID: PMC8112532) (Apr 16;NEJMoa2105385).
- [33] H. Ledford, COVID vaccines and blood clots: five key questions, *Nat. Rev. Neurol.* 592 (7855) (2021).
- [34] H. Merchant, Might post-injection distribution of CoViD vaccines to the brain explain the rare fatal events of cerebral venous sinus thrombosis (CVST)? *BMJ (online)* (2021) 373.
- [35] I.H.H.K. Sorvoll, S.L. Ernsten, L.J. Laegreid, S. Lund, R.H. Grønli, M.K. Olsen, H. K. Jacobsen, A. Eriksson, A.M. Halstensen, E. Tjønnfjord, W. Ghanima, M.T. Ahlen, An observational study to identify the prevalence of thrombocytopenia and anti-PP4/polyanion antibodies in Norwegian health care workers after COVID-19 vaccination, *J. Thromb. Haemost.* (2021), <https://doi.org/10.1111/jth.15352> (Epub ahead of print. PMID: 33909350).
- [36] European Medicines Agency, AstraZeneca's COVID-19 Vaccine: Benefits and Risks in Context, Updated 23/04/21. Available from: <https://www.ema.europa.eu/en/news/astrazenecas-covid-19-vaccine-benefits-risks-context>, 2021.
- [37] Department of Health & Social Care, JCVI Statement on Use of the AstraZeneca COVID-19 Vaccine: 7 April 2021, United Kingdom, 2021.
- [38] National Advisory Committee on Immunization (NACI), NACI Rapid Response: Recommended Use of AstraZeneca COVID-19 Vaccine in Younger Adults Canada, Government of Canada, 2021. Available from: <https://www.canada.ca/en/p-public-health/services/immunization/national-advisory-committee-on-immunization-naci/rapid-response-recommended-use-astrazeneca-covid-19-vaccine-younger-adults.html>.
- [39] O. Dyer, Covid-19: EMA defends AstraZeneca vaccine as Germany and Canada halt rollouts, *BMJ* 373 (2021).
- [40] Trial C-OV, Children's Trial (COV006), Available from: <https://covid19vaccinetril.co.uk/childrens-trial-list>.
- [41] J.R. MacNeil, Updated recommendations from the advisory committee on immunization practices for use of the Janssen (Johnson & Johnson) COVID-19 vaccine after reports of thrombosis with thrombocytopenia syndrome among vaccine recipients — United States, April 2021, *MMWR Morb. Mortal. Wkly Rep.* 70 (2021).
- [42] CDC, COVID-19 Vaccination, 2021.
- [43] A. Pottgård, L.C. Lund, Ø. Karlstad, J. Dahl, M. Andersen, J. Hallas, et al., Arterial events, venous thromboembolism, thrombocytopenia, and bleeding after vaccination with Oxford-AstraZeneca ChAdOx1-S in Denmark and Norway: population based cohort study, *BMJ.* 373 (1114) (2021).
- [44] E. Agostoni, Headache in cerebral venous thrombosis, *Neurol. Sci.* 25 (Suppl. 3) (2004) S206–S210.
- [45] R. Cumurciuc, I. Crassard, M. Sarov, D. Valade, M.G. Bousser, Headache as the only neurological sign of cerebral venous thrombosis: a series of 17 cases, *J. Neurol. Neurosurg. Psychiatry* 76 (8) (2005) 1084–1087.
- [46] P.-M. Roy, E. Gras, Cerebral venous thrombosis, *New Engl. J. Med.* 349 (18) (2003) 1730.
- [47] V. Biousse, A. Ameri, M.-G. Bousser, Isolated intracranial hypertension as the only sign of cerebral venous thrombosis, *Neurology* 53 (7) (1999) 1537.
- [48] G. Saposnik, F. Barinagarrementeria, R.D. Brown, C.D. Bushnell, B. Cucchiara, M. Cushman, et al., Diagnosis and management of cerebral venous thrombosis, *Stroke.* 42 (4) (2011) 1158–1192.
- [49] R.E. Clifford-Jones, C.J. Ellis, J.M. Stevens, A. Turner, Cavernous sinus thrombosis, *J. Neurol. Neurosurg. Psychiatry* 45 (12) (1982) 1092–1097.
- [50] Association AHAAS, Leadership SC, Diagnosis and management of cerebral venous sinus thrombosis with vaccine-induced thrombotic thrombocytopenia, *Stroke.* (2021), <https://doi.org/10.1161/STROKEAHA.121.035564> (Epub ahead of print. PMID: 33914590).
- [51] M.G.R.R. Bousser, Cerebral venous thrombosis, in: Warlow CPVJG (Ed.), *Major Problems in Neurology*, WB Saunders, London, 1997, p. 27.
- [52] M. Wasay, M. Azeemuddin, Neuroimaging of cerebral venous thrombosis, *J. Neuroimaging* 15 (2) (2005) 118–128.
- [53] M.H. Rodallec, A. Krainik, A. Feydy, A. Hélias, J.M. Colombani, M.C. Jullès, et al., Cerebral venous thrombosis and multidetector CT angiography: tips and tricks, *Radiographics* 26 (Suppl. 1) (2006) S5–S18, discussion S42–3.
- [54] M.-G. Bousser, Cerebral venous thrombosis, *Stroke.* 30 (3) (1999) 481–483.
- [55] M.-G. Bousser, J.M. Ferro, Cerebral venous thrombosis: an update, *Lancet Neurol.* 6 (2) (2007) 162–170.
- [56] F. Laffitte, M. Boukobza, J.P. Guichard, C. Hoeffel, D. Reizine, O. Ille, et al., MRI and MRA for diagnosis and follow-up of cerebral venous thrombosis (CVT), *Clin. Radiol.* 52 (9) (1997) 672–679.
- [57] F. Bonneville, Imaging of cerebral venous thrombosis, *Diagn. Interv. Imaging.* 95 (12) (2014) 1145–1150.
- [58] J.M. Ferro, D. Aguiar de Sousa, Cerebral venous thrombosis: an update, *Curr. Neurol. Neurosci. Rep.* 19 (10) (2019) 74.
- [59] Españolas FdACM, RECOMENDACIONES PARA EL DIAGNÓSTICO Y TRATAMIENTO DE EVENTOS TROMBOTICOS TRAS LA VACUNACION FRENTE A COVID-19 [Fecha: 25 de abril de 2021 (versión 4)], Available from: https://facme.es/wp-content/uploads/2021/04/VACUNAS-COVID-Y-EVENTOS-TROMBO%CC%81TICOS-FACME-V4_26-final-.pdf, 2021.
- [60] British Society for Haematology, Guidance produced by the Expert Haematology Panel (EHP) focussed on Vaccine induced Thrombosis and Thrombocytopenia (VITT) United Kingdom, updated 20/04/2021. Available from: <https://b-s-h.org.uk/media/19590/guidance-version-17-on-mngmt-of-vitt-20210420.pdf>, 2021.
- [61] S.M. Silvis, D.A. de Sousa, J.M. Ferro, J.M. Coutinho, Cerebral venous thrombosis, *Nat. Rev. Neurol.* 13 (9) (2017) 555–565.
- [62] Diagnostic and treatment recommendations from the FACME ad-hoc expert working group on the management of cerebral venous sinus thrombosis associated with COVID-19 vaccination, *Neurologia* (2021), <https://doi.org/10.1016/j.nrl.2021.05.001> (Epub ahead of print. PMID: 34049738) (May 6;S0213-4853(21)00083-9. English, Spanish).
- [63] HAN Archive – 00442, Health Alert Network (HAN) [updated 2021–04-13T07:12:31Z], Available from: <https://emergency.cdc.gov/han/2021/han00442.asp>.
- [64] Nazy I. Sachs, J. Ulrich, Donald M. Arnold, Steven E. McKenzie, Phil Choi, Karina Athlans, et al., Recommendations for the clinical and laboratory diagnosis of vaccine-induced immune thrombotic thrombocytopenia (VITT) for SARS-CoV-2 infections: communication from the ISTH SSC Subcommittee on Platelet Immunology, *J. Thromb. Haemost.* 19 (6) (2021) 1585–1588, <https://doi.org/10.1111/jth.15341> (Epub 2021 May 20. PMID: 34018298).
- [65] E.M.H.C. Ammann, K.M. Fillman, et al., Intravenous immune globulin and thromboembolic adverse events: a systematic review and meta-analysis of RCTs, *Am. J. Hematol.* 91 (6) (2016).
- [66] A. Cuker, Gowthami M. Arepally, Beng H. Chong, et al., American Society of Hematology 2018 guidelines for management of venous thromboembolism: heparin-induced thrombocytopenia, *Blood Adv.* 2 (22) (2018) 3360–3392.
- [67] J. Thaler, C. Ay, K.V. Gleixner, A.W. Hauswirth, F. Cacioppo, J. Grafeneder, P. Quehenberger, I. Pabinger, P. Knöbl, Successful treatment of vaccine-induced prothrombotic immune thrombocytopenia (VITP) - Thaler, *J. Thromb. Haemost.* (2021), <https://doi.org/10.1111/jth.15346> (Epub ahead of print. PMID: 33877735).
- [68] A. Soares Ferreira Júnior, S.H. Boyle, M. Kuchibhatla, O.A. Onwuemene, A population-based analysis on the use of therapeutic plasma exchange and intravenous immunoglobulin in heparin-induced thrombocytopenia, *Thromb. Res.* 201 (2021) 6–14.
- [69] K. Salottolo, J. Wagner, D.F. Frei, D. Loy, R.J. Bellon, K. McCarthy, et al., Epidemiology, endovascular treatment, and prognosis of cerebral venous thrombosis: US Center Study of 152 patients, *J. Am. Heart Assoc.* 6 (6) (2017).
- [70] C.-H. Liao, N.-C. Liao, W.-H. Chen, H.-C. Chen, C.-C. Shen, S.-F. Yang, et al., Endovascular mechanical Thrombectomy and on-site chemical thrombolysis for severe cerebral venous sinus thrombosis, *Sci. Rep.* 10 (1) (2020) 4937.
- [71] E. Keller, A. Pangalu, J. Fandino, D. Könti, Y. Yonekawa, Decompressive craniectomy in severe cerebral venous and dural sinus thrombosis, *Acta Neurochir. Suppl.* 94 (2005) 177–183.
- [72] M.E. Wolf, B. Luz, L. Niehaus, P. Bhogal, H. Bänzner, H. Henkes, Thrombocytopenia and intracranial venous sinus thrombosis after “COVID-19 vaccine AstraZeneca” exposure, *J. Clin. Med.* 10 (8) (2021) 1599.
- [73] P.R. Mehta, S. Apap Mangion, M. Benger, B.R. Stanton, J. Czuprynska, R. Arya, et al., Cerebral venous sinus thrombosis and thrombocytopenia after COVID-19 vaccination – A report of two UK cases, *Brain Behav. Immun.* 95 (2021) 514–517, <https://doi.org/10.1016/j.bbi.2021.04.006> (Epub 2021 Apr 20. PMID: 33857630; PMCID: PMC8056834).
- [74] G.P. Castelli, C. Pognani, C. Sozzi, M. Franchini, L. Vivona, Cerebral venous sinus thrombosis associated with thrombocytopenia post-vaccination for COVID-19, *Crit. Care* 25 (1) (2021) 137.
- [75] M. Franchini, S. Testa, M. Pezzo, C. Glingani, B. Caruso, I. Terenziani, et al., Cerebral venous thrombosis and thrombocytopenia post-COVID-19 vaccination, *Thromb. Res.* 202 (2021) 182–183.
- [76] V. D'Agostino, F. Caranci, A. Negro, V. Piscitelli, B. Tuccillo, F. Fasano, et al., A rare case of cerebral venous thrombosis and disseminated intravascular coagulation temporally associated to the COVID-19 vaccine administration, *J. Personal. Med.* 11 (4) (2021) 285.
- [77] K.-L. Muir, A. Kallam, S.A. Koepsell, K. Gundabolu, Thrombotic thrombocytopenia after Ad26.COV2.S vaccination, *New Engl. J. Med.* 384 (20) (2021) 1964–1965, <https://doi.org/10.1056/NEJMc2105869> (Epub 2021 Apr 14. PMID: 33852795; PMCID: PMC8063883).
- [78] J. Sadoff, K. Davis, M. Douoguih, Thrombotic thrombocytopenia after Ad26.COV2.S vaccination — Response from the manufacturer, *New Engl. J. Med.* 384 (20) (2021) 1965–1966, <https://doi.org/10.1056/NEJMc2106075> (Epub 2021 Apr 16. PMID: 33861522; PMCID: PMC8117965).
- [79] A Tiede, U Sachs, A Czwalinna, et al., Prothrombotic immune thrombocytopenia after COVID-19 vaccine, *Blood* (2021), <https://doi.org/10.1182/blood.2021011958>.
- [80] M. Jamme, E. Mosnino, J. Hayon, et al., Fatal cerebral venous sinus thrombosis after COVID-19 vaccination, *Intensive Care Medicine* (2021), <https://doi.org/10.1007/s00134-021-06425-y>.