



## All-suture anchor and unicortical button show comparable biomechanical properties for onlay subpectoral biceps tenodesis

Alexander Otto, MD <sup>a,b,c,\*</sup>, Sebastian Siebenlist, MD <sup>b</sup>, Joshua B. Baldino, PharmD <sup>a</sup>, Matthew Murphy, BS <sup>a</sup>, Lukas N. Muench, MD <sup>b</sup>, Julian Mehl, MD <sup>b</sup>, Elifho Obopilwe, MS <sup>a</sup>, Mark P. Cote, DPT, MSCTR <sup>a</sup>, Andreas B. Imhoff, MD <sup>b</sup>, Augustus D. Mazzocca, MS, MD <sup>a</sup>

<sup>a</sup> Department of Orthopaedic Surgery, UConn Musculoskeletal Institute, University of Connecticut, Farmington, CT, USA

<sup>b</sup> Department of Orthopaedic Sports Medicine, Klinikum rechts der Isar, Technical University of Munich, Munich, Germany

<sup>c</sup> Department of Trauma, Orthopaedic, Plastic and Hand Surgery, University Hospital of Augsburg, Augsburg, Germany

### ARTICLE INFO

#### Keywords:

All-suture anchor  
unicortical biceps button  
long head of the biceps tendon  
LHB  
LHB tenodesis  
subpectoral tenodesis

Level of evidence: Basic Science Study;  
Biomechanics

**Hypothesis:** The purpose of this study was to biomechanically evaluate onlay subpectoral long head of the biceps (LHB) tenodesis with all-suture anchors and unicortical buttons in cadaveric specimens.

**Methods:** After evaluation of bone mineral density, 18 fresh-frozen, unpaired human cadaveric shoulders were randomly assigned to 2 groups: One group received an onlay subpectoral LHB tenodesis with 1 all-suture anchor, whereas the other group received a tenodesis with 1 unicortical button. The specimens were mounted in a servo-hydraulic material testing system. Tendons were initially loaded from 5 N to 100 N for 5000 cycles at 1 Hz. Displacement of the repair constructs was observed with optical tracking. After cyclic loading, each specimen was loaded to failure at a rate of 1 mm/s.

**Results:** The mean displacement after cyclic loading was  $6.77 \pm 3.15$  mm in the all-suture anchor group and  $8.41 \pm 3.17$  mm in the unicortical button group ( $P =$  not significant). The mean load to failure was  $278.05 \pm 38.77$  N for all-suture anchor repairs and  $291.36 \pm 49.69$  N for unicortical button repairs ( $P =$  not significant). The most common mode of failure in both groups was LHB tendon tearing. There were no significant differences between the 2 groups regarding specimen age ( $58.33 \pm 4.37$  years vs.  $58.78 \pm 5.33$  years) and bone mineral density ( $0.50 \pm 0.17$  g/cm<sup>2</sup> vs.  $0.44 \pm 0.19$  g/cm<sup>2</sup>).

**Conclusion:** All-suture anchors and unicortical buttons are biomechanically equivalent in displacement and load-to-failure testing for LHB tenodesis. All-suture anchors can be considered a validated alternative for onlay subpectoral LHB tenodesis.

© 2020 The Author(s). Published by Elsevier Inc. on behalf of American Shoulder and Elbow Surgeons. This is an open access article under the CC BY-NC-ND license (<http://creativecommons.org/licenses/by-nc-nd/4.0/>).

Tenodesis of the long head of the biceps (LHB) tendon has become a widely used treatment for anterior shoulder pain due to LHB pathologies resisting conservative treatment.<sup>14,19,31,39</sup> The 2 most often used surgical approaches for LHB tenodesis are the proximal (supraperacrotal) approach and the distal (subpectoral) approach.<sup>31</sup> The subpectoral approach is reported to be more effective for achieving lasting pain reduction and has lower revision rates than the proximal approach.<sup>1,24,31</sup> Although outcomes studies have shown successful results with both approaches, it is thought

This study has been reviewed via the Human Research Determination Form by the institutional review board of the University of Connecticut, and it was concluded that no institutional review board approval was required (because deidentified specimens do not constitute human subject research).

\* Corresponding author: Alexander Otto, MD, Department of Orthopaedic Surgery, UConn Musculoskeletal Institute, University of Connecticut, 263 Farmington Ave, Farmington, CT 06030, USA.

E-mail address: [alexander.otto@tum.de](mailto:alexander.otto@tum.de) (A. Otto).

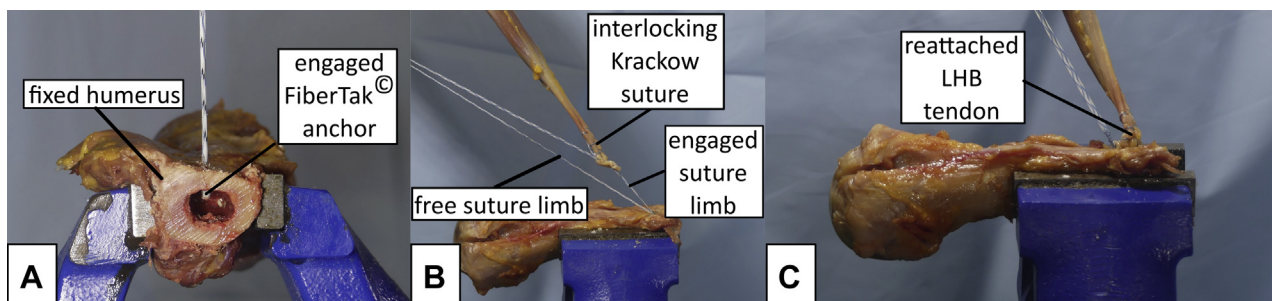
<https://doi.org/10.1016/j.jseint.2020.08.004>

2666-6383/© 2020 The Author(s). Published by Elsevier Inc. on behalf of American Shoulder and Elbow Surgeons. This is an open access article under the CC BY-NC-ND license (<http://creativecommons.org/licenses/by-nc-nd/4.0/>).

that the course of the LHB in the bicipital groove (so-called no man's land) after a proximal LHB tenodesis may be the cause of persistent pain and failure.<sup>1,13,15,17,19,22,31,38,40</sup> Various fixation techniques have been used for both approaches.<sup>1,5,20,30,31,39</sup> Owing to facilitated surgical exposition, variable fixation techniques, and reduced postoperative pain, subpectoral LHB tenodesis has gained popularity among shoulder surgeons.<sup>1</sup> An inlay technique using an interference screw for intramedullary LHB tendon fixation or an onlay technique with suture anchors can be used.<sup>39</sup>

Despite the advantages of subpectoral LHB tenodesis, there are certain complications that need to be considered, including humeral fracture, nerve injury, and brachial artery injury.<sup>8,19,25,29,32–35,37</sup> Mellano et al<sup>23</sup> and Beason et al<sup>4</sup> showed that subpectoral LHB tenodesis performed with an interference screw leads to increased susceptibility of fractures at the humerus.

All-suture anchors have become very popular in shoulder surgery in recent times. These implants can minimize trauma to soft



**Figure 1** After engaging the all-suture anchor against the inner cortex (A), a modified Krackow locking suture was applied on the long head of the biceps (LHB) tendon (B). (C) The LHB tendon was reattached while the free suture limb was tied to the remaining suture limb.

tissue and bone owing to a lower drill diameter, less bone loss, and smaller dimensions than classic solid anchors or fixation buttons. Consequently, all-suture anchors have the potential to reduce the risk of surgery-associated humeral fractures.<sup>4,8,23,29,32,35</sup> Because of the small drill diameter used for all-suture anchors, revision is easier; moreover, these anchors are a reasonable substitute for revision cases. Furthermore, follow-up of tendon healing through the postoperative course with a magnetic resonance imaging study would be allowed by the metal-free implant design of all-suture anchors. The benefits of these newly developed implant devices are already well described for labral repair at the hip and shoulder, as well as rotator cuff repair.<sup>9,16,21</sup> In addition, for distal biceps tendon repair, as well as proximal hamstring repair, these anchor types have proved their effectiveness in the biomechanical setting.<sup>27,28</sup>

The purpose of this biomechanical study was to determine displacement under cyclic loading and load to failure of an onlay subpectoral LHB tenodesis with all-suture anchors and unicortical buttons in cadaveric specimens. It was hypothesized that intramedullary all-suture anchors would be able to provide equal load to failure and comparable displacement when compared with unicortical button fixation. The observations of this study might help shoulder surgeons who are considering all-suture anchors and unicortical buttons for onlay subpectoral LHB tenodesis.

**Materials and methods**

A total of 18 fresh-frozen, unpaired human cadaveric shoulders were used in this study and were randomly allocated into 2 groups. All specimens were obtained from Science Care (Phoenix, AZ, USA).

The cadavers were thawed overnight to room temperature prior to biomechanical testing. All specimens received bone mineral density scans with a GE Lunar Prodigy (GE Healthcare, Chicago, IL, USA) 50 mm distal to the proximal end of the bicipital groove at the area of the surgical repair to exclude differences between testing


groups. Each shoulder was carefully dissected of soft tissue to preserve the LHB tendon. The humerus was cut 15 cm from the top of the humeral head to maintain a consistent length under testing conditions. To approximate the in vivo force vector of the biceps muscle and tendon after subpectoral LHB tenodesis, the humerus and biceps tendon were positioned parallel to the longitudinal axis of the humerus as described previously.<sup>36</sup> Specimens were randomly assigned to repair by an all-suture anchor or unicortical button.

*All-suture anchor repair*


A unicortical hole was created with a 1.6-mm drill guide 2 cm proximal to the inferior border of the pectoralis major tendon insertion.<sup>36</sup> An all-suture anchor loaded with 1.3-mm suture tape material (FiberTak; Arthrex, Naples, FL, USA) was inserted and secured in the hole (Fig. 1, A). One free limb of the suture was used to create a modified Krackow locking suture starting 20 mm proximal to the musculotendinous junction<sup>20</sup> (Fig. 1, B). The remaining suture limb was used to secure the construct with 8 surgical knots (Fig. 1, C).

*Unicortical button repair*

A unicortical hole was established with a 3.2-mm spade-tip drill 2 cm proximal to the inferior border of the pectoralis major tendon insertion.<sup>36</sup> A No. 2 suture (FiberWire; Arthrex) was used to apply a modified Krackow locking suture starting 20 mm proximal to the musculoskeletal junction.<sup>20</sup> Each limb of the suture was passed through a proximal tenodesis button (BicepsButton; Arthrex) in opposite directions, allowing the button to slide along the suture limbs. The button was then pushed into the intramedullary canal of the humerus and flipped (Fig. 2, A). Tension was applied to each suture limb to bring the biceps into contact with the anterior cortex of the humerus and to bring the button into contact with the



**Figure 2** (A) Krackow locking sutures of the long head of the biceps (LHB) tendon were inserted into a biceps button, which was engaged with the inner humeral cortex. (B) The tendon was reattached by alternating pull on each suture limb and was fixed by tying the suture limbs.



**Figure 3** (A) The specimen was securely mounted for testing in an axial direction. (B) Optical tracking was performed with 2 markers. MTS, material testing system; LHB, long head of biceps.

interior cortex. The tendon was securely fixed with 8 surgical knots (Fig. 2, B).

**Biomechanical testing**

The specimens were mounted inverted in a servo-hydraulic material testing system (MTS Systems, Eden Prairie, MN, USA) for loading along the longitudinal axis of the humerus (Fig. 3, A). The tendons were loaded from 5 N to 100 N for 5000 load cycles at 1 Hz to evaluate the displacement of the repair construct.<sup>36</sup> Displacement was measured with Kinovea software (version 0.8.27). One optical marker was placed on the bone at the level of the repair site to correct for humeral motion, and one was placed directly on the tendon 2 cm distal to the repair site at the end of the suture reinforcement (Fig. 3, B). After cyclic loading, each specimen was loaded to failure at a rate of 1 mm/s.<sup>36</sup> The mode of failure was documented for each specimen.

**Statistical analysis**

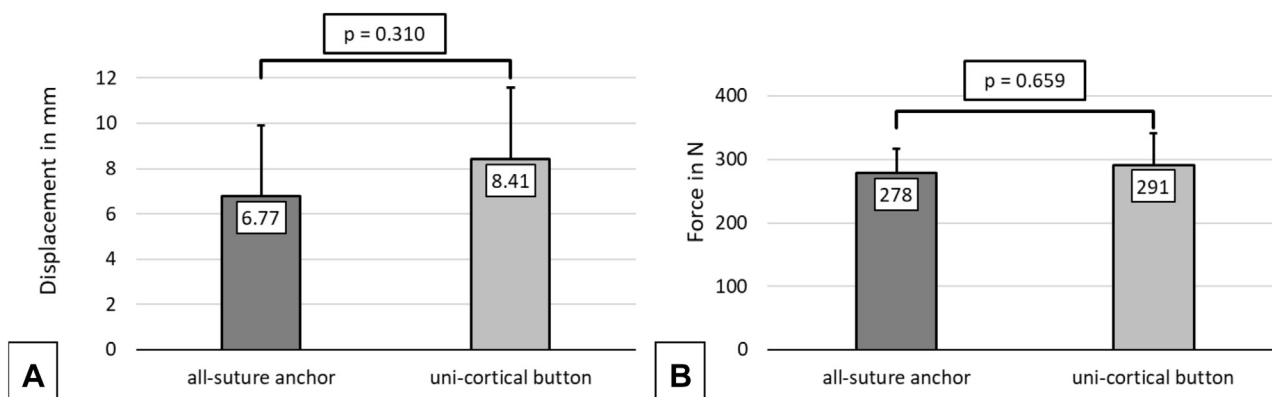
An a priori power analysis was conducted using data from a previous study applying the same setup.<sup>36</sup> With the assumption of a standard deviation of 45 N, a sample size of 9 specimens was determined to provide 93% power to detect a 70-N difference between the 2 repair techniques at an  $\alpha$  of .05. Analysis was performed using the R programming language (version 3.5.3; R

Foundation for Statistical Computing, Vienna, Austria) and SPSS statistical software (version 25; IBM, Armonk, NY, USA). The Mann-Whitney *U* test was used for group comparisons given non-normality assumptions.

**Results**

There were 6 female and 3 male specimens in the all-suture anchor cohort. The mean age was  $58.33 \pm 4.37$  years, and the mean bone mineral density was  $0.50 \pm 0.17$  g/cm<sup>2</sup>. There were 5 female and 4 male specimens in the unicortical button cohort. The mean age was  $58.78 \pm 5.33$  years, and the mean bone mineral density was  $0.44 \pm 0.19$  g/cm<sup>2</sup>. There was no significant difference between the 2 groups regarding specimen age and bone mineral density.

The mean displacement was  $6.77 \pm 3.15$  mm for all-suture anchor repairs and  $8.41 \pm 3.17$  mm for unicortical button repairs ( $P =$  not significant) after cyclic loading (Fig. 4, A). No failures occurred during cyclic loading. The mean load to failure was  $278.05 \pm 38.77$  N for all-suture anchor repairs and  $291.36 \pm 49.69$  N for unicortical button repairs ( $P =$  not significant) (Fig. 4, B). Tearing of the LHB tendon was the most common mode of failure observed in the all-suture anchor group ( $n = 6$ ), as well as the unicortical button group ( $n = 8$ ). Additionally, failure by suture rupture occurred in 3 cases in the all-suture anchor group and 1 case in the unicortical button group. However, all cases that failed by suture rupture initially



**Figure 4** Displacement after cyclic loading (A) and load to failure (B) for all-suture anchor and unicortical button repair techniques. Data are presented as means and standard deviations (error bars).

showed a heterogeneous amount of LHB tendon tearing, which was followed by entanglement of the dissolving locking Krackow suture pattern while suture material was still engaged with the tendon. Continued axial loading ultimately led to suture rupture. There was no significant correlation between observed parameters and specimen properties. The mean stiffness was  $111.61 \pm 26.12$  N/mm for all-suture anchor repairs and  $134.40 \pm 23.41$  N/mm for unicortical button repairs ( $P =$  not significant). No specimens were excluded during the conduct of the study.

## Discussion

The most important finding of this study is that the all-suture anchor technique and the unicortical button technique for subpectoral LHB repair showed comparable mean displacement under cyclic loading and mean peak load to failure. The major failure mode observed was tendon rupture in both groups, whereas in a few cases, suture rupture occurred in both groups. Overall, all-suture anchors can be regarded as an equivalent alternative for onlay subpectoral LHB tenodesis.

Displacement values of 8.1 mm,<sup>6</sup> 11.8 mm,<sup>11</sup> and 12.5 mm<sup>18</sup> have been reported in prior biomechanical studies evaluating subpectoral LHB tenodesis using all-suture anchors. Frank et al<sup>11</sup> tested conventional suture anchors for onlay subpectoral biceps tenodesis as well and observed a displacement value of 14.4 mm. For onlay subpectoral LHB tenodesis with an intramedullary button, displacement values of 8.9 mm,<sup>2</sup> 11.3 mm,<sup>5</sup> 14.5 mm,<sup>36</sup> and 29.2 mm<sup>18</sup> have been reported. The observed displacement under cyclic loading of all-suture anchors in our study is lower than the observed values in corresponding biomechanical studies.<sup>2,5,6,11,36</sup> The fact that no failures occurred during cyclic loading and the observed low displacement values indicate that all-suture anchors possess high primary stability under cyclic loading.

The mean peak load to failure for all-suture anchors used for subpectoral LHB tenodesis ranges between 170 and 290 N.<sup>3,6,11,18</sup> Conventional suture anchors for onlay subpectoral biceps tenodesis have shown a mean peak load of 192.3 N.<sup>11</sup> The mean peak load values for onlay subpectoral LHB tenodesis with intramedullary buttons have been variously reported as 99.4 N,<sup>36</sup> 125 N,<sup>18</sup> 174 N,<sup>2</sup> and 218 N.<sup>5</sup> The observed peak load to failure of all-suture anchors in our study is within this range,<sup>2,3,5,6,11,18,36</sup> suggesting that all-suture anchors show equal primary stability. Tendon rupture was the failure mode most often observed in both groups, whereas only a few cases in both groups showed suture rupture. Heterogeneous failure modes have been described in prior biomechanical evaluations of subpectoral tenodesis of the LHB tendon.<sup>2,3,6,18</sup>

The mean stiffness of all-suture anchor repair constructs for subpectoral LHB tenodesis was 26 N/mm,<sup>6</sup> 59 N/mm,<sup>18</sup> and 82 N/mm<sup>3</sup> in prior biomechanical studies. In our study, higher values than the reported range were observed for the mean repair construct stiffness of all-suture anchors. This finding suggests that all-suture anchors have high rigidity, which is equal to that of the unicortical buttons evaluated in this study.

Biomechanical studies have shown a correlation between bone mineral density and pullout strength for all-suture anchors.<sup>10,26</sup> There was no significant difference in bone mineral density between the 2 groups in our study, and we found no correlation between load to failure and bone mineral density.

The reported average age of specimens used in prior biomechanical studies evaluating subpectoral LHB tenodesis was between 52 and 79 years.<sup>2,3,5,6,11,36</sup> The specimens in this study had a representative average age that was within this range.<sup>2,3,5,6,11,36</sup>

There are limitations to this study that need to be considered. This study was performed in unpaired specimens. However, this characteristic might be negligible because there were no significant

differences in bone mineral density and age between the 2 groups. To allow optimal optical tracking and consistent test conditions, 1 marker was placed directly on the LHB tendon at the end of the suture reinforcement. Although the current repairs were all performed in macroscopically physiological parts of the LHB tendon, other surgeons might consider removing more of the LHB tendon to address degeneration or to obtain a more anatomic biceps muscle level. Owing to the use of a cryo-clamp that firmly secures the LHB muscle and given the limited LHB muscle tissue available for fixation, the positioning of an optical marker further distal was not possible. The biomechanical evaluation was performed in a time-zero setting without the influence of (soft) tissue healing. In vivo tendon healing might affect the displacement and failure load of tissue. Consequently, only the primary stability of each repair was observed. Furthermore, comparison to the literature is limited because different methods for the biomechanical evaluation were applied in each study group.<sup>2,3,5,6,11,18</sup>

A strength of this study is that the biomechanical setup was previously demonstrated in a study evaluating subpectoral LHB tenodesis as well.<sup>36</sup> Therefore, the inverted alignment of the humerus and biceps tendon parallel to the longitudinal axis can be considered a validated setup approach. Furthermore, a comparable approach to mount the specimens inverted and re-create the in vivo vector of the biceps muscle and tendon after a subpectoral LHB tenodesis has been followed by multiple study groups.<sup>2,5–7,11,18</sup>

Another strength of this study is that specimens with a representative age for subpectoral LHB tenodesis were evaluated. The average patient age at surgery for subpectoral LHB tenodesis in the literature ranges between 49 and 63 years.<sup>12,17,25,40</sup> The current biomechanical evaluation was performed on representative specimens.

Although all-suture anchors have already been tested for LHB tenodesis,<sup>3,6,11,18</sup> comparison of the current all-suture anchor and its concomitant type of suture material with a unicortical button technique with the same suture pattern for LHB tendon fixation has not been widely described. The current biomechanical comparison between all-suture anchors and intramedullary buttons for onlay subpectoral LHB tenodesis shows that at time zero, all-suture anchors can be considered an equal alternative for onlay subpectoral LHB tenodesis. This might help surgeons performing onlay subpectoral LHB tenodesis who are considering all-suture anchors for their repairs.

## Conclusion

All-suture anchors and unicortical buttons are biomechanically equivalent in displacement and load-to-failure testing for LHB tenodesis. All-suture anchors can be considered a validated alternative for onlay subpectoral LHB tenodesis.

## Disclaimer

The University of Connecticut Health Center/UConn Musculoskeletal Institute receives funding from Arthrex. The company had no influence on study design, data collection, or interpretation of the results or the final manuscript.

Alexander Otto received material support from Arthrex during the conduct of the study.

Sebastian Siebenlist is a consultant for Arthrex.

Mark Cote reports personal fees outside the submitted work from the Arthroscopy Association of North America.

Andreas B. Imhoff reports personal fees outside the submitted work from Arthrex, personal fees from Medi Bayreuth (Bayreuth, Germany), and personal fees from ArthroSurface (Franklin, MA, USA).

Augustus D. Mazzocca received grants while conducting the study from Arthrex and has received other funding outside the submitted work from Arthrex.

All remaining authors declare no conflict of interest.

## References

- Angelo RL. Surgical management of proximal long head biceps tendon disorders. *Sports Med Arthrosc Rev* 2018;26:176–80. <https://doi.org/10.1097/JSA.000000000000197>.
- Arora AS, Singh A, Koonce RC. Biomechanical evaluation of a unicortical button versus interference screw for subpectoral biceps tenodesis. *Arthroscopy* 2013;29:638–44. <https://doi.org/10.1016/j.arthro.2012.11.018>.
- Baleani M, Francesconi D, Zani L, Giannini S, Snyder SJ. Suprapectoral biceps tenodesis: a biomechanical comparison of a new "soft anchor" tenodesis technique versus interference screw biceps tendon fixation. *Clin Biomech (Bristol, Avon)* 2015;30:188–94. <https://doi.org/10.1016/j.clinbiomech.2014.12.001>.
- Beason DP, Shah JP, Duckett JW, Jost PW, Fleisig GS, Cain EL Jr. Torsional fracture of the humerus after subpectoral biceps tenodesis with an interference screw: a biomechanical cadaveric study. *Clin Biomech (Bristol, Avon)* 2015;30:915–20. <https://doi.org/10.1016/j.clinbiomech.2015.07.009>.
- Buchholz A, Martetschlagner F, Siebenlist S, Sandmann GH, Hapfelmeier A, Lenich A, et al. Biomechanical comparison of intramedullary cortical button fixation and interference screw technique for subpectoral biceps tenodesis. *Arthroscopy* 2013;29:845–53. <https://doi.org/10.1016/j.arthro.2013.01.010>.
- Chiang FL, Hong CK, Chang CH, Lin CL, Jou IM, Su WR. Biomechanical comparison of all-suture anchor fixation and interference screw technique for subpectoral biceps tenodesis. *Arthroscopy* 2016;32:1247–52. <https://doi.org/10.1016/j.arthro.2016.01.016>.
- DeAngelis JP, Chen A, Wexler M, Hertz B, Grimaldi Bournissaint L, Nazarian A, et al. Biomechanical characterization of unicortical button fixation: a novel technique for proximal subpectoral biceps tenodesis. *Knee Surg Sports Traumatol Arthrosc* 2015;23:1434–41. <https://doi.org/10.1007/s00167-013-2775-6>.
- Dein EJ, Huri G, Gordon JC, McFarland EG. A humerus fracture in a baseball pitcher after biceps tenodesis. *Am J Sports Med* 2014;42:877–9. <https://doi.org/10.1177/0363546513519218>.
- Denard PJ, Burkhart SS. The evolution of suture anchors in arthroscopic rotator cuff repair. *Arthroscopy* 2013;29:1589–95. <https://doi.org/10.1016/j.arthro.2013.05.011>.
- Douglass NP, Behn AW, Safran MR. Cyclic and load to failure properties of all-suture anchors in synthetic acetabular and glenoid cancellous bone. *Arthroscopy* 2017;33:977–985.e5. <https://doi.org/10.1016/j.arthro.2016.11.022>.
- Frank RM, Bernardoni ED, Veera SS, Waterman BR, Griffin JW, Shewman EF, et al. Biomechanical analysis of all-suture suture anchor fixation compared with conventional suture anchors and interference screws for biceps tenodesis. *Arthroscopy* 2019;35:1760–8. <https://doi.org/10.1016/j.arthro.2019.01.026>.
- Geaney LE, Mazzocca AD. Biceps brachii tendon ruptures: a review of diagnosis and treatment of proximal and distal biceps tendon ruptures. *Phys Sportsmed* 2010;38:117–25. <https://doi.org/10.3810/psm.2010.06.1790>.
- Gombera MM, Kahlenberg CA, Nair R, Saltzman MD, Terry MA. All-arthroscopic suprapectoral versus open subpectoral tenodesis of the long head of the biceps brachii. *Am J Sports Med* 2015;43:1077–83. <https://doi.org/10.1177/0363546515570024>.
- Gottschalk MB, Karas SG, Ghattas TN, Burdette R. Subpectoral biceps tenodesis for the treatment of type II and IV superior labral anterior and posterior lesions. *Am J Sports Med* 2014;42:2128–35. <https://doi.org/10.1177/0363546514540273>.
- Green JM, Getelman MH, Snyder SJ, Burns JP. All-arthroscopic suprapectoral versus open subpectoral tenodesis of the long head of the biceps brachii without the use of interference screws. *Arthroscopy* 2017;33:19–25. <https://doi.org/10.1016/j.arthro.2016.07.007>.
- Harris JD. Hip labral repair: options and outcomes. *Curr Rev Musculoskelet Med* 2016;9:361–7. <https://doi.org/10.1007/s12178-016-9360-9>.
- Jeong HY, Kim JY, Cho NS, Rhee YG. Biceps lesion associated with rotator cuff tears: open subpectoral and arthroscopic intracuff tenodesis. *Orthop J Sports Med* 2016;4:2325967116645311. <https://doi.org/10.1177/2325967116645311>.
- Lacheta L, Rosenberg SI, Brady AW, Dornan GJ, Millett PJ. Biomechanical comparison of subpectoral biceps tenodesis onlay techniques. *Orthop J Sports Med* 2019;7:2325967119876276. <https://doi.org/10.1177/2325967119876276>.
- Levy DM, Meyer ZI, Campbell KA, Bach BR. Subpectoral biceps tenodesis. *Am J Orthop (Belle Mead NJ)* 2016;45:68–74.
- Mazzocca AD, Bicos J, Santangelo S, Romeo AA, Arciero RA. The biomechanical evaluation of four fixation techniques for proximal biceps tenodesis. *Arthroscopy* 2005;21:1296–306. <https://doi.org/10.1016/j.arthro.2005.08.008>.
- Mazzocca AD, Chowanec D, Cote MP, Fierra J, Apostolakis J, Nowak M, et al. Biomechanical evaluation of classic solid and novel all-soft suture anchors for glenoid labral repair. *Arthroscopy* 2012;28:642–8. <https://doi.org/10.1016/j.arthro.2011.10.024>.
- Mazzocca AD, Cote MP, Arciero CL, Romeo AA, Arciero RA. Clinical outcomes after subpectoral biceps tenodesis with an interference screw. *Am J Sports Med* 2008;36:1922–9. <https://doi.org/10.1177/0363546508318192>.
- Mellano CR, Frank RM, Shin JJ, Jain A, Zuke WA, Mascarenhas R, et al. Subpectoral biceps tenodesis with PEEK interference screw: a biomechanical analysis of humeral fracture risk. *Arthroscopy* 2018;34:806–13. <https://doi.org/10.1016/j.arthro.2017.09.012>.
- Moon SC, Cho NS, Rhee YG. Analysis of "hidden lesions" of the extra-articular biceps after subpectoral biceps tenodesis: the subpectoral portion as the optimal tenodesis site. *Am J Sports Med* 2015;43:63–8. <https://doi.org/10.1177/0363546514554193>.
- Nho SJ, Reiff SN, Verma NN, Slabaugh MA, Mazzocca AD, Romeo AA. Complications associated with subpectoral biceps tenodesis: low rates of incidence following surgery. *J Shoulder Elbow Surg* 2010;19:764–8. <https://doi.org/10.1016/j.jse.2010.01.024>.
- Oh JH, Jeong HJ, Yang SH, Rhee SM, Itami Y, McGarry MH, et al. Pullout strength of all-suture anchors: effect of the insertion and traction angle—a biomechanical study. *Arthroscopy* 2018;34:2784–95. <https://doi.org/10.1016/j.arthro.2018.04.028>.
- Otto A, DiCosimo AM, Baldino JB, Mehl J, Obopilwe E, Cote MP, et al. Biomechanical evaluation of proximal hamstring repair: all-suture anchor versus titanium suture anchor. *Orthop J Sports Med* 2020;8:2325967119892925. <https://doi.org/10.1177/2325967119892925>.
- Otto A, Mehl J, Obopilwe E, Cote M, Lacheta L, Scheiderer B, et al. Biomechanical comparison of onlay distal biceps tendon repair: all-suture anchors versus titanium suture anchors. *Am J Sports Med* 2019;47:2478–83. <https://doi.org/10.1177/0363546519860489>.
- Overmann AL, Colantonio DF, Wheatley BM, Volk WR, Kilcoyne KG, Dickens JF. Incidence and characteristics of humeral shaft fractures after subpectoral biceps tenodesis. *Orthop J Sports Med* 2019;7. <https://doi.org/10.1177/2325967119833420>.
- Patel KV, Bravman J, Vidal A, Chrisman A, McCarty E. Biceps tenotomy versus tenodesis. *Clin Sports Med* 2016;35:93–111. <https://doi.org/10.1016/j.csm.2015.08.008>.
- Provencher MT, LeClere LE, Romeo AA. Subpectoral biceps tenodesis. *Sports Med Arthrosc Rev* 2008;16:170–6. <https://doi.org/10.1097/JSA.0b013e3181824edf>.
- Reiff SN, Nho SJ, Romeo AA. Proximal humerus fracture after keyhole biceps tenodesis. *Am J Orthop (Belle Mead NJ)* 2010;39:E61–3.
- Rhee PC, Spinner RJ, Bishop AT, Shin AY. Iatrogenic brachial plexus injuries associated with open subpectoral biceps tenodesis: a report of 4 cases. *Am J Sports Med* 2013;41:2048–53. <https://doi.org/10.1177/0363546513495646>.
- Saithna A, Longo A, Jordan RW, Leiter J, MacDonald P, Old J. A cadaveric assessment of the risk of nerve injury during open subpectoral biceps tenodesis using a bicortical guidewire. *Knee Surg Sports Traumatol Arthrosc* 2017;25:2858–63. <https://doi.org/10.1007/s00167-015-3972-2>.
- Sears BW, Spencer EE, Getz CL. Humeral fracture following subpectoral biceps tenodesis in 2 active, healthy patients. *J Shoulder Elbow Surg* 2011;20:e7–11. <https://doi.org/10.1016/j.jse.2011.02.020>.
- Sethi PM, Rajaram A, Beitzel K, Hackett TR, Chowanec DM, Mazzocca AD. Biomechanical performance of subpectoral biceps tenodesis: a comparison of interference screw fixation, cortical button fixation, and interference screw diameter. *J Shoulder Elbow Surg* 2013;22:451–7. <https://doi.org/10.1016/j.jse.2012.03.016>.
- Sethi PM, Vadasdi K, Greene RT, Vitale MA, Duong M, Miller SR. Safety of open suprapectoral and subpectoral biceps tenodesis: an anatomic assessment of risk for neurologic injury. *J Shoulder Elbow Surg* 2015;24:138–42. <https://doi.org/10.1016/j.jse.2014.06.038>.
- Taylor SA, Ramkumar PN, Fabricant PD, Dines JS, Gausden E, White A, et al. The clinical impact of bicipital tunnel decompression during long head of the biceps tendon surgery: a systematic review and meta-analysis. *Arthroscopy* 2016;32:1155–64. <https://doi.org/10.1016/j.arthro.2016.02.020>.
- Voss A, Cerciello S, Yang J, Beitzel K, Cote MP, Mazzocca AD. Open subpectoral tenodesis of the proximal biceps. *Clin Sports Med* 2016;35:137–52. <https://doi.org/10.1016/j.csm.2015.08.007>.
- Werner BC, Evans CL, Holzgrefe RE, Tuman JM, Hart JM, Carson EW, et al. Arthroscopic suprapectoral and open subpectoral biceps tenodesis: a comparison of minimum 2-year clinical outcomes. *Am J Sports Med* 2014;42:2583–90. <https://doi.org/10.1177/0363546514547226>.