

.....

Protecting the Cochlea during Stapes Surgery: Is There a Role for Corticosteroids?

Jan Kiefer^a, Qing Ye^b, Jochen Tillein^c, O. Adunka^b, Wolfgang Arnold^a,
Wolfgang Gstöttner^b

^aKlinik für Hals-Nasen-Ohrenheilkunde, Klinikum rechts der Isar, Technische Universität München, Munich, ^bKlinik für Hals-Nasen-Ohrenheilkunde und ^cZentrum der Physiologie, Johann Wolfgang Goethe-Universität, Frankfurt am Main, Germany

Abstract

The aim of the present study was to evaluate possible protective effects of corticosteroids on the inner ear after surgical trauma and to exclude any ototoxicity. A corticosteroid (triamcinolone, Volon A[®]) was topically applied to the inner ear of guinea pigs, either by extracochlear application with permeation and diffusion through the round window membrane or by intracochlear application with direct infusion into the inner ear via a cochleostomy. Threshold and input/output functions of compound action potentials (CAPs) were determined before and after application of the corticosteroid. We found that extracochlear application of the corticosteroid induced insignificant mild shifts of mean CAP thresholds, but significantly increased mean maximal amplitudes of input/output function after the 14th day following application of the steroid. No detrimental effects on cochlear function were noted in the extracochlear group, indicating absence of ototoxicity with the concentrations used. In the intracochlear group, CAP thresholds and amplitudes of input/output function recovered from partial hearing loss due to cochleostomy between 7 and 14 days after application of the steroid, whereas in controls without steroid application, no such recovery of hearing was detected. These results suggest that topical application of triamcinolone has no ototoxic effect and that it leads to increased recovery of cochlear functions after trauma in the guinea pig inner ear.

Copyright © 2007 S. Karger AG, Basel

Stapes surgery in experienced hands is a safe procedure and inner ear damage with hearing loss or severe vertigo only seldom occurs. However, in these rare instances, it represents a severe complication and should be avoided in any

case. The most important issue in prevention of hearing loss after stapes surgery is a meticulous surgical technique; nevertheless, hearing loss may occur even in technically correct and uneventful surgical procedures. Mechanisms other than direct mechanical trauma, e.g. inflammation or infection, acoustic and metabolic stress and disturbance of fluid balance, may be at the origin of postoperative hearing loss. Additional pharmacological treatment for the protection of the inner ear, e.g. with corticosteroids, has found interest and is applied in clinical practice in an attempt to prevent or alleviate auditory dysfunction.

Corticosteroids have been shown to reduce noise-induced cochlear damage and hearing loss [1–3], increase recovery after noise trauma [4, 5] and are the mainstay in the treatment of sudden sensorineural hearing loss [6, 7]. However, efficacy in stapedoplasty is still under debate. Riechelmann et al. [8] found no positive effect but increased patient discomfort after intravenous administration of corticosteroids in stapedoplasty; Hendershot [9] stated that short-acting corticosteroids were able to alleviate postoperative serous labyrinthitis, whereas long-acting corticosteroids increased the incidence of postoperative vertigo and reduced the success rate. Spandow et al. [10] reported possible ototoxicity after local administration of hydrocortisone.

Possible ways of application are systemic and local application, either via diffusion through the round window or by direct instillation after opening of inner ear spaces.

Niedermeyer et al. [11] have measured concentrations of prednisolone in the human perilymph after systemic application and found that high doses of 250 mg were necessary to obtain a significant increase of concentration. They also noted a great interindividual variability of results.

Tobita et al. [12] were able to measure uptake of prednisolone, with a peak 1 h after application and a prolonged stay in cochlear tissue only at high doses of 100 mg/kg (corresponding to a human dosage of 7,000 mg for a 70-kg patient); at 30 mg/kg, corresponding to 1,000 mg human dosage, they could not detect an increase in steroid concentration in the tissue with their measurement system. Relatively high doses of corticosteroid seem to be necessary to exert measurable effects in the inner ear, but they carry the risk of systemic side effects. Therefore, direct instillation of drugs into the cochlea offers several advantages, allowing delivery of high drug concentrations to the target organ while minimizing side effects. Some attempts at steroid delivery directly into the cochlea, such as intratympanic therapy [13] and osmotic micropump infusion [14, 15], have been reported.

To further evaluate the efficacy and exclude any ototoxic effects, we decided to design an experimental study on the safety of topically applied steroid and protective effects on acoustic hearing in guinea pigs after specific trauma.

Methods

Study Design

The design of the study included two arms. In the first study arm, steroids were applied extracochlearly at the round window, avoiding any direct mechanical impingement on the cochlea, to test whether steroids have any ototoxic effect. In the second arm of the study, steroids were applied intracochlearly to evaluate possible protective effects of a locally applied steroid on the inner ear after a specific surgical trauma to the cochlea, namely cochleostomy.

Animal Preparation and Application of Corticosteroids

This study complied with the guidelines of the Institutional Review Board. All efforts were made to minimize both the number of animals used and their suffering.

Eleven pigmented guinea pigs (21 ears), weighing from 400 to 630 g, were used in the study. Guinea pigs were anesthetized by intraperitoneal injection of Ketavet (ketamine, Pharmacia & Upjohn GmbH, Erlangen, Germany; dose: 85 mg/kg), xylazine (Rompun, Bayer, Leverkusen, Germany; dose: 8.5 mg/kg), and atropine (Braun, Melsungen, Germany; dose: 0.3 mg/kg). Body temperature was maintained at 37°C during the experiments. The otic bulla was exposed via a postauricular incision and opened with a hole of 2 × 2 mm to allow visualization of the round window.

In the extracochlear study arm, a size of 1 × 1 mm Gelfoam with 5 µl Volon A® (crystalline triamcinolone acetone solution, 5 ears, verum group) or saline (Ringer's solution, 5 ears, control group) was implanted in contact with the round window membrane. In the intracochlear study arm, a cochleostomy of about 1 × 1 mm in the basal turn of the cochlea was drilled and 3 µl Volon A (7 ears, verum group), or Ringer's solution (4 ears, control group) were infused into the scala tympani, using a microsyringe.

Measurements of Compound Action Potentials

A gold hook electrode was anchored to the bony edge of the round window and connected to a percutaneous plug at the vertex to serve as recording electrodes for the acoustically evoked compound action potentials (CAPs) of the auditory nerve.

Acoustic thresholds were determined in a soundproof chamber using frequency-specific gauss pips. The acoustic stimuli were delivered to the ear via a tightly sealed tubed earphone. The intensity of the gauss pip was changed in 5-dB steps between 20 and 119 dB SPL. Thresholds of CAPs were determined at 25 frequencies, distributed logarithmically between 250 Hz and 64 kHz. In addition, input/output (I/O) functions of CAPs in response to click stimuli of increasing intensity were recorded to assess the cochlear function at threshold and suprathreshold levels. CAP amplitudes were measured from the first negative peak to the subsequent positive peak of the waveform through a programmed algorithm.

Frequency-specific thresholds and I/O functions were determined after opening of the bulla, prior to the placement of Gelfoam at the round window or before cochleostomy, and repeated soon after the placement of Gelfoam or cochleostomy and regularly on days 1, 3, 7, 14, 21 and 28 after the operation.

Statistical Analyses

Paired t tests were used to analyze pre- and postoperative results within animals. Unpaired t tests were used for comparison of group results. Differences were considered statistically significant when $p < 0.05$. Mean values are given \pm SD.

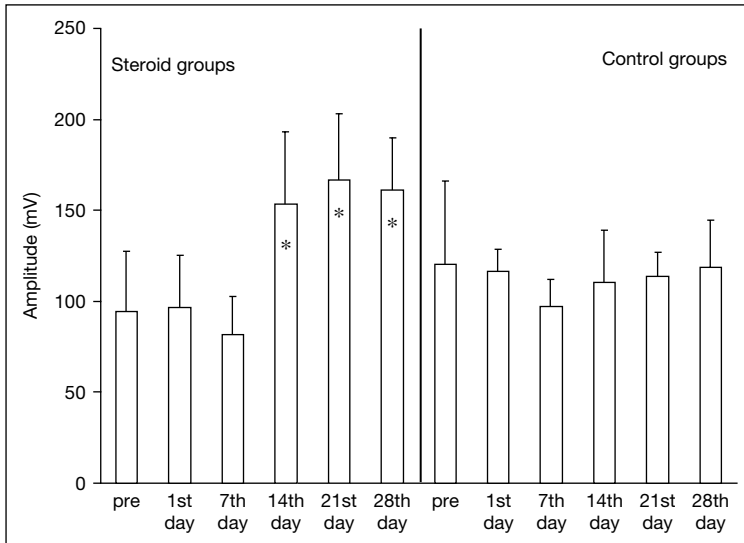


Fig. 1. Mean maximum amplitudes of CAPs at different intervals after extracochlear application of either corticosteroid or saline. Note the significant increase of amplitudes in the steroid group at days 14, 21 and 28. Significant changes ($p < 0.05$) are marked with an asterisk.

Results

Extracochlear Study Arm

No significant shifts of mean CAP thresholds at different frequencies have been observed after the application of the corticosteroid or in the control group. Whereas thresholds remained unchanged, mean maximal amplitudes of I/O function in response to click stimuli at suprathreshold levels increased significantly ($p < 0.05$) at days 14, 21, and 28 after application of the steroid in comparison with amplitudes prior to the application. There were no significant changes of amplitudes from pre- to postapplication of saline in the control group (fig. 1). These results indicate that there are no ototoxic effects, but on the contrary, steroids increased amplitudes of CAPs.

Intracochlear Study Arm

Soon after cochleostomy, thresholds increased up to about 10–20 dB in both the corticosteroid group as well as in the control group. Cochleostomy itself induced a significant hearing loss ($p < 0.05$) in comparison with the

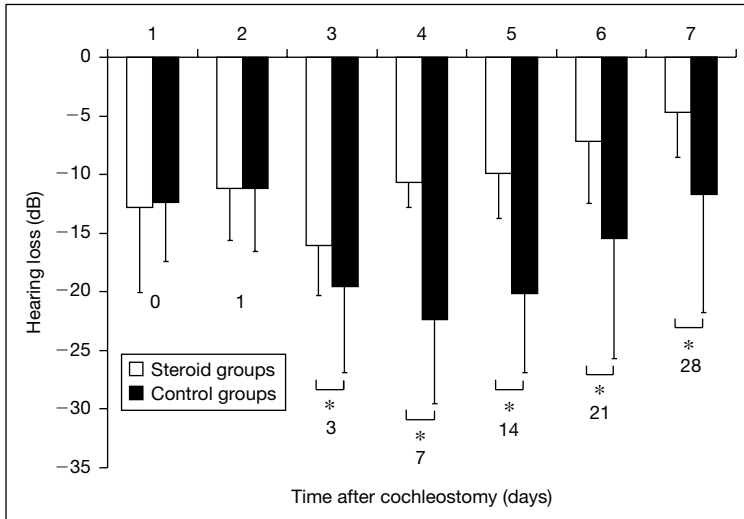


Fig. 2. Mean changes of thresholds after cochleostomy in the steroid and the control group at different time intervals after operation. Significant changes ($p < 0.05$) are marked with an asterisk.

values prior to cochleostomy. The shift of thresholds was most prominent in the high-frequency range from 8 to 64 kHz.

In the control group without corticosteroids, thresholds continued to increase up to day 7 and only little recovery has been seen afterwards.

In the steroid group, thresholds also increased up to day 3, but then, recovery of CAP thresholds was found on day 7, and gradually continued until day 28, when it returned close to the presurgical level. In the control group, no notable recovery occurred until the end of the experiment. Statistic comparison of mean CAP thresholds in the steroid group showed significant differences between pre- and postcochleostomy at the time of surgery and on days 1, 3, 7 and 14, but no longer on days 21, and 28, whereas in the control group, statistically significant differences of mean CAP thresholds persisted at all intervals (fig. 2).

Mean maximal amplitudes of I/O function, both from the steroid and the control group, decreased immediately after cochleostomy, and were down to the lowest level at the 3rd day. In the steroid group, recovery could be found on day 14, which continued until day 28. Amplitudes from the control group stayed at a low level until day 14 and recovered only after the 21st day following operation, about 1 week later than in the steroid group.

Discussion

The safety and efficacy of topic application of steroids to the inner ear is still controversial and few reports on possible ototoxicity are available. Doubts about the effects of steroids on inner ear function still exist [16–18].

In this study, we investigated the safety of topically applied steroid and possible protective effects on acoustic hearing in guinea pigs after surgical trauma to the inner ear. Our findings from this study were consistent with those studies which did not find ototoxic effects.

In the extracochlear group, hearing of animals in both the steroid as well as the control group did not change significantly from the time of application of the drug up to 28 days after surgery; on the contrary, even enhanced amplitudes of CAPs were found in the steroid group. The latter phenomena could be partially interpreted by the study of Shirwany et al. [19], in which they observed that blood flow in the cochlea increased after application of the steroid. Another possible interpretation could be that the surgical procedure of preparation and opening of the bulla and placing the recording electrode already introduced a minor trauma to the inner ear. Application of the steroid might, as in the intracochlear group, have some rescuing effect on inner ear structures. Results from this first set of experiments clearly demonstrated absence of ototoxicity of the steroid for the substance, concentration and route of application that were used. Applying drugs onto the round window membrane has previously been shown to be a reliable route for the delivery of drugs to the inner ear. Nomura [20], Bachmann et al. [21] and Parnes et al. [13] using triamcinolone, dexamethasone, prednisolone-21-hydrogen succinate and hydrocortisone, respectively, demonstrated that corticosteroids permeate through the round window membrane into the perilymph and they reported success in the treatment of patients with sudden hearing loss [22, 23].

In the case of intracochlear application of steroid to the inner ear after a surgical trauma, hearing of animals decreased soon after cochleostomy in both groups. While hearing loss was initially similar in both groups, thresholds in the steroid group started to recover from the 7th day and returned close to the preapplication level on day 28, whereas recovery of thresholds in the control group did not reach the preapplication level on day 28. Possible reasons of hearing loss after cochleostomy may be loss of perilymph, acoustic trauma due to drilling noise, and inflammation due to surgical disturbance. In principle, perilymph loss should be stopped by sealing the opening of the cochleostomy and should be compensated spontaneously by cerebrospinal fluid, which reaches the cochlea via the open cochlear aqueduct. Influence of drilling noise on hearing can either be a temporal threshold shift, disappearing within a few hours to a week, or a permanent damage. Corticosteroids may contribute to related intracochlear

recovery processes associated with restoration of the auditory function by influence on carbohydrate metabolism, transcription of specific genes, as indicated by an increase in specific mRNAs, and influence on potassium turnover in the stria vascularis. Inflammation can severely impair the inner ear structure, if without effective control. It is well known that corticosteroids have a strong anti-inflammatory action, inhibiting the reactive processes of inflammation and scar tissue formation. In this study, recovery of hearing in the intracochlear steroid group may be partly attributable to the inflammation-inhibiting effect of steroid.

In recent years, more studies on apoptosis in the auditory system have been reported. It is agreed that any trauma associated with cochlear implant electrode insertion has the potential to form reactive oxygen species and to result in loss of auditory sensory cells through oxidative stress-induced apoptosis [24]. It is hypothesized that steroids may have the ability to block the initiating pathways of sensory cell apoptosis and inhibit the subsequent degeneration of the peripheral processes of the auditory neurons, thereby enhancing neural preservation for patients receiving cochlear implants.

In conclusion, results from this study indicated that topical application of steroid had no ototoxic effect and was able to rescue some cochlear functions in the guinea pig after trauma to the inner ear. Moreover, it was shown that corticosteroids can have a protective effect against damage of inner ear structures and hearing loss in stapes surgery. They were not able to prevent hearing loss but to increase recovery. There are indications that local application by direct instillation is more effective than diffusion via the round window and can avoid the side effect of systemic application. However, possible local effects, e.g. delayed healing, will have to be investigated.

References

- 1 Henry KR: Noise-induced auditory loss: influence of genotype, naloxone and methylprednisolone. *Acta Otolaryngol* 1992;112:599–603.
- 2 Michel O, Steinmann R, Walger M, Stennert E: Die medikamentöse Beeinflussung der Innenohrfunktion in einem neuen Lärmschädigungsmodell. *Otorhinolaryngol Nova* 1993;3:292–297.
- 3 Wang Y, Libermann MC: Restraint stress and protection from acoustic injury in mice. *Hear Res* 2002;165:96–102.
- 4 Lamm K, Arnold W: The effect of prednisolone and non-steroidal anti-inflammatory agents on the normal and noise-damaged guinea pig inner ear. *Hear Res* 1998;115:149–161.
- 5 Lamm K, Arnold W: Successful treatment of noise induced cochlear ischemia, hypoxia and hearing loss. *Ann NY Acad Sci* 1999;28:233–248.
- 6 Wilson WR, Byl FM, Laird N: The efficacy of steroids in the treatment of idiopathic sudden hearing loss: a double-blind clinical study. *Arch Otolaryngol* 1980;106:772–776.
- 7 Lamm K, Arnold W: How useful is corticosteroid treatment in cochlear disorders? *Otorhinolaryngol Nova* 1999;9:203–216.

- 8 Riechelmann H, Tholen M, Keck T, Rettinger G: Perioperative glucocorticoid treatment does not influence early post-laser stapedotomy hearing thresholds. *Am J Otol* 2000;21:809–812.
- 9 Hendershot EL: Corticosteroid therapy in stapedectomy: a clinical study. *Laryngoscope* 1974;84:1346–1351.
- 10 Spandow O, Anniko M, Hellström S: Hydrocortisone applied into the round window niche causes electrophysiological dysfunction of the inner ear. *ORL J Otorhinolaryngol Relat Spec* 1989;51:94–102.
- 11 Niedermeyer HP, Zahneisen G, Luppä P, Busch R, Arnold W: Cortisol levels in the human perilymph after intravenous administration of prednisolone. *Audiol Neurotol* 2003;8:316–321.
- 12 Tobita T, Senarita M, Hara A, Kusakari J: Determination of prednisolone in the cochlear tissue. *Hear Res* 2002;165:30–34.
- 13 Parnes LS, Sun AH, Freeman DJ: Corticosteroid pharmacokinetics in the inner ear fluids: an animal study followed by clinical application. *Laryngoscope* 1999;109:1–17.
- 14 Lefebvre P, Staecker H: Steroid perfusion of the inner ear for sudden sensorineural hearing loss after failure of conventional therapy: a pilot study. *Acta Otolaryngol* 2002;122:698–702.
- 15 Kopke RD, Hoffer ME, Weter D, O'Leary MJ, Jackson RL: Targeted topical steroid therapy in sudden sensorineural hearing loss. *Otol Neurotol* 2001;22:475–479.
- 16 Nordang L, Linder B, Anniko M: Morphologic changes in round window membrane after topical hydrocortisone and dexamethasone treatment. *Otol Neurotol* 2003;24:339–343.
- 17 Arriaga MA, Goldman S: Hearing results of intratympanic steroid treatment of endolymphatic hydrops. *Laryngoscope* 1998;108:1682–1685.
- 18 Karlidag T, Yalcin S, Ozturk A, Ustundag B, et al: The role of free oxygen radicals in noise induced hearing loss: effects of melatonin and methylprednisolone. *Auris Nasus Larynx* 2002;29:147–152.
- 19 Shirwany NA, Seidman MD, Tang W: Effect of transtympanic injection of steroids on cochlear blood flow, auditory sensitivity, and histology in the guinea pig. *Am J Otol* 1998;19:230–235.
- 20 Nomura Y: Otological significance of the round window, in Pfaltz CR (ed): *Advances in Oto-Rhino-Laryngology*. Basel, Karger, 1984, pp 63–71.
- 21 Bachmann G, Su J, Zumegegen C, Wittekindt C, Michel O: Permeability of the round window membrane for prednisolone-21-hydrogen succinate. Prednisolone content of the perilymph after local administration vs systemic injection. *HNO* 2001;49:538–542.
- 22 Chandrasekhar SS: Intratympanic dexamethasone for sudden sensorineural hearing loss: clinical and laboratory evaluation. *Otol Neurotol* 2001;22:18–23.
- 23 Hillman TM, Arriaga MA, Chen DA: Intratympanic steroids: do they acutely improve hearing in cases of cochlear hydrops? *Laryngoscope* 2003;113:1903–1907.
- 24 Scarpidis U, Madnani D, Shoemaker C, et al: Arrest of apoptosis in auditory neurons: implications for sensorineural preservation in cochlear implantation. *Otol Neurotol* 2003;24:409–417.

PD Dr. J. Kiefer

Klinik und Poliklinik für HNO-Heilkunde, Klinikum r.d. Isar der Technischen Universität München

Ismaninger Strasse 22

DE-81675 Munich (Germany)

Tel. +49 89 4140 2389, E-Mail J.Kiefer@lrz.tum.de