ONKOLOGIE

Original Article · Originalarbeit

Onkologie 2007;30:545–549
DOI: 10.1159/000108283

Published online: September 28, 2007

Breast Ductoscopy: Technical Development from a Diagnostic to an Interventional Procedure and Its Future Perspective

Volker R. Jacobs[a] Stefan Paepke[a] Ralf Ohlinger[b] Susanne Grunwald[b] Marion Kiechle-Bahat[a]

[a] Frauenklinik der Technischen Universität München,
[b] Frauenklinik, Ernst-Moritz-Arndt-Universität, Greifswald, Germany

Key Words
Ductoscopy: interventional, diagnostic, future technical development · Breast endoscopy · Breast duct procedure, diagnostic

Summary
Background: Endoscopy of the female breast, known as ductoscopy, is increasingly gaining acceptance as a diagnostic procedure worldwide. Recent technical development of ductoscopes and micro-instruments is shifting research interest from diagnostic to interventional ductoscopy. We describe novel technical aspects and the resulting possible future perspective of ductoscopy. **Methods:** This study comprised the analysis and review of new technical developments from research at the Technical University Munich, Germany, and others, as well as a review of the MEDLINE and COCHRANE databases for the keyword ductoscopy. **Results:** Diagnostic ductoscopy is performed by many breast physicians worldwide. Interventional ductoscopy, however, depends on an additional working channel and a variety of micro-instruments of 0.4–0.8 mm for procedures inside the breast duct. They are at present not available in the U.S. but are used in Germany and several other countries. Autofluorescence ductoscopy is a new imaging technique used on an experimental base for clinical evaluation to identify intraductal lesions. Laser ductoscopy for removal of intraductal papillomas and 3-dimensional intraductal tracking systems are future projects. **Conclusion:** Technical innovation and further miniaturization of instruments is supporting a change from diagnostic to interventional ductoscopy. A therapeutic intraductal approach as well as autofluorescence endoscopy could potentially eliminate unnecessary biopsies and offer better identification of intraductal lesions.

Schlüsselwörter
Duktoskopie: interventionelle, diagnostische, zukünftige technische Entwicklung · Milchgangsendoskopie · Milchgangsuntersuchung, diagnostische

Zusammenfassung
Hintergrund: Endoskopie der weiblichen Brust, bekannt als Duktoskopie, gewinnt zunehmende Akzeptanz als Diagnostikum weltweit. Neue technische Weiterentwicklungen von Duktoskopen sowie dazugehörigen Mikroinstrumenten richten das Forschungsinteresse von der diagnostischen auf die interventionelle Duktoskopie, die zum gegenwärtigen Zeitpunkt noch experimentell ist. Wir beschreiben diese neuartige technische Entwicklung und die daraus mögliche resultierende Zukunftsperspektive der Duktoskopie. **Methoden:** Die Studie umfasste die Analyse von und Übersicht über technische Neuentwicklungen in der Forschung an der Frauenklinik der Technischen Universität München und anderen Einrichtungen, sowie die Literaturanalyse aus MEDLINE und COCHRANE zum Stichwort Ductoscopy. **Ergebnisse:** Die rein diagnostische Duktoskopie wird von vielen Brustspezialisten weltweit durchgeführt. Die interventionelle Duktoskopie hingegen benötigt einen zusätzlichen Arbeitskanal und eine Auswahl von Mikroinstrumenten von 0.4–0.8 mm für Eingriffe innerhalb der Milchgänge. Solche Duktoskope gibt es gegenwärtig nicht in den USA, sie werden aber in Deutschland und in verschiedenen anderen Ländern eingesetzt. Die Autofluoreszenzduktoskopie ist eine neue Bildgebungstechnik im experimentellen klinischen Einsatz zur Identifizierung intraduktaler Läsionen. Die Laserduktoskopie zur Entfernung von intraduktalen Papillomen und dreidimensionale Tracking-Systeme sind Zukunftsprojekte. **Schlussfolgerung:** Die technische Neuentwicklung und weitere Miniaturisierung von Instrumenten unterstützt den Wandel von der diagnostischen zur interventionellen Duktoskopie. Der therapeutische, intraduktale Zugang sowie die Autofluoreszenzendoskopie könnten zukünftig unnötige Biopsien vermeiden und eine bessere Identifikation intraduktaler Veränderungen ermöglichen.

KARGER
Fax +49 761 4 52 07 14
E-mail Information@Karger.de
www.karger.com

Accessible online at:
www.karger.com/onk

PD Dr. med. Volker R. Jacobs, MBA
Oberarzt der Frauenklinik der
Technischen Universität München
Ismaninger Str. 22, 81675 München, Germany
Tel. +49 89 4140-5425, Fax -4831
E-mail volkerjacobs@hotmail.com

Introduction

The attention of breast physicians to ductoscopy as a rather new minimally invasive method has been rising recently with remarkable speed. Since its first publication in 1988 [1], ductoscopy developed slowly in the beginning but has escalated recently. The technique and clinical performance of ductoscopy in our institution has been comprehensively described before [2]. The use of a ductoscope (fig. 1) is easy; the setting for an ambulatory performance (fig. 2) does not require a sophisticated environment. Innovative endoscopy and medical instrument companies allow, in cooperation with specialized breast centers at universities and their excellent premises, to develop joint ideas into clinical applications and procedures, e.g. the development of the, at that time, world's smallest mini-ductoscope with a full working length of 75 mm but an outer diameter of only 0.5 mm [2]. Two German endoscopy companies manufacture autoclavable reusable metal ductoscopes of different sizes ranging from 0.5 to 1.3 mm in outer diameter [3, 4].

With the recent publication of several German case series from Munich [2], Greifswald [5], and Berlin [6], after only sporadic German publications for initial evaluation in the 1990s [7–10], a critical mass of users and promoters has been reached in Germany for the first time, which is necessary to implement and further develop this novel diagnostic and therapeutic technique on a broad base in larger centers nationwide. Several ductoscopy workshops as well as a multi-center trial for office-based physicians and hospital-based clinicians support training and ease the learning curve as well as the acceptance and consecutive adoption of this new procedure. We summarize here the latest technical developments of ductoscopy, related instrumentation, and intraductal imaging techniques.

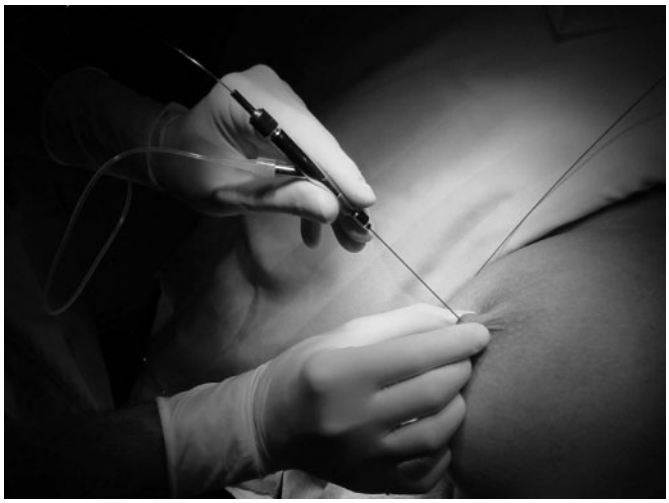

Fig. 1. Insertion of a ductoscope through the nipple.

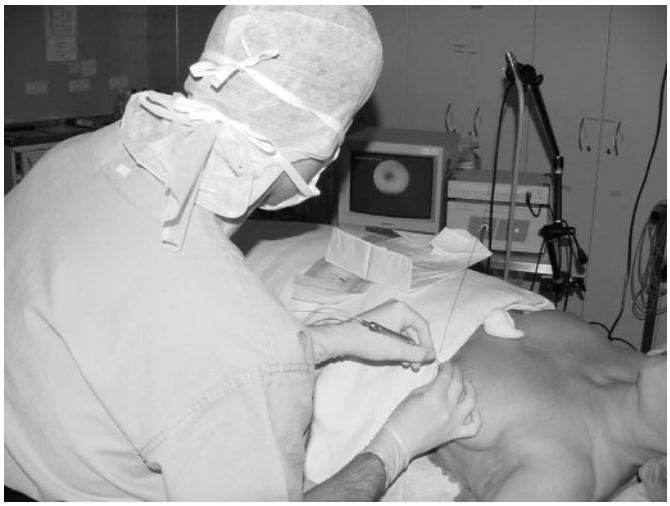

Fig. 2. Setting for ambulatory ductoscopy with normal intraductal walls on the monitor.

Methods

An analysis and review of new technical developments from research and clinical evaluation at the Technical University Munich and the Ernst-Moritz-Arndt-University of Greifswald (both Germany) and others, as well as a review of the MEDLINE database (*www.ncbi.nlm.nih.gov*) for the keyword ductoscopy including synonyms like breast duct microendoscopy were performed on March 25th 2007. A search of the COCHRANE database (*www.cochrane.org*) for the evaluation of ductoscopy under evidence-based medicine and randomized trial aspects was simultaneously performed.

Results

Up until March 25th 2007, only 66 papers were listed in a keyword search in MEDLINE for ductoscopy, 65 of them are about breast ductoscopy. A large number (33.8%) of them were listed as reviews (n = 22/65). For the keyword breast duct microendoscopy, another 2 scientific papers were found. Only very few publications mentioned or used an interventional ductoscope, or described interventional ductoscopy or instruments for intraductal interventions [2, 5, 10–12]. Ductoscopy as a new intraductal imaging technique has not yet been evaluated for the Cochrane Library.

From Diagnostic to Interventional Ductoscopy

In contrast to the U.S., technical development of ductoscopes in Germany at present is rather advanced. The reason is that, despite comprehensive clinical research and publications, ductoscopy has so far been primarily performed and used as a diagnostic method in the USA. In Germany, for several years interventional ductoscopes have been in use [10, 13, 14] which so far do not have an FDA approval for the U.S. market. An additional channel of ductoscopes of a U.S. manufacturer of only 0.35 mm [12] can be used for irrigation and ductal lavage but not in conjunction with micro-instruments of 0.4–0.8 mm. However, in Japan intraductal biopsy forceps were developed

and have been used for several years [15, 16]. In contrast to diagnostic ductoscopes, interventional ductoscopes offer a working channel with an inner diameter of up to 0.8 mm through which multiple newly developed as well as adopted or adjusted micro-instruments from gastrointestinal endoscopy can be used. Interventional ductoscopy allows for the first time intraductal access and use of different instruments under visual control, bringing conventional diagnostic ductoscopy to a completely new level with numerous therapeutic options. A variety of micro-instruments, e.g. a cytology brush of 0.4 mm in diameter for cytology retrieval of suspicious lesions under visual control [2, 11] or micro-biopsy forceps with an 0.8 mm diameter with a built-in optical system [14], are available so intraductal biopsies can also be performed under visual control. Thin marking wires of 0.4 mm can be used through the working channel either for a reversible or irreversible marking of intraductal areas of interest which later can be easily found after the ductoscope has been removed. Also, intraductal papillomas can be extracted with a thin titanium basket [17]. Further devices are an inlet guide introducer or the Soft Lumen Tissue Expander (SOLEX®, PolyDiagnost GmbH, Pfaffenhofen, Germany) for insertion support of instruments or the ductoscope especially helpful in case of an intraoperative exchange of ductoscopes. All these instruments and devices are currently either already in clinical use or under experimental evaluation [14, 17].

Autofluorescence Ductoscopy

But the development of ductoscopy is not limited to new instruments or procedures and techniques. Also, the endoscopic imaging technique is breaking new ground for intraductal visualization. As a result, autofluorescence ductoscopy as a new intraductal imaging technique was first described only recently [18]. A new type of autofluorescence ductoscope with a 30,000 pixel resolution has been developed [19] and is currently under experimental clinical investigation [20]. In contrast to standard white light endoscopy, the light source offers by the simple switch of a button the alternative of an autofluorescence mode [18]. Fluorescence light of a defined wave length is sent through the ductoscope into the breast ducts and is immediately reflected by body's own intraductal wall molecules: healthy tissue at a 100% reflection rate, altered or non-benign tissue at a reduced rate to nothing. So without modification, any intraductal lesions of interest and ductal wall changes could hardly be recognized. Only after inverting the picture and adding and cross-fading an additional picture from the blue-violet spectrum, additional visual intraductal information results which could allow a visual identification of early ductal wall alterations and possibly even ductal carcinoma in situ. From the initial development and application in bronchoscopy, a semi-quantitative visual evaluation of tissue dignity seems to be possible allowing the physician to instantly differentiate between benign and non-benign lesions during ductoscopy [20, 21]. Regarding the application of autofluorescence ductoscopy, these are preliminary experimental results at a very early stage of clinical evaluation, therefore evidence-based study results are not available at present. However, in bronchoscopy for which the autofluorescence technique has initially been developed [21, 22], it is already successfully in use and has resulted in the commercially available DAFE System (Diagnostische-Auto-Fluoreszenz-Endoskopie) [23].

Future Technology of Ductoscopy

A few papers are pointing towards future technical developments. Spectrally encoded endoscopy (SEE) is a step towards further miniaturization with just a single optical fiber of only 80–250 µm allowing 3-dimensional imaging [24]. The development of laser ductoscopy, e.g. for intraductal ablation of papillomas, seems to be technically feasible and is under consideration [25]. To eliminate visual-spatial orientation problems or difficulties finding back to previously identified intraductal lesions, 3-dimensional tracking systems – e.g. ultrasound supported – will be helpful and are likely to further reduce operating room time [26]. Confocal laser endomicroscopy could offer a further magnification of the in vivo cell architecture as well as being a subsurface imaging technique [27]. First results of conventional imaging techniques using helical computed tomography have been published to identify intraductal lesions [28, 29] allowing 3-dimensional intraductal imaging of lesions and their localization. Also, a combination of breast ductoscopy with standard conventional techniques like core needle biopsy or vacuum needle biopsy is possible and seems to improve histological results [30–32]. These options show a variety of experimental minimally invasive techniques which could increase the use of ductoscopy alone or in combination with other techniques for the diagnosis of suspicious nipple discharge.

Discussion

Present Place of Ductoscopy

In recent years, breast ductoscopy has been increasingly used worldwide as a new imaging technique for the evaluation of the breast duct and any potential intraductal lesions. The method is currently in continuing clinical evaluation comparing it to standard techniques as well as under ongoing technical development. First data show comparable results [6, 10, 32] but many questions remain and are waiting to be addressed [33]. Its final clinical value as well as its place in a comprehensive oncological concept or guidelines have yet to be determined. Based on published data, it should not yet be used to substitute the standard of care but as an additional and in parts even experimental innovative tool for breast diagnosis. But there is no doubt that ductoscopy with its related new technical innovations means a remarkably reduced diagnostic and operative invasiveness for patients compared to standard open breast biopsy or ductectomy.

Interventional Ductoscopy as an Example for 'Advanced' Ductoscopy

The concept of interventional ductoscopy as 'advanced' ductoscopy with the previously described micro-instruments and new imaging technology is currently under clinical evaluation. In its continuing technical development, clinical application, and evaluation in larger case series, it will have to confirm the initial promising results.

Ductoscopy under Evidence-Based Medicine and Randomized Controlled Trial Aspects

Unsurprisingly and due to the fact that ductoscopy is an evolving new method, it has not yet been evaluated for the Cochrane Library. Although there is a continuing trend worldwide that every single application of any medical diagnostic and therapeutic method has to be evidence-based proven preferably in randomized controlled trials before its initial use, for ductoscopy there are currently no such option and data available. On the contrary, this demand would lead to a prolonged evaluation process and delay clinical application in hospitals who would be left alone with the costs of the technical development of a novel minimally invasive technique. Since in our experience as well as documented in the published literature, very limited to no adverse side effects or complications have been seen so far with the application of ductoscopy, colleagues can be encouraged to use this technique at present as an additional diagnostic method after appropriate informed consent and parallel to a standard care treatment protocol. Breast ductoscopy is a promising new method [34] but based on today's experience it is too early to determine its final value and significance or even to declare it prematurely as standard of care.

Reimbursement for Ductoscopy

At present, reimbursement is not possible in Germany because ductoscopy has not yet been coded, and private payment by patients for non-standard diagnostic procedures is not established. At the German Institut für das Entgeltsystem im Krankenhaus (InEK; Institute for Payment in Hospitals), an additional payment for ductoscopy as a New Diagnostic Method (NUB) was applied for in 2005 and 2006, which can apparently not be reflected in a retrospectively calculated reimbursement system such as the German DRG system. Disappointingly, it was categorized twice as Level 2 and therefore currently does not qualify for additional payment negotiations with German compulsory health insurances. However, in the U.S., private payment for ductoscopy is possible and accepted and is currently the reimbursement of choice there. But before upfront rejecting payment for ductoscopy as a non-established and unproven method [35], health insurances should bear in mind that diagnostic as well as interventional breast ductoscopy can not only be much cheaper than open breast biopsy but also means less invasiveness for the patient with all its advantages for the health care system and the entire society.

Conclusion

Breast ductoscopy is a novel and so far the only visual intraductal approach to directly identify breast duct lesions. Technical development of a variety of micro-instruments and further miniaturization are supporting the current change from diagnostic to interventional ductoscopy. However, ongoing clinical evaluation as well as further trials and clinical data have to continue to confirm the expectations of its developers and early adopters. The therapeutic intraductal approach combined with autofluorescence ductoscopy might be able to eliminate unnecessary biopsies and offer better identification of any intraductal lesions. New and novel technical innovations are currently under development which could have remarkable impact on diagnostics and therapeutic options of breast endoscopy in the not too distant future.

References

1 Teboul M: A new concept in breast investigation: echo-histological acino-ductal analysis or analytic echography. Biomed Pharmacother 1988;42: 289–295.

2 Jacobs VR, Kiechle M, Plattner B, Fischer T, Paepke S: Breast ductoscopy with a 0.55-mm mini-endoscope for direct visualization of intraductal lesions. J Minim Invasive Gynecol 2005;12:359–364.

3 PolyDiagnost GmbH: *www.polydiagnost.com*; March 25th 2007.

4 Karl Storz GmbH: *www.karlstorz.de*; March 25th 2007.

5 Grunwald S, Bojahr B, Schwesinger G, Schimming A, Kohler G, Schulz K, Ohlinger R: Mammary ductoscopy for the evaluation of nipple discharge and comparison with standard diagnostic techniques. J Minim Invasive Gynecol 2006;13:418–423.

6 Hunerbein M, Raubach M, Gebauer B, Schneider W, Schlag PM: Intraoperative ductoscopy in women undergoing surgery for breast cancer. Surgery 2006;139:833–838.

7 Heywang-Kobrunner SH: Nonmammographic breast imaging techniques. Curr Opin Radiol 1992; 4:146–154.

8 Rimbach S, Wallwiener D, Fein A, von Fournier D, Bastert G: Experimentelle Mikroendoskopie des Milchgangssystems (Duktoskopie). [Experimental microendoscopy of the milk duct system (ductoscopy)]. Zentralbl Gynakol 1995;117:198–203.

9 Keckstein J, Tuttlies F, Ulrich U: Galaktoskopie – eine neue Methode zur Evaluierung des Milchganges. [Galactoscopy – a new method for evaluation of milk ducts.] Arch Gynecol Obstet 1994; 255(suppl 1):S57.

10 Schulz-Wendtland R, Aichinger U, Kramer S, Schaaf H, Tartsch M, Bautz W: Galactoscopy – is it a new interventional method for breast diagnosis? Rofo 2002;174:1015–1017.

11 Beechey-Newman N, Kulkarni D, Kothari A, D'Arrlgo C, Culora G, Hamed H, Fentiman I: Breast duct microendoscopy in nipple discharge: microbrush improves cytology. Surg Endosc 2005; 19:1648–1651.

12 Kothari A, Beechey-Newman N, Kulkarni D: Breast duct micro-endoscopy: a study of technique and a morphological classification of endo-luminal lesions. Breast 2006;15:363–369.

13 Jacobs VR, Kiechle M, Schaaf H, Paepke S: Initial experience with breast ductoscopy: a 0.55 mm micro-endoscope for direct visualization of intraductal lesions. JSLS 2004;8:S65-S66.

14 Jacobs VR, Kiechle M, Schaaf H, Paepke S: Interventionelle Duktoskopie. [Interventional ductoscopy.] Endoskopie heute 2006;19:45.
15 Nagase J, Endo M: Endoscopic biopsy in the intraductal lesions of the breast for the mammary duct fiberscope. Jpn J Breast Cancer 1995;10:405–409.
16 Matsunaga T, Ohta D, Misaka T, Hosokawa K, Fujii M, Kaise H, Kusama M, Koyanagi Y: Mammary ductoscopy for diagnosis and treatment of intraductal lesions of the breast. Breast Cancer 2001; 8:213–221.
17 Jacobs VR, Euler U, Grunwald S, Ohlinger R, Fischer T, Kiechle M, Paepke S: Moving forward with breast endoscopy: From diagnostic to interventional ductoscopy. JSLS 2006;10(3 suppl):S10.
18 Jacobs VR, Paepke S, Schaaf H, Weber BC, Kiechle-Bahat M: Autofluorescence ductoscopy: a new imaging technique for intraductal breast endoscopy. Clin Breast Cancer 2007;7:619–623.
19 Jacobs VR, Schaaf H, Weber BC, Kiechle M, Paepke S: Auto fluorescence ductoscope: a new instrument for in vivo detection of intraductal malignancies in the breast. J Minim Invasive Gynecol 2005: 12(suppl 1):S91-S92.
20 Jacobs VR, Kiechle M, Schaaf H, Weber BC, Paepke S: Auto fluorescence ductoscopy for semi-quantitative visual differentiation of intraductal breast lesions. Breast Cancer Res Treat 2006;100(suppl 1): S45.
21 De Veld DC, Skurichina M, Witjes MJ, Duin RP, Sterenborg HJ, Roodenburg JL: Clinical study for classification of benign, dysplastic, and malignant oral lesions using autofluorescence spectroscopy. J Biomed Opt 2004;9:940–950.
22 Goujon D, Zellweger M, Radu A, Grosjean P, Weber BC, van den Bergh H, Monnier P, Wagnieres G: In vivo autofluorescence imaging of early cancers in the human tracheobronchial tree with a spectrally optimized system. J Biomed Opt 2003;8: 17–25.
23 Richard Wolf GmbH: DAFE System; *www.richard-wolf.com/Modules/Documents/Document.aspx?DocumentId=1666&NavigationItemId=3162*; accessed March 25th 2007.
24 Yelin D, Rizvi I, White WM, Motz JT, Hasan T, Bouma BE, Tearney GJ: Three-dimensional miniature endoscopy. Nature 2006;443:765.
25 Jacobs VR, Schaaf H, Weber BC, Kiechle M, Paepke S: Autofluoreszenzduktoskopie als neue Methodik zur semiquantitativen Dignitätsbeurteilung intraduktaler Läsionen. Geburtshilfe Frauenheilkd 2006;66(suppl 1):S9.
26 Hunerbein M, Raubach M, Eulenstein S, Lange T, Schlag PM: Ductoscopic biopsy and ductoscopy navigated minimal invasive therapy of intraductal breast lesions. 5th International Symposium on the Intraductal Approach to Breast Cancer, Santa Monica, CA, USA, March 1st–4th 2007.
27 Hoffman A, Goetz M, Vieth M, Galle PR, Neurath MF, Kiesslich R: Confocal laser endomicroscopy: technical status and current indications. Endoscopy 2006;38:1275–1283.
28 Matsuda M, Seki T, Kikawada Y, Isaka H, Teraoka H, Fukushima H, Goya T: Mammary ductoscopy by helical CT: initial experience. Breast Cancer 2005;12:118–121.
29 Matsuda M, Nakayama E, Itou H, Isaka H, Goya T: Mammary ductoscopy by helical CT: initial experience. Breast Cancer Res Treat 2006;100(suppl 1): S45.
30 Hunerbein M, Raubach M, Gebauer B, Schneider W, Schlag PM: Ductoscopy and intraductal vacuum assisted biopsy in women with pathologic nipple discharge. Breast Cancer Res Treat 2006;99: 301–307.
31 Hunerbein M, Estevez Schwarz L, Schneider U, Schlag PM: Evaluation of pathologic nipple discharge with ductoscopy. J Am Coll Surg 2003;197: 697–698.
32 Grunwald S, Heyer H, Paepke S, Schwesinger G, Schimming A, Hahn M, Thomas A, Jacobs VR, Ohlinger R: Diagnostic value and feasibility of ductoscopy in the diagnosis of nipple discharge and intraductal proliferations in comparison to standard methods. Onkologie 2007;30:243–248.
33 Dooley WC: Who wants a blind breast surgeon? Ann Surg Oncol 2006 (Epub ahead of print), online May 18th 2006.
34 Ohlinger R, Paepke S, Jacobs VR, Hahn M, Grunwald S: Stellenwert der Duktoskopie in der Mammadiagnostik. [The value of ductoscopy in breast diagnostics.] Gynakologe 2006;39:538–544.
35 CIGNA HealthCare: CIGNA HealthCare Coverage Position 0057: Mammary Ductoscopy (MD). CIGNA HealthCare, Philadelphia, PA, USA, revision from February 15th 2007. Website accessed on June 30th 2007. *www.cigna.com/customer_care/healthcare_professional/coverage_positions/medical/mm_0057_coveragepositioncriteria_ductoscopy.pdf*