

## REVIEW

# Image-based response assessment during immunotherapy in skin cancer

Kristine E. Mayer<sup>1</sup> | Jochen Gaa<sup>2</sup> | Tilo Biedermann<sup>1</sup> | Christian Posch<sup>1,3</sup>

<sup>1</sup>Clinic and Polyclinic for Dermatology and Allergology, Technical University Munich, Munich, Germany

<sup>2</sup>Institute for Diagnostic and Interventional Radiology, Technical University Munich, Munich, Germany

<sup>3</sup>Faculty of Medicine, Sigmund Freud University Vienna, Austria

**Correspondence**

Kristine E. Mayer, Clinic and Polyclinic for Dermatology and Allergology, Technical University Munich, Biedersteiner Strasse 29, 80802 München, Germany.  
Email: [kristine.mayer@tum.de](mailto:kristine.mayer@tum.de)

**Summary**

Immune-checkpoint inhibitors and further immunotherapeutic treatment strategies have significantly extended therapy options for melanoma and other skin cancer entities over the last decade. In the context of a broader application of immunotherapeutic approaches, sufficient ways to monitor the course of the disease during therapy are required. Immunotherapies are based on different ways of modulating the immune system. This leads to complex clinical response patterns including pseudoprogression and others, requiring an adaptation of conventional diagnostic imaging tools or the introduction of novel technologies. In this review, current non-invasive imaging approaches for response assessment during immunotherapies in skin cancers as well as their limitations are discussed. To overcome present hurdles, promising alternatives to better address novel imaging features during immunotherapy are depicted giving an outlook on what can be expected in the future.

**INTRODUCTION**







Over the past decades, immunotherapies have advanced treatment options of various dermatological tumors. First, adoptive T-cell transfer (ACT) was shown to be effective in some melanoma patients in the early 1980s,<sup>1</sup> already providing an outlook on the immunotherapeutic revolution initiated by the approval of the anti-CTLA-4-directed ipilimumab and further immune-checkpoint-inhibitors with other target structures such as PD-1 and PD-L1. Beside melanomas, immune-checkpoint inhibition (ICI) has been successfully applied for other skin cancers such as squamous cell carcinoma, Merkel cell carcinoma and lately basal cell carcinoma.<sup>2</sup> The field of clinically established immunotherapeutic approaches is completed by the oncolytic virus T-Vec which leads to an indirect stimulation of an immune response (Figure 1).<sup>3</sup>

However, the development of suitable diagnostic methods could not keep up with the rapid progression of these new therapeutic concepts. Conventional imaging approved in the context of chemo- and radiotherapy is

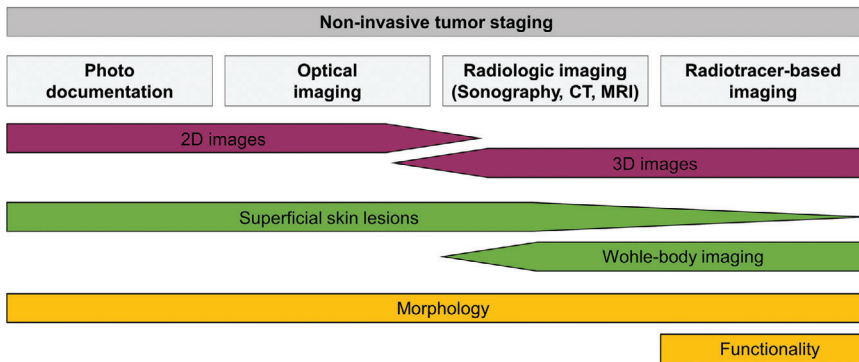
not able to reliably assess therapeutic response in all cases, much less predict it in advance.<sup>4</sup> For this reason, clinicians are often forced to conduct diagnostic biopsies. Hereby especially fine-needle aspiration (FNA) biopsy is often a reasonable approach.<sup>5</sup> Biopsies can give precise insights into the composition of the tumor with its stromal reaction, tumor microenvironment as well as a possible immune infiltrate. Furthermore, the tissue can be analyzed for genetic and epigenetic alterations which may have therapeutic implications or indicate therapy response.<sup>6</sup> While in the beginning surgical resections are also conducted for therapeutic reasons, in the course of a disease the diagnostic value goes beyond its therapeutic one. Respectively, less invasive methods would be desirable, particularly in view of the fact that results from one biopsy may not provide a holistic picture of heterogeneous tumor metastases. In this review, we depict current non-invasive imaging approaches for response assessment of immunotherapies in skin cancer, discuss their current limitations and give an outlook on potential future technologies.

This is an open access article under the terms of the [Creative Commons Attribution-NonCommercial-NoDerivs License](https://creativecommons.org/licenses/by-nc-nd/4.0/), which permits use and distribution in any medium, provided the original work is properly cited, the use is non-commercial and no modifications or adaptations are made.

© 2023 The Authors. *Journal der Deutschen Dermatologischen Gesellschaft* published by John Wiley & Sons Ltd on behalf of Deutsche Dermatologische Gesellschaft.

Melanoma	NMSC
 <b>Immune-checkpoint inhibition</b> Nivolumab (anti-PD-1) Pembrolizumab (anti-PD1) Ipilimumab (anti-CTLA-4) <i>Relatlimab (anti-LAG-3)*</i>	 <b>Basal cell carcinoma</b> Cemiplimab (anti-PD-1)
 <b>Oncolytic virus</b> Talimogen laherparepvec (T-VEC)	 <b>Cutaneous squamous cell carcinoma</b> Cemiplimab (anti-PD-1) Pembrolizumab (anti-PD-1)
 <b>Adoptive T-cell transfer</b> TCR-modulated T cells	 <b>Merkel cell carcinoma</b> Avelumab (anti-PD-L1) Pembrolizumab (anti-PD-1)

**FIGURE 1** Overview on immunotherapeutic options for melanoma and other non-melanoma skin cancer (NMSC) entities. \*FDA-approval in combination with nivolumab since March 2022.



**FIGURE 2** Modalities of non-invasive tumor staging in dermato-oncology with their relevant characteristics. They include photodocumentation, optical imaging, radiologic imaging such as sonography, CT and MRI as well as radiotracer-based imaging. The methods differ concerning their spatial depiction (purple), their suitable target structures (green) and their underlying methodological concept (morphology- and functionality-based approaches) explaining their respective advantages and disadvantages.

## THE ONCOLYTIC VIRUS T-VEC

To date, Talimogene laherparepvec (T-Vec) is the only approved oncolytic virus for the treatment of locally unresectable melanoma (without distant disease). Human herpes simplex virus is genetically modified to preferentially replicate in tumor cells and induce apoptosis.<sup>3</sup> Tumor cell death causes the release of tumor antigens triggering and stimulating immune cell recruitment leading to further tumor cell lysis.<sup>3</sup> T-Vec is injected locally at the melanoma tumor site or into skin and lymph-node metastases and is able to induce a high rate of durable complete responses.<sup>7</sup> Because of the good visibility on the skin surface, response evaluation by photo documentation and ultrasound is feasible (Figure 2).<sup>7</sup> Additionally, optical imaging approaches including optoacoustic imaging may contribute to a more detailed evaluation of treatment response.<sup>8</sup> However, in optoacoustic imaging in particular differentiation between melanophages and melanoma cells post-treatment may be difficult to assess potentially leading to misinterpretations.<sup>9</sup> Moreover, for deeper lesions conventional radiologic imaging such as computed tomography (CT) is needed. For functional information it should be combined with an additional radiotracer-based imaging method such as positron emission tomography (PET) as discussed below (Figure 2).

## RESPONSE PATTERNS IN ICI

ACT and ICI both cause tumor cell destruction through T-cell-mediated immune responses. While ACT is mainly used in studies for late-stage melanoma patients, ICI is recommended for patients with malignant melanoma TNM-classified as N1a or distant disease. Immune-checkpoint inhibition is also approved in late-stage squamous cell carcinoma, Merkel-cell carcinoma and basal cell carcinoma.<sup>2</sup> Response patterns are best characterized for ICI-treated melanomas because of longer clinical experience.

Treatment response may vary significantly reaching from durable to no response at all.<sup>10</sup> While response to conventional therapies like chemo- or radiotherapy is mainly classified as no (progressive disease), partial or complete response, practitioners observe durable responses, pseudoprogression, hyperprogression, and mixed responses as common response patterns with ICI.<sup>11</sup>

Pseudoprogression describes an initial increase in the detected tumor volume related to an enhanced immune infiltrate followed by tumor shrinkage over time.<sup>12</sup> Some patients even experience delayed pseudoprogression which is defined as an increase in tumor burden of at least 25% first detected at least twelve weeks after therapy initiation and not confirmed in the following imaging.<sup>13</sup> In total, the phenomenon of pseudoprogression is assumed

to occur in about 10% of ICI-treated melanomas which is a small, but relevant number.<sup>14</sup>

Hyperprogression is a phenomenon more often observed in elderly patients receiving ICI, which leads to the development of rapid tumor progression upon the application of immune-checkpoint inhibitors.<sup>15</sup>

In some cases, response may vary for different metastases typically referred to as mixed response.<sup>16</sup> In a retrospective study including 292 patients with metastatic melanoma mixed responses were followed by response in 56% of cases.<sup>16</sup>

## MORPHOLOGY-BASED IMAGING

To reliably evaluate therapy response in oncology, different methods are usually combined (Figure 2). Sonography is a simple tool to quickly estimate the dignity of a suspect lesion, by assessing its morphology and perfusion. It is a point-of-care method, easy and cost-effective. Furthermore, it can be employed for FNA which can increase diagnostic accuracy using e. g. cytomorphological as well as molecular tools.<sup>5</sup> However, clinical experience is needed which may influence the reliability of results. Computed tomography is the standard diagnostic tool, while magnetic resonance imaging (MRI) is preferentially used to visualize the brain, head and soft tissues. Independent of the underlying physical principle, morphological criteria are used to determine the dignity of suspect lesions. Therapy response is then categorized by the change in tumor size and shape on consecutive scans.

The *Response Evaluation Criteria in Solid Tumors* (RECIST) serve as instructions to evaluate therapeutic response after conventional oncologic therapies.<sup>17</sup> Here, progression is defined by an increase in size or number of malignant lesions. However, since immune-based therapies do not lead to direct tumor damage, but induce an immune response causing indirect effects on the morphology of cancerous lesions, this method is less suitable to evaluate response to ICI. An enhanced immune infiltrate can at first lead to an increase in lesions-size before the actual antitumoral effects become evident. This may lead to the assumption of disease progression which may trigger false therapeutic decisions.<sup>13,14</sup> Therefore, the tumor volume is no longer a reliable parameter to assess therapy response. This led to the development of „immune RECIST“ (iRECIST).<sup>4</sup> Here, a single increase in size of a known tumor lesion does no longer define tumor progression.<sup>4</sup> Instead, it has to be confirmed by an additional examination.

In a meta-analysis conducted by Park and colleagues superiority of iRECIST in comparison to RECIST 1.1 was proven concerning progression-free survival.<sup>18</sup> For overall response and disease control rate, however, no substantial differences were detected.<sup>18</sup> Even though here mostly patients with non-small cell lung cancer were examined and only one of the eleven studies explicitly included melanoma, it may be assumed that the results are trans-

ferable to other cancer entities. The results of Park and colleagues are in line with findings from a pooled FDA analysis stressing the benefit of iRECIST especially in the small subgroup of patients with pseudoprogression.<sup>19</sup> However, prospective studies about iRECIST in general and especially studies focusing on melanoma and other skin cancers are currently lacking.

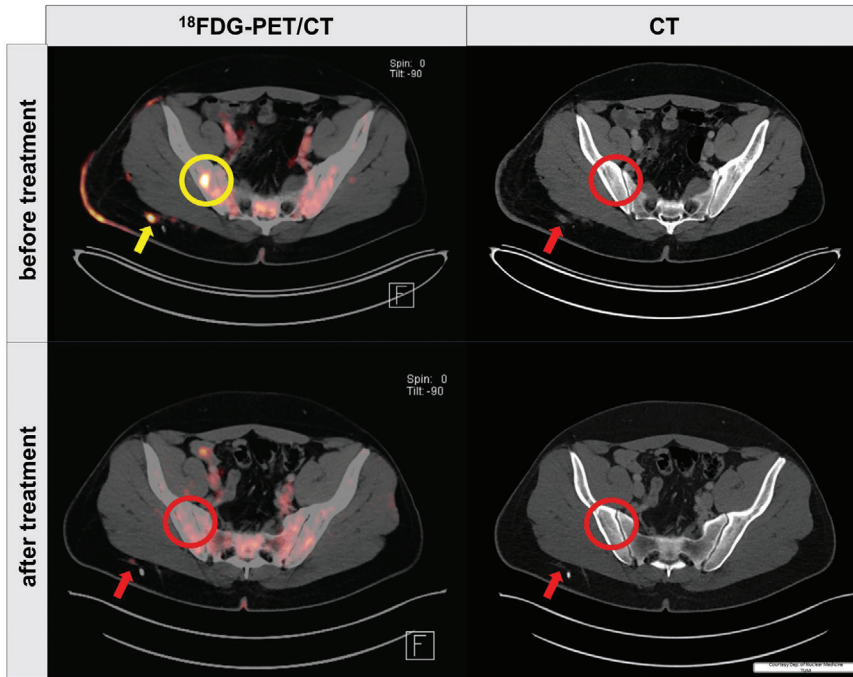
In the context of melanoma treatment with ipilimumab, alternative response criteria have been introduced based on the WHO criteria.<sup>20</sup> In contrast to (i)RECIST where each lesion is evaluated independently, these immune-related response criteria (irRC) assess all lesions in sum.<sup>20</sup> When the criteria were applied on patients with advanced melanoma treated with a PD-1 antibody, a comparison of RECIST v1.1 and irRC showed an underestimation of response in around 15% by RECIST v1.1.<sup>13</sup>

## FUNCTIONALITY-BASED IMAGING: FDG-PET IMAGING

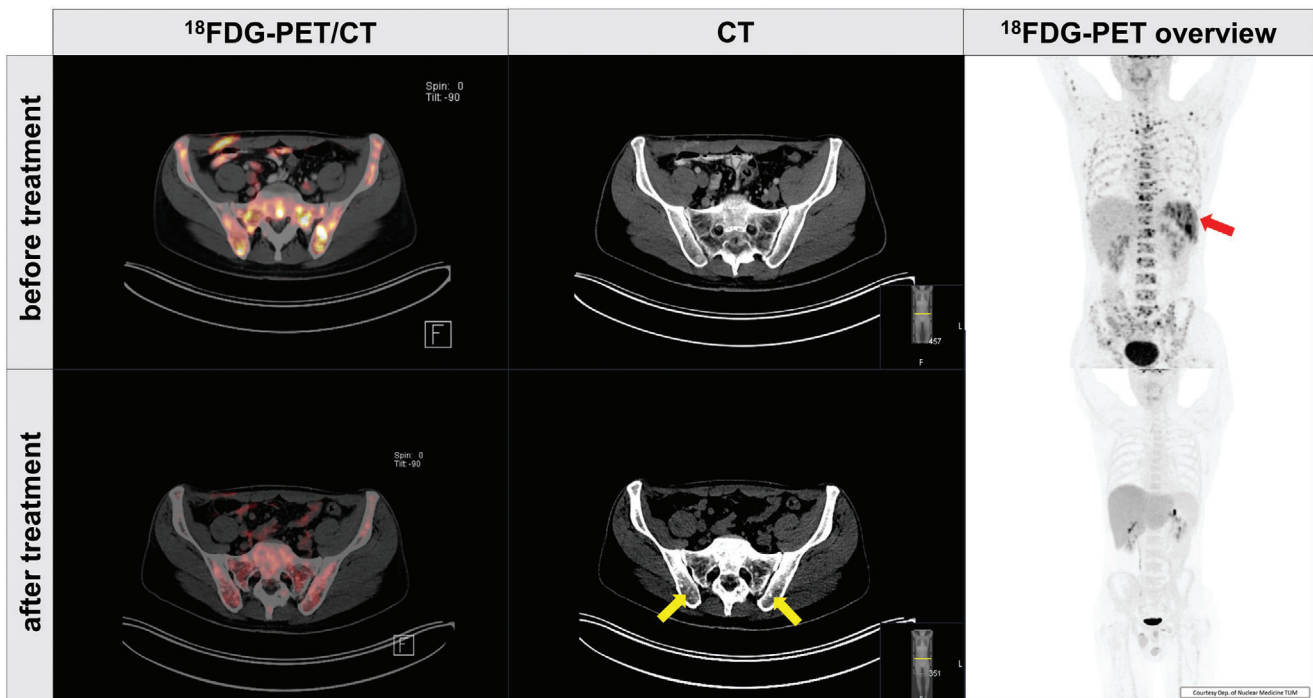
Computed tomography, MRI and sonography are morphology-based imaging strategies. However, especially in the context of immunotherapies the composition and distribution of the immune infiltrate in the tumor have great impact on therapy response.<sup>21</sup> Like that, the distribution of T cells in the tumor and its periphery determines the therapeutic outcome.<sup>22</sup> Functional imaging e. g. with PET combines the advantages of functional characterization and spatial information. Promising PET-based methods for immunotherapeutic response assessment include the clinically applied Fluor-18-Deoxyglucose (<sup>18</sup>FDG)-PET, but also novel technologies such as immuno-PET and reporter gene-based imaging.

<sup>18</sup>FDG-PET visualizes metabolic activity as a correlate of glucose uptake. Because of this favorable characteristic, it is far more sensitive in the detection of metastases in generally, but especially in the context of bone metastases, compared to CT scans only (Figures 3, 4). During immunotherapeutic treatment, the criteria from the *European Organization for Research and Treatment of Cancer* (EORTC),<sup>23</sup> or the *PET Response Evaluation Criteria in Solid Tumors* (PERCIST),<sup>24</sup> can be applied to assess therapy response (Figures 3, 4). However,<sup>18</sup>FDG-PET identifying highly metabolically active regions reaches its limits since not only the tumor but also the immune infiltrate shows high glucose uptake.<sup>25</sup> Like that, especially the identification of immune-related phenomena such as pseudoprogression poses a challenge.<sup>13</sup>

Aiming to reliably identify clinical benefit from ICI also in patients with unclear response, Cho and colleagues proposed to use a two-step analysis of PET/CT scans 3–4 weeks after the beginning of treatment to best categorize response three months later.<sup>25</sup> RECIST 1.1 criteria should be applied to distinguish complete or partial response from stable and progressive disease.<sup>25</sup> For the subgroup of patients with stable disease PERCIST criteria should be used



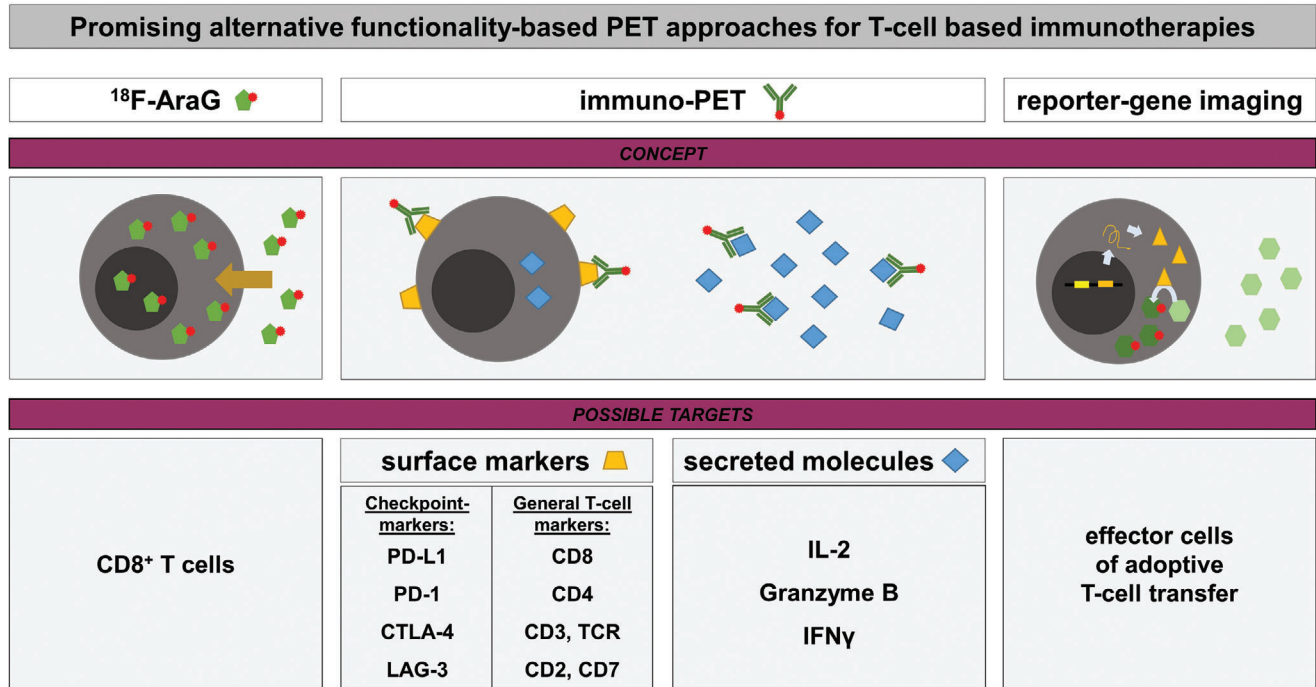
**FIGURE 3**  $^{18}\text{F}$ FDG-PET/CT scans and single CT scans of a 31-year-old patient with metastatic melanoma before and after treatment with two immune-checkpoint inhibitors (ipilimumab and nivolumab).  $^{18}\text{F}$ FDG-PET/CT is able to detect a CT-occult bone metastasis before therapy start (yellow circle). Corresponding areas on the other scans are marked with red circles. Besides, an intensified  $^{18}\text{F}$ FDG uptake was detected in a subcutaneous metastasis as well as satellite metastases (yellow arrow). Compared to CT alone,  $^{18}\text{F}$ FDG-PET/CT scans facilitate response evaluation. During the course of the immunotherapy the  $^{18}\text{F}$ FDG-avid metastases were no longer detectable indicating excellent response.



**FIGURE 4**  $^{18}\text{F}$ FDG-PET/CT scans, single CT scans and  $^{18}\text{F}$ FDG-PET overview of a 38-year-old patient with metastatic melanoma. Multiple osseous metastases are visible on  $^{18}\text{F}$ FDG-PET, but not on CT scans (upper row) before treatment. Furthermore, metastases in the spleen could be detected (red arrow). After treatment with immune-checkpoint inhibitors, follow-up scans (lower row) confirm a complete remission with sclerotic changes in the place of former osseous metastases (yellow arrows).

to differentiate patients with and without a clinical benefit by a threshold in change of tracer uptake.<sup>25</sup> However, others showed that the number of newly occurred  $^{18}\text{F}$ FDG-avid lesions on PET/CT scans after four cycles of anti-CTLA-4 inhibitor treatment in patients with metastatic melanoma seems to be a more sensitive predictor for clinical ben-

efit than the comparison of the lesional tracer uptake.<sup>26</sup> Anwar and colleagues therefore propose a cut-off of four newly detected lesions on posttreatment PET/CT scans indicating treatment failure.<sup>26</sup> Interestingly, the larger the lesions are, the lower number of new lesions is required.<sup>26</sup> Based on these findings, *PET Response Evaluation Criteria*



**FIGURE 5** Overview on alternative functionality-based PET technologies for T-cell based immunotherapies. Promising concepts include (1) other metabolic tracers apart from  $^{18}\text{F}$ FDG such as Fluor-18-arabinofuranosylguanine ( $^{18}\text{F}$ -AraG) which preferentially accumulates in activated CD8<sup>+</sup> T cells (left), (2) immuno-PET using highly antigen-specific antibodies or their constructs to target either surface markers or secreted molecules (middle) and (3) reporter-gene imaging which may be applied when genetically modified cells are transferred for therapy (right). Possible targets in the context of T-cell-based immunotherapies are shown in the lower row.

for Immunotherapy (PERCINT) were introduced providing a better estimation of the progression-free survival when compared to the EORTC criteria.<sup>27</sup>

Furthermore, there is evidence that  $^{18}\text{F}$ FDG-PET is capable of detecting immunotherapeutic responses in melanoma patients at an early time point as soon as two weeks after therapy start.<sup>27,28</sup> However, the clinical practicability is doubtful, not to mention the radiation exposure when taking into consideration that late responders cannot be identified in this case.

All these efforts are based on the idea that an early identification of immunotherapeutic treatment responses can help prevent unnecessary treatments of patients not benefiting from the therapy. At the same time, patients potentially benefiting from therapy at later time points should not be missed.

This approach includes the assumption that an early discontinuation can impede immune-related adverse effects what might not always be the case. For this reason, response prediction from imaging even prior to treatment is highly desirable. On retrospectively analyzed  $^{18}\text{F}$ FDG-PET scans from patients with metastatic melanoma later responders showed higher tracer uptake in the bones, with a predominance in the axial bones, compared to non-responders.<sup>29</sup> Besides, a meta-analysis showed that measurable PET/CT values in tumors before treatment such as peak standardized uptake value, metabolic tumor volume or total lesion glycolysis rate may indicate response to

immunotherapy.<sup>30</sup> However, no general surrogate parameter could be identified so far,<sup>30</sup> what may require alternative methods.

## ALTERNATIVE FUNCTIONALITY-BASED PET APPROACHES

To overcome the issue of differentiating both metabolically active cell compartments, tumor and immune cells, more suitable imaging modalities and alternative substrates with higher specificity in the immunotherapeutic context should be identified. There is a bunch of alternative functionality-based PET approaches for T-cell based immunotherapies based on different concepts and possible target structures (Figure 5).

Fluor-18-arabinofuranosylguanine ( $^{18}\text{F}$ -AraG), for example, preferentially accumulates in activated CD8<sup>+</sup> T cells.<sup>31</sup>  $^{18}\text{F}$ -AraG seems to be especially suitable since the presence of CD8<sup>+</sup> T cells in the tumor and at its rim is an approved biomarker for immune checkpoint blockade induced therapy response.<sup>22,32</sup> To our knowledge,  $^{18}\text{F}$ -AraG imaging in an immunotherapeutic setting with an anti-PD-1 directed therapy has only been conducted in a rhabdomyosarcoma mouse model so far.<sup>31</sup> Even though data are preclinical and have not been tested in melanoma patients, investigations are promising showing that particularly the signal detected in the tumor-draining

lymph nodes may be a predictive parameter for therapy response.<sup>31</sup>

Apart from metabolic tracers such as <sup>18</sup>F-DG and <sup>18</sup>F-AraG, CD8<sup>+</sup> T cells as surrogate markers may be visualized by novel imaging methods such as immuno-PET (Figure 5). For immuno-PET, antibodies or antibody-derived molecules are labelled with respective radionuclides. Thereby, the high target specificity of an antibody is combined with the advantages of PET imaging.<sup>33</sup> In fact, there are pre-clinical reports about the visualization of CD8<sup>+</sup> T cells in immunotherapeutic settings.<sup>34</sup> Rashidian and colleagues could show that immuno-PET of CD8<sup>+</sup> T cells in a mouse model is able to predict therapeutic response by analyzing the signal distribution,<sup>34</sup> as expected from clinical experience.<sup>22</sup> Lately, the safe and successful application of an anti-CD8 directed minibody in a phase 1 study has been reported.<sup>35</sup> The study also included patients suffering from advanced melanoma treated with immunotherapy and showed for some patients an increase of tracer uptake in tumors after therapy correlating with response.<sup>35</sup>

Besides tumor infiltrating CD8<sup>+</sup> T cells, the tumoral mutational load and the expression of PD-L1 are further biomarkers indicating response to immunotherapy in general,<sup>32</sup> even though low expression of PD-L1 in melanoma does not exclude therapy response.<sup>36</sup> In the context of skin cancer, PD-L1 expression has been visualized by immuno-PET in a melanoma mouse model.<sup>37</sup> Besides, anti-PD-L1 immuno-PET reagents have even been tested in clinical studies including stage IV melanoma patients.<sup>38</sup> Hereby, the investigators observed a correlation between high lesional baseline uptake of their tracer corrected for the blood pool uptake and the immunotherapeutic response.<sup>38</sup>

Alternative image-based approaches focus on other immune-checkpoint-related surface molecules or target-independent T-cell markers either only expressed on certain subpopulations such as CD4 or generally on T cells expressed such as CD3, CD2, CD7 or the T-cell receptor (TCR).

Immune-checkpoint-related target structures may include CTLA-4, PD-1 and LAG-3.<sup>39,40</sup> They harbor therapeutic potential because they cannot only be applied in a diagnostic setting but also for therapy. Simultaneously, such approaches may help to better understand the pharmacokinetics of clinically administered immunotherapeutic drugs as exemplarily shown in a humanized melanoma mouse model.<sup>39</sup> However, respective antibody-based agents are so far only tested preclinically. Apart from immune-checkpoint molecules, CD4 may be a reasonable target to visualize responses in the context of immunotherapies,<sup>41</sup> even though it has not yet been investigated in an immunotherapeutic setting as far as we know.

Further T-cell-related targets to identify tumor infiltrating T cells may include permanently expressed T cell surface molecules such as CD3 or the TCR.<sup>42,43</sup> A radiolabeled anti CD3 directed antibody was able to detect T cells in a preclinical model of colon cancer treated with anti-CTLA-4 therapy

showing potential to predict tumor growth in advance.<sup>42</sup> Its internalization enabling intracellular tracer accumulation makes the TCR a favorable target for immuno-PET imaging.<sup>43</sup> At the same time, however, it should be taken into account that the TCR is highly relevant for antigen recognition which could be disturbed by the application of tracers. Like that, it has been reported that a F(ab')<sub>2</sub> fragment directed against CD2 which is also involved in T-cell activation led to a strong impairment of T-cell functionality in a murine model of adoptive T-cell transfer.<sup>44</sup>

Another indirect way of detecting activated T cells as surrogate markers for immunotherapeutic response is by secreted molecules such as granzyme B, IFN $\gamma$  or IL-2. Granzyme B is released by activated CD8<sup>+</sup> T cells and its upregulation can indicate response to ICI.<sup>45</sup> These favorable characteristics justify testing its potential as predictive immuno-PET based biomarker.<sup>46</sup> Similarly, the detection of IFN $\gamma$  in the tumor microenvironment may indicate later response as shown in an in vivo tumor model of therapeutic Her2/neu vaccination.<sup>47</sup> Even though these approaches have not been tested in skin cancer models so far, their applicability in other tumor entities can be assumed. Markovic and colleagues have successfully conducted <sup>99m</sup>Tc-IL2 Single Photon Emission Computed Tomography (SPECT)/CT imaging in three patients with metastatic melanoma receiving immune-checkpoint inhibitor therapy without severe side-effects.<sup>48</sup> However, feasibility to assess therapy response and especially prediction remain to be tested in detail in larger patient cohorts. This is especially relevant since it is known that at least some 10,000 cells are required for sufficient detection by immuno-PET.<sup>49</sup> In this case, other diagnostic tools such as FNA biopsy remain valuable alternatives facilitating therapeutic decisions.

At least in the context of adoptive cell transfer, reporter-gene imaging seems a reasonable way to detect and monitor infused cells apart from metabolic tracers or immuno-PET (Figure 5). Reporter-gene imaging is based on a genetic modulation of therapeutic cells encoding a marker protein which can then be visualized by different methods including PET and SPECT, but also optical imaging modalities.<sup>50</sup> In this case, TCR or chimeric antigen receptor modulated T cells can be tracked.<sup>51</sup> Since adoptive T-cell transfer is not broadly applied therapy option for skin cancer, reporter-gene-based imaging has only been used on a preclinical basis in this context. Further developments in this field will show if there is a need for respective reporter-gene-based diagnostic tools.

## CONCLUSIONS

Immunotherapies have revolutionized therapeutic options in oncology including a variety of frequent skin cancers such as melanoma, basal cell carcinoma and cutaneous squamous cell cancer. Simultaneously, clinicians observed highly patient-specific response patterns resulting from

individual tumor micro-environmental settings requiring new diagnostic ways to precisely determine response to treatment.

For this reason, conventional image-assessment approaches were refined including iRECIST for CT or PERCIST and PERCMT for <sup>18</sup>F-DG-PET. Since none of the established non-invasive diagnostic tools is capable of sufficient response prediction, the combination of different imaging tools with photo documentation, optical imaging and in rare cases even diagnostic biopsies are feasible ways to evaluate therapy response to immunotherapies. Nevertheless, novel imaging modalities such as immuno-PET or reporter-gene based imaging may give more detailed insights into the tumor microenvironment allowing better therapy assessment or even response prediction facilitating the clinical use of immunotherapeutic applications.

## ACKNOWLEDGEMENTS

Open access funding enabled and organized by Projekt DEAL.

## CONFLICT OF INTEREST

None.

## REFERENCES

- Dudley ME, Wunderlich JR, Robbins PF, et al. Cancer regression and autoimmunity in patients after clonal repopulation with antitumor lymphocytes. *Science*. 2002;298:850-854.
- Barrios DM, Do MH, Phillips GS, et al. Immune checkpoint inhibitors to treat cutaneous malignancies. *J Am Acad Dermatol*. 2020;83:1239-1253.
- Ferrucci PF, Pala L, Conforti F, Cocorocchio E. Talimogene laherparepvec (T-VEC): An intralesional cancer immunotherapy for advanced melanoma. *Cancers (Basel)*. 2021;13:1383.
- Seymour L, Bogaerts J, Perrone A, et al. iRECIST: guidelines for response criteria for use in trials testing immunotherapeutics. *Lancet Oncol*. 2017;18:e143-e152.
- Ronchi A, Montella M, Zito Marino F, et al. Cytologic diagnosis of metastatic melanoma by FNA: A practical review. *Cancer Cytopathol*. 2022;130:18-29.
- Sade-Feldman M, Yizhak K, Bjorgaard SL, et al. Defining T cell states associated with response to checkpoint immunotherapy in melanoma. *Cell*. 2018;175:998-1013e20.
- Andtbacka RH, Kaufman HL, Collichio F, et al. Talimogene laherparepvec improves durable response rate in patients with advanced melanoma. *J Clin Oncol*. 2015;33:2780-2788.
- Dean-Ben XL, Razansky D. Optoacoustic imaging of the skin. *Exp Dermatol*. 2021;30:1598-1609.
- Audrey-Bayan C, Trager MH, Gartrell-Corrado RD, et al. Distinguishing melanophages from tumor in melanoma patients treated with talimogene laherparepvec. *Melanoma Res*. 2020;30:410-415.
- Pennock GK, Waterfield W, Wolchok JD. Patient responses to ipilimumab, a novel immunopotentiator for metastatic melanoma: how different are these from conventional treatment responses? *Am J Clin Oncol*. 2012;35:606-611.
- Borcoman E, Kanjanapan Y, Champiat S, et al. Novel patterns of response under immunotherapy. *Ann Oncol*. 2019;30:385-396.
- Chiou VL, Burotto M. Pseudoprogression and immune-related response in solid tumors. *J Clin Oncol*. 2015;33:3541-3543.
- Hodi FS, Hwu WJ, Kefford R, et al. Evaluation of immune-related response criteria and RECIST v1.1 in patients with advanced melanoma treated with pembrolizumab. *J Clin Oncol*. 2016;34:1510-1517.
- Nishino M, Giobbie-Hurder A, Manos MP, et al. Immune-related tumor response dynamics in melanoma patients treated with pembrolizumab: Identifying markers for clinical outcome and treatment decisions. *Clin Cancer Res*. 2017;23:4671-4679.
- Champiat S, Derclé L, Ammari S, et al. Hyperprogressive disease is a new pattern of progression in cancer patients treated by anti-PD-1/PD-L1. *Clin Cancer Res*. 2017;23:1920-1928.
- Rauwerdink DJW, Molina G, Frederick DT, et al. Mixed response to immunotherapy in patients with metastatic melanoma. *Ann Surg Oncol*. 2020;27:3488-3497.
- Schwartz LH, Litiere S, de Vries E, et al. RECIST 1.1-Update and clarification: From the RECIST committee. *Eur J Cancer*. 2016;62:132-137.
- Park HJ, Kim GH, Kim KW, et al. Comparison of RECIST 1.1 and iRECIST in patients treated with immune checkpoint inhibitors: A systematic review and meta-analysis. *Cancers*. 2021;13:120.
- Mulkey F, Theoret MR, Keegan P, et al. Comparison of iRECIST versus RECIST V.1.1 in patients treated with an anti-PD-1 or PD-L1 antibody: pooled FDA analysis. *J Immunother Cancer*. 2020;8:e000146.
- Wolchok JD, Hoos A, O'Day S, et al. Guidelines for the evaluation of immune therapy activity in solid tumors: immune-related response criteria. *Clin Cancer Res*. 2009;15:7412-7420.
- Loo K, Smithy JW, Postow MA, Betof Warner A. Factors determining long-term antitumor responses to immune checkpoint blockade therapy in melanoma. *Front Immunol*. 2021;12:810388.
- Tumeh PC, Harview CL, Yearley JH, et al. PD-1 blockade induces responses by inhibiting adaptive immune resistance. *Nature*. 2014;515:568-571.
- Young H, Baum R, Cremerius U, et al. Measurement of clinical and subclinical tumour response using [18F]-fluorodeoxyglucose and positron emission tomography: review and 1999 EORTC recommendations. European Organization for Research and Treatment of Cancer (EORTC) PET Study Group. *Eur J Cancer*. 1999;35:1773-1782.
- Wahl RL, Jacene H, Kasamon Y, Lodge MA. From RECIST to PERCIST: Evolving Considerations for PET response criteria in solid tumors. *J Nucl Med*. 2009;50(Suppl 1):122S-50S.
- Cho SY, Lipson EJ, Im HJ, et al. Prediction of response to immune checkpoint inhibitor therapy using early-time-point (18)F-FDG PET/CT imaging in patients with advanced melanoma. *J Nucl Med*. 2017;58:1421-1428.
- Anwar H, Sachpekidis C, Winkler J, et al. Absolute number of new lesions on (18)F-FDG PET/CT is more predictive of clinical response than SUV changes in metastatic melanoma patients receiving ipilimumab. *Eur J Nucl Med Mol Imaging*. 2018;45:376-383.
- Sachpekidis C, Kopp-Schneider A, Pan L, et al. Interim [(18)F]FDG PET/CT can predict response to anti-PD-1 treatment in metastatic melanoma. *Eur J Nucl Med Mol Imaging*. 2021;48:1932-1943.
- Seith F, Forschner A, Schmidt H, et al. 18F-FDG-PET detects complete response to PD1-therapy in melanoma patients two weeks after therapy start. *Eur J Nucl Med Mol Imaging*. 2018;45:95-101.
- Schwenck J, Schorg B, Fiz F, et al. Cancer immunotherapy is accompanied by distinct metabolic patterns in primary and secondary lymphoid organs observed by non-invasive in vivo (18)F-FDG-PET. *Theranostics*. 2020;10:925-937.
- Ayati N, Sadeghi R, Kiamanesh Z, et al. The value of (18)F-FDG PET/CT for predicting or monitoring immunotherapy response in patients with metastatic melanoma: a systematic review and meta-analysis. *Eur J Nucl Med Mol Imaging*. 2021;48:428-448.
- Levi J, Lam T, Goth SR, et al. Imaging of activated t cells as an early predictor of immune response to anti-PD-1 therapy. *Cancer Res*. 2019;79:3455-3465.
- Topalian SL, Taube JM, Anders RA, Pardoll DM. Mechanism-driven biomarkers to guide immune checkpoint blockade in cancer therapy. *Nat Rev Cancer*. 2016;16:275-287.
- Wu AM. Antibodies and antimatter: the resurgence of immuno-PET. *J Nucl Med*. 2009;50:2-5.
- Rashidian M, Ingram JR, Dougan M, et al. Predicting the response to CTLA-4 blockade by longitudinal noninvasive monitoring of CD8 T cells. *J Exp Med*. 2017;214:2243-2255.

35. Farwell MD, Gamache RF, Babazada H, et al. CD8-targeted PET imaging of tumor infiltrating T cells in patients with cancer: A phase I First-in-human study of 89 Zr-Df-IAB22M2C, a radiolabeled anti-CD8 minibody. *J Nucl Med.* 2022;63:720-726.
36. Daud AI, Wolchok JD, Robert C, et al. Programmed death-ligand 1 expression and response to the anti-programmed death 1 antibody pembrolizumab in melanoma. *J Clin Oncol.* 2016;34:4102-4109.
37. Bridgwater C, Geller A, Hu X, et al. 89 Zr-labeled anti-PD-L1 antibody fragment for evaluating in vivo PD-L1 Levels in melanoma mouse model. *Cancer Biother Radiopharm.* 2020;35:549-557.
38. Nienhuis PH, Antunes IF, Glaudemans A, et al. 18 F-BMS986192 PET imaging of PD-L1 in metastatic melanoma patients with brain metastases treated with immune checkpoint inhibitors. A pilot study. *J Nucl Med.* 2022;63:899-905.
39. van der Veen EL, Giesen D, Pot-de Jong L, et al. 89 Zr-pembrolizumab biodistribution is influenced by PD-1-mediated uptake in lymphoid organs. *J Immunother Cancer.* 2020;8:e000938.
40. Burova E, Hermann A, Dai J, et al. Preclinical development of the anti-LAG-3 antibody REGN3767: Characterization and activity in combination with the anti-PD-1 antibody cemiplimab in human PD-1xLAG-3-knockin mice. *Mol Cancer Ther.* 2019;18:2051-2062.
41. Alspach E, Lussier DM, Miceli AP, et al. MHC-II neoantigens shape tumour immunity and response to immunotherapy. *Nature.* 2019;574:696-701.
42. Larimer BM, Wehrenberg-Klee E, Caraballo A, Mahmood U. Quantitative CD3 PET imaging predicts tumor growth response to anti-CTLA-4 therapy. *J Nucl Med.* 2016;57:1607-1611.
43. Griessinger CM, Maurer A, Kesenheimer C, et al. 64Cu antibody-targeting of the T-cell receptor and subsequent internalization enables in vivo tracking of lymphocytes by PET. *Proc Natl Acad Sci USA.* 2015;112:1161-1166.
44. Mayer KE, Mall S, Yusufi N, et al. T-cell functionality testing is highly relevant to developing novel immuno-tracers monitoring T cells in the context of immunotherapies and revealed CD7 as an attractive target. *Theranostics.* 2018;8:6070-6087.
45. Herbst RS, Soria JC, Kowanetz M, et al. Predictive correlates of response to the anti-PD-L1 antibody MPDL3280A in cancer patients. *Nature.* 2014;515:563-567.
46. LaSalle T, Austin EE, Rigney G, et al. Granzyme B PET imaging of immune-mediated tumor killing as a tool for understanding immunotherapy response. *J Immunother Cancer.* 2020;8:e000291.
47. Gibson HM, McKnight BN, Malysa A, et al. IFNgamma PET imaging as a predictive tool for monitoring response to tumor immunotherapy. *Cancer Res.* 2018;8:5706-5717.
48. Markovic SN, Galli F, Suman VJ, et al. Non-invasive visualization of tumor infiltrating lymphocytes in patients with metastatic melanoma undergoing immune checkpoint inhibitor therapy: a pilot study. *Oncotarget.* 2018;9:30268-30278.
49. Yusufi N, Mall S, Bianchi HO, et al. In-depth characterization of a TCR-specific tracer for sensitive detection of tumor-directed transgenic T cells by immuno-PET. *Theranostics.* 2017;7:24022416.
50. Li M, Wang Y, Liu M, Lan X. Multimodality reporter gene imaging: Construction strategies and application. *Theranostics.* 2018;8:2954-2973.
51. Emami-Shahri N, Foster J, Kashani R, et al. Clinically compliant spatial and temporal imaging of chimeric antigen receptor T-cells. *Nat Commun.* 2018;9:1081.

**How to cite this article:** Mayer KE, Gaa J, Biedermann T, Posch C. Image-based response assessment during immunotherapy in skin cancer. *JDDG: Journal der Deutschen Dermatologischen Gesellschaft.* 2023;21:107–114.  
<https://doi.org/10.1111/ddg.14941>