



Technische Universität München

Fakultät für Medizin

TMD and orthognathic surgery: Is the matter still relevant? A longitudinal analysis of 375 patients

Laura Burger-Krebes

Vollständiger Abdruck der von der Fakultät für Medizin
der Technischen Universität München zur Erlangung des akademischen Grades
einer Doktorin der Medizin genehmigten Dissertation.

Vorsitz

Prof. Dr. Herbert Deppe

Prüfende der Dissertation

1. apl. Prof. Dr. Dr. Andreas Kolk
2. Priv.-Doz. Dr. Markus Wirth

Die Dissertation wurde am 05.05.2021 bei der Technischen Universität München
eingereicht und durch die Fakultät für Medizin am 12.10.2021 angenommen.

Für meinen Mann, meine Tochter und meine Eltern

In ewiger Dankbarkeit für ihre immerwährende Unterstützung und Liebe

Table of contents

Abbreviations	4
Abstract	6
1 Introduction	7
1.1 Hypotheses.....	10
1.2 Temporomandibular joint.....	11
1.2.1 Anatomy of TMJ	11
1.2.2 TMJ function.....	12
1.2.3 Temporomandibular dysfunction	13
1.2.4 Signs and symptoms of TMD.....	14
1.2.5 Treatment of TMD	18
1.3 Orthognathic surgery	22
1.3.1 Presurgical orthodontic treatment	23
1.3.2 Surgical planning.....	24
1.3.3 Surgical treatment	26
1.3.4 Postsurgical orthodontic treatment.....	35
2 Patients and Methods	36
2.1 Outcome measures.....	37
2.2 Study design	37
2.2.1 Preoperative planning.....	37
2.2.2 Surgical technique	44

2.2.3	Postoperative follow-up	45
2.3	Evaluation and data collection.....	46
2.4	Helkimo Index	52
2.5	Statistical analysis.....	53
3	Results	54
3.1	Descriptive statistics	54
3.2	TMJ function	55
3.3	Clinical signs and symptoms	58
3.4	Risk factors for patients without TMD symptoms at T0.....	62
3.5	Dysfunction index by Helkimo.....	72
4	Discussion	75
4.1	Sex	81
4.2	Age.....	81
4.3	Skeletal class.....	82
4.4	Type of rotation of the maxillo-mandibular complex	83
4.5	Amount of mandibular advancement	84
5	Drawbacks of the study	86
6	Conclusion.....	87
7	Acknowledgement.....	88
8	Publications	89
9	References	90
10	List of figures	106

11 List of tables 108

Abbreviations

Abbreviations	Meaning
A	
ALL	Arthroscopic lysis and lavage
B	
BSSO	Bilateral sagittal split osteotomy
BTX	Botulinum Toxin
C	
CAD/CAM	Computer-aided design and manufacturing
CBCT	Conebeam computer tomography
CCR	Counterclockwise rotation
CR	Clockwise-rotation
D	
DICOM	Digital imaging and communications in medicine
H	
HI: Di/Ai	Helkimo Index: Clinical dysfunction Index/Anamnestic Index
M	
MMC	Maxillomandibular complex
MMO	Maximal mouth opening
MTD	Maxillary transverse deficiency
N	
NHO	Natural Head Orientation
NSAIDs	Non-steroidal anti-inflammatory drugs

O

OGS Orthognathic surgery

P

PMMA Polymethylmethacrylate

PACS Picture archiving and communication system

R

RDC/TMD The Research Diagnostic Criteria for Temporomandibular Disorders

S

SARPE Surgically assisted rapid palatal expansion

STL Stereolithography

T

TMJ Temporomandibular joint

TMD Temporomandibular disorders

V

VSP Virtual surgical planning

Abstract

Purpose: The effects of orthognathic surgery (OGS) on the temporomandibular joint (TMJ) are still controversial. Based on a high-volume uniform sample, the function and clinical symptoms of the TMJ and the dysfunction index by Helkimo (Di) were evaluated prior to, and up to two years after OGS.

Materials and Methods: A longitudinal cohort study was performed between 2006 and 2016. A comprehensive clinical examination focusing on TMJ function, temporomandibular joint dysfunction (TMD) symptoms (pain, clicking, and crepitus), and the Di had been performed preoperative (T0) and postoperative at six weeks (T1), six months (T2), one (T3), and two years (T4). The predictor variables used were sex, age, skeletal class, type of surgery, and amount of dysfunction or TMD complaints prior to treatment. The outcome of this study was TMD symptoms and the Di. Descriptive and bivariate statistics were computed, and the significance level was set at $P < .05$.

Results: The sample consisted of 375 patients (247 women, 128 men, mean 28.1 ± 9.4 years), 269 with skeletal class II (71.7%), and 106 with skeletal class III (28.3%) treated with bilateral sagittal split osteotomy (BSSO) ($n = 173$) or Le Fort and BSSO combined ($n = 202$). Severe signs of dysfunction (Di 2/3) were seen in 5.9% of the patients before, and in 2.1% of the patients two years after OGS. The difference of Di (Di0/1 and Di2/3) between T0 and T1/T2 was statistically significant ($P = .028$; $P = .011$ respectively). Female gender ($P = .013$), skeletal class II ($P < .001$), and counterclockwise rotation ($P < .001$) were the only risk factors significantly associated with the occurrence of TMD after six weeks. TMD symptoms were notably reduced two years after OGS ($P = .028$).

Conclusion: The results of the study suggest that in most cases TMD symptoms can be remarkably reduced, and only a few can be induced, with OGS. No risk factors were found for long-term effects on the TMJ.

1 Introduction

Orthognathic surgery (OGS) is widely used to correct severe congenital or acquired dentofacial deformities. The goals of providing improvement for the patient's aesthetic and functional problems are paramount to the surgery. The functional component relates to mainly oral functions such as speech, malocclusion, sleep apnea, and swallowing, all of which can be affected by the temporomandibular joint (TMJ) to a greater or lesser extent. Obtaining harmony and balance in facial appearance is the focus of the aesthetic component. The mandibular condyle is part of the anatomic structures that constitute the TMJ. Objectively, the position of the condyles in relation to the temporal bone and the disc can be altered via various movements during OGS. Thus, OGS affects functional and aesthetic components including mastication, pronunciation, and clinical TMJ function. However, the impact on TMJ function has been a point of discussion in the scientific literature, with multiple articles published on the subject (Dujoncquoy et al., 2010; Iannetti et al., 2013; Kretschmer et al., 2019; Van Sickels et al., 1997).

The term temporomandibular dysfunction (TMD) can be defined as a collective name for conditions that involve pain and/or dysfunction of the TMJ, and/or the related masticatory musculature (de Leeuw, 2008; Young, 2016). Signs and symptoms of TMD include facial pain, headache, limited jaw movement, joint noise, clicking, and deviation of mandible during mouth opening or closing (Al-Moraissi et al., 2017; Dujoncquoy et al., 2010; Scrivani, Steven J.; Keith David A.. Kaban, 2008; Sinisalu & Akermann, 2016). In several examinations, the prevalence of TMD is thought to be around 5% in the population (Bevilaqua-Grossi et al., 2006; LeResche, 1997; Scrivani, Steven J.; Keith David A.. Kaban, 2008).

Moreover, dysfunction of the masticatory system has been reported to be more frequent in individuals with dentofacial anomalies than in those without TMJ pathology (Egermark et al., 2000; Nokar et al., 2018). Some authors have reported that OGS has a beneficial effect and

reduces the signs and symptoms of preexisting TMD, or at least does not aggravate them (Arya et al., 2017; Dervis et al., 2013; Hackney et al., 1989; Kretschmer et al., 2019; T. Magnusson et al., 1990, 2000; Onizawa et al., 1995; Panula et al., 2005; Rodrigues-Garcia et al., 1998). However, relief in clinical signs in individual patients cannot be accurately predicted preoperatively (Kretschmer et al., 2019; Sostmann et al., 1991). In contrast, there are studies that suggest that OGS may result in alteration of TMJ function (jaw movement, jaw deviation on mouth opening) and may induce clinical signs of TMD symptoms such as pain (facial, headache, earache, and joint pain) and/or joint noise (clicking, popping, or crepitus) (Abrahamsson et al., 2015; Al-Moraissi et al., 2017; Dujoncquoy et al., 2010). Other authors concluded that, especially in patients with former TMD symptoms, OGS can cause further deleterious effects on the TMJ (Hori et al., 1999; Mehra et al., 2001; Wolford et al., 2003). In a systematic review on this subject, however, no conclusions could be drawn due to the few studies identified, heterogeneity in study design, and unclear results (Abrahamsson et al., 2007). OGS, either as a single jaw or double jaw surgery, became popular in the late 1960s following the wide acceptance of maxillofacial surgery (Trauner & Obwegeser, 1957). Nowadays, they are the most commonly performed surgeries in the correction of dentofacial deformities (Iannetti et al., 2013).

TMJ pathology is a common source for late skeletal and occlusal instability following OGS, as well as continued or worsening pain, headaches, and jaw dysfunction. These instabilities are usually a result of preexisting unrecognized and untreated TMJ pathology or TMJ conditions created by the OGS, such as excessively traumatic surgery that damages the joints, or overloading them by intentionally creating posterior open bites at surgery (Wolford et al., 2011).

To individually classify the incidence of TMD and assess the severity of the disease, the use of indices is an excellent means. Helkimo developed an index to measure the severity of TMD

symptoms. His index was first described in 1974 (Helkimo, 1974b). The Helkimo index (HI) is a two-part index including anamnestic (Ai) and clinical dysfunction (Di). It has been used to assess TMD in varying clinical scenarios and been found to have an acceptable level of accuracy (Cunha et al., 2007; Leamari et al., 2019; Nokar et al., 2018; Rani et al., 2017).

Patient and operative factors have been examined in the literature to establish the relationship between OGS and TMJ including gender, age, preoperative skeletal pattern, malocclusion and orthodontic treatment, preoperative signs and symptoms of TMD, type of fixation, amount and type of jaw movement, and rotation of the maxillomandibular complex (MMC). Limitation in sample size has been one of the major issues with previous literature on this subject, thus making it difficult to reach a conclusion on the association between OGS and TMD. The aim of this study is to provide evidence of the relationship between OGS and TMD, by examining data before and after surgical intervention, and to identify risk factors relevant to the latter, in a large cohort of patients using the dysfunction index by Helkimo. In this underlying longitudinal study, the sample size is unique. Consequently, for the first time the study is suitable for the validation of results of TMJ function and clinical signs of TMD before, and up to two years after OGS.

1.1 Hypotheses

The key questions that are raised here are: Is there a difference in TMD symptoms before and after OGS, and are there predictive risk factors associated with the prevalence of TMD?

The hypothesis was:

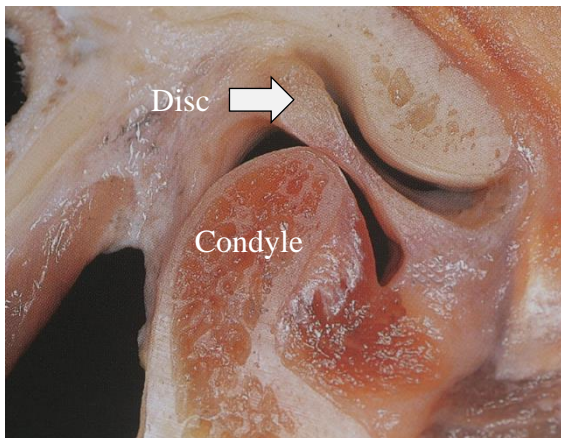
- 1) that the prevalence of TMD is not increased with OGS,
- 2) risk factors such as sex, age, skeletal class, clockwise (CR) or counterclockwise (CCR) rotation of the MMC and the amount of jaw movement increase the risk of TMD.

1.2 Temporomandibular joint

1.2.1 Anatomy of TMJ

The TMJ is a ginglymus-arthrodial joint, a term that is derived from ginglymus, meaning a hinge joint, and arthrodia, which defines a joint that permits a gliding motion of the surfaces. It has certain unique features: its articular surface is covered by fibrocartilage instead of hyaline cartilage; the condylar cartilage is considered a growth centre that significantly contributes to the overall growth of the mandible; the TMJ functions bilaterally and can be influenced by dental occlusion. Furthermore, it has an intact disc between the condyle and the temporal bone that functions as a shock absorber. The disc is also described as an avascular non-innervated fibrocartilage that covers the condyle during all joint movements due to his flexible and complex anatomical composition. (Alomar *et al.*, 2007)

A



B

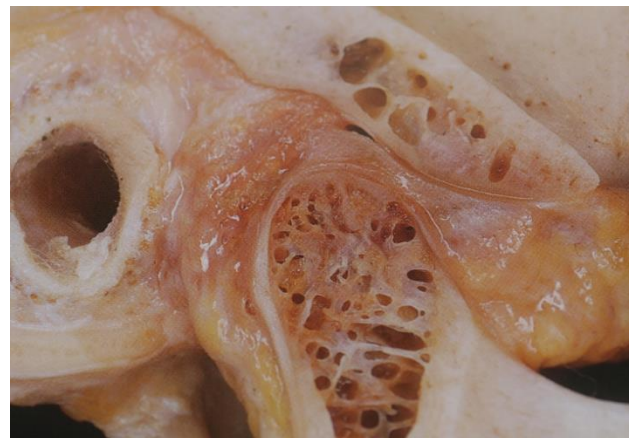

Figure 1. Anatomy of the pterygomandibular joint (sagittal section). A. open, B closed.

Adapted from Buhmann & Lotzmann, 2000

The joint has two articular bone components – the mandibular condyle inferiorly, and the articular eminence and glenoid fossa of the temporal bone superiorly and is lined by synovial

membrane. Other components of TMJ are: Capsule, extracapsular ligaments, disc, and disc ligaments. The superficial temporal and the internal maxillary branches of the external carotid artery supply the joint, the muscles of mastication, as well as the capsule.

The muscles that act on the TMJ are the masseter, temporalis, and pterygoids along with a group which are classed under suprahyoid and infrahyoid muscles.

Primarily, the TMJ receives innervations from the auriculotemporal nerve branch of the mandibular nerve (V3 of the trigeminal nerve), as well as from the masseteric and deep temporal nerves. Ruffini receptors, Golgi tendon organs, and Pacinian corpuscles are the additional types of mechanoreceptors, that the capsule contains beside the nerve fibres. (David & Elavarasi, 2016)

1.2.2 TMJ function

The basic anatomical functions of the mandible are to: open and close, protrude and retrude, and slide laterally to the left and right. These movements arise out of a combination of rotation and translation. Rotation occurs in the lower portion of the joint whilst translation occurs in the upper portion of the joint. Muscular control of TMJ movement is moderated through extensive sensory and proprioceptive pathways which line the entire stomatognathic system, namely, periodontal ligaments, muscles of mastication, and joint receptors. Jaw opening is affected by action of the lateral pterygoids primarily, with supporting action from the suprahyoid muscles. The temporalis, masseter, and medial pterygoids act in jaw closure.

Average maximum mouth opening, measured between the edges of the central incisors, has been reported to be between 35 mm and 60 mm across different population groups (Al-Dlaigan & Asiry, 2014; Cox & Walker, 1997; De Rossi et al., 2014; Ingervall, 1971; Khare et al., 2012; Mezitis et al., 1989; Posselt & Nevstedt, 1961; Woelfel et al., 2014). Protrusive movement of

the jaw is affected by the action of medial and lateral pterygoids with evidence of contribution from geniohyoid, digastric and masseter muscles. Normal average protrusive jaw movement is about 7 to 10 mm (De Rossi et al., 2014; Ingervall, 1971; Woelfel et al., 2014).

In retrusion, the temporalis muscle acts with contribution from the digastric and mylohyoid muscles. For lateral mandibular deviation, posterior fibres of the temporalis on the ipsilateral side, digastric, mylohyoid, and geniohyoid act in unison while on the contralateral side, lateral and medial pterygoids are prime movers (Helland, 1979). Average maximum lateral excursion is about 7 to 10 mm on each side (De Rossi et al., 2014; Ingervall, 1971; Woelfel et al., 2014).

1.2.3 Temporomandibular dysfunction

TMD is a wide-ranging group of conditions affecting related disorders of the TMJ function and morphology, masticatory muscles, and dental occlusion, with common clinical symptoms such as pain, limited mouth opening, and TMJ sounds. The change of the position of the maxilla, mandible or both jaws during OGS can change the interaction of this components and therefore affect TMJ function and TMD symptoms.

TMD is common in adults; with peak incidence between 20 to 40 years of age, it is reported to be twice as common in women than in men (John et al., 2003; Maixner et al., 2011; Manfredini et al., 2011; Scrivani, Steven J.; Keith David A.. Kaban, 2008). The etiology of TMD remains unclear, but it is likely multifactorial (Table 1). In the scientific community it can be assessed clearly that the causes of TMD are likewise complex, and not entirely examined yet (De Rossi et al., 2014; Scrivani, Steven J.; Keith David A.. Kaban, 2008).

1.2.4 Signs and symptoms of TMD

Hypomobility

Mandibular hypomobility is generally defined as the limitation of mouth opening. It can be a sign of various underlying etiologies and is a common clinical symptom associated with masticatory muscle disorders. Clinically, the minimized incisal edge distance arises from a decrease in the range of mandibular movement. When muscle tissues have been compromised by overuse, any contraction or stretching increases the pain for the patient. Therefore, the patients tend to decrease pain by restricting movements while mouth opening, depending on where discomfort is felt. These limitations may also be partly due to contraction of the antagonistic muscles, a phenomenon that is called protective co-contraction (Mense, 2003; Okeson & de Leeuw, 2011).

TMJ sounds (Clicking, popping, crepitus)

TMJ sounds are frequent complaints. From an anamnestic point of view, they are often described as clicking, popping, grating, or crepitus. In many cases, the joint sounds are not accompanied by pain or dysfunction. However, in specific cases, joint sounds can be associated with locking of the jaw during opening or closing, or with pain (Okeson & de Leeuw, 2011).

The joint sounds can be described as a single event of short duration known as a click or if this is loud, it may be referred to as a pop.

Joint clicking is differentiated as follows:

1. Initial Clicking is a sign of retruded condyle in relation to the disc.
2. Intermediate clicking is a sign of unevenness of the condylar surfaces.

3. Terminal clicking is an effect of the condyle being moved too far into the anterior direction in relation to the disc on MMO. It is a sign of unevenness of the condylar surface or a peripheral irregularity of the articular disc.
4. Reciprocal clicking occurs during opening and closing, and shows an incoordination between displacement of the condyle and the disc. (Pawar et al., 2016)

A single click during opening of the mouth may be associated with an anterior disc displacement. A second click during closure of the mouth results in recapture of the displaced disc; this condition is referred to as disc displacement with reduction. When disc displacement progresses and the patient is unable to fully open the mouth (i.e., the disc is blocking translation of the condyle), this condition is referred to as closed lock (Okeson, 2008; Okeson & de Leeuw, 2011).

Crepitation is a multiple, rough, gravellike sound, described as grating or grinding. A roughness of the articular surfaces because of remodeling or osteoarthritis is usually related to crepitation. (Okeson & de Leeuw, 2011)

Neither crepitation nor clicking alone is an indication for conservative or operative treatment.

Pain

Pain in TMJ can arise from masticatory muscle dysfunctions or temporomandibular joint disorders. It is called myalgia when the pain is felt in muscle tissues. Generally, the severity of muscle pain is directly related to the amount of functional activity. During examination patients often report pain in the preauricular areas, face, or temples. In most cases, pain associated with TMD is increased with jaw movement. Therefore, when a patient's pain complaint is not influenced by jaw function, other sources of (orofacial) pain should be suspected. (Okeson & de Leeuw, 2011)

Joint pain can arise from healthy joint structures that are mechanically abused during function, from impingement of tissues, or from inflamed structures. Pain originating from healthy structures or impingements is often felt as a sharp and sometimes intense hurt that is closely associated with joint movement. In the clinical examination, the patient often reports the pain as being localized to the preauricular area and stops instantly, when the joint is rested.

If the joint structures have become inflamed, the pain is reported as constantly dull or throbbing.

This kind of hurt does not stop when the joint is at rest. (Okeson & de Leeuw, 2011)

To improve the patient's complaint conservative treatment of TMD should always be the first step.

Table 1. AAOP Diagnostic classification of TMD

Diagnostic Category	Diagnoses
Cranial bones (including the mandible)	<ul style="list-style-type: none"> • Congenital and developmental • Disorder aplasia, hypoplasia, hyperplasia • Dysplasia (e.g. first and second branchial arch anomalies, hemifacial microsomnia, Pierre Robin syndrome, Treacher Collins syndrome, condylar hyperplasia, prognathism, fibrous dysplasia) • Acquired disorders (neoplasia, fracture)
TMJ disorders	<ul style="list-style-type: none"> • Deviation in form of disc displacement (with reduction, without reduction) • Dislocation • Inflammatory conditions (synovitis, capsulitis) • Arthritis (osteoarthritis, osteoarthrosis, polyarthritis) • Ankylosis (fibrous, bony) • Neoplasia
Masticatory muscle disorders	<ul style="list-style-type: none"> • Myofascial pain • Myositis spasm • Protective splinting contracture

Adapted from Leeuw Rd, Klasser GD, American Academy of Orofacial P. Orofacial Pain: guidelines for assessment, diagnosis, and management. 5th edition, Chicago: Quintessence Publishing 2013.

1.2.5 Treatment of TMD

There are essentially two types of therapy for TMD – conservative (non-invasive), and surgical (invasive), during which the joint structures themselves are entered. Conservative treatment includes e.g. bite splints, rehabilitation exercises, isometric exercises, massage of the chewing muscles, analgesic treatment, thermotherapy, or laser therapy. Surgical treatment can be divided into minimally invasive (which includes arthrocentesis and arthroscopy), and invasive (open) procedures (Trauner & Obwegeser, 1957; Tvrdy et al., 2015). Surgical treatment is indicated in only 2% to 5% of cases (da Silva et al., 2015). Reviews of the literature, including one meta-analysis, have not demonstrated significant differences between physical therapy, arthrocentesis, arthroscopic surgery, and disc repair/repositioning surgery relative to outcomes such as maximum mouth opening, jaw pain, and jaw function (Holmlund et al., 2001; Kropmans et al., 1999; Reston & Turkelson, 2003; Schiffman et al., 2007).

Conservative treatment options

Supportive patient education is recommended in initial treatment for TMD (Dimitroulis, 1998). Medical management include education on the participant's condition, soft diet, optimistic counseling, a home exercise program, and a regimen of oral methylprednisolone followed by non-steroidal anti-inflammatory drugs (NSAIDs), muscle relaxants, and over-the-counter analgesics (Schiffman et al., 2007, 2014). The choice of medications is largely based on expert opinion. A Cochrane review evaluating nonsteroidal anti-inflammatory drugs (NSAIDs; including salicylates and cyclooxygenase inhibitors), benzodiazepines, antiepileptic agents, and muscle relaxants found insufficient evidence to support or refute the effectiveness of any drug for the treatment of TMD (Gauer & Semidey, 2015; Mujakperuo et al., 2010). Rehabilitation includes medical management plus use of an intra-oral splint, physical therapy, and cognitive behavioural therapy (Klasser & Greene, 2009). The use of occlusal splints is thought to alleviate

or prevent degenerative forces placed on the TMJ, articular disc, and dentition by restoring the centric relation of the jaws (Klasser & Greene, 2009). Physical therapy techniques may be active or passive (e.g., scissor opening with fingers, use of medical devices) with the goal of improving muscle strength, coordination, relaxation, and range of motion (Dimitroulis, 1998). Specialized physical therapy options such as ultrasound, iontophoresis, electrotherapy, or low-level laser therapy have been used in the management of TMD, despite the lack of evidence to support their use (Melis et al., 2012). Cognitive behavioral therapy includes assessment of oral habits, maladaptive habits, psychopathology, follow-up sessions focused on education, habit reversal, and improvement of compliance and self-efficacy (Schiffman et al., 2007). Acupuncture and injection of botulinum toxin (BTX) are other conservative treatment options that have been explored (Cho & Whang, 2010; Fallah HM, 2012; Gauer & Semidey, 2015; La Touche et al., 2010).

Surgical treatment options

Arthrocentesis

Arthrocentesis is a minimal invasive clinical intervention for the lavage of the joint space. It is used to wash out inflammatory mediators, reduce pain, improve joint mobility or release the disc. To treat internal disorders of TMD the arthrocentesis is a method with a minimum number of complications and can be performed repeatedly.

The surgical procedure consists in the introduction of a pair of needles into the upper joint space and following lavage, using a solution of physiological saline or Ringer's solution. The first needle introduces the solution into the joint, and the second one is used to drain the liquid. Another option is to use a single-needle technique, which consists of introducing only one injection needle into the upper joint space. The most frequent indication for arthrocentesis is an

acute anterior displacement of the articular disc without reduction or hypomobility of the joint with occurrences of disc adhesions (a stuck disc). Lavage of the upper joint gap helps to reduce pain by removing inflammatory mediators from the joint. Arthrocentesis also abolishes negative pressure, loosens adhered discs, and reinstates its free sliding movement (Singh & Varghese, 2013).

The risk for intraoperative or postoperative complications ranges between 2% and 10%. These complications include injury to the facial nerve, preauricular hematoma, injury to the superficial temporal artery, the development of an arteriovenous fistula, bleeding into the joint, intracranial perforation, extradural hematoma, breakage of a part of the needle in the joint, unsuccessful introduction of the needle, leakage of the lavage fluid into the extra-articular space in the area, damage to the surface of joint or an allergic reaction to the anesthetic or drugs that may be administered at the end of the arthrocentesis. (Tozoglu et al., 2011; Tvrdy et al., 2015)

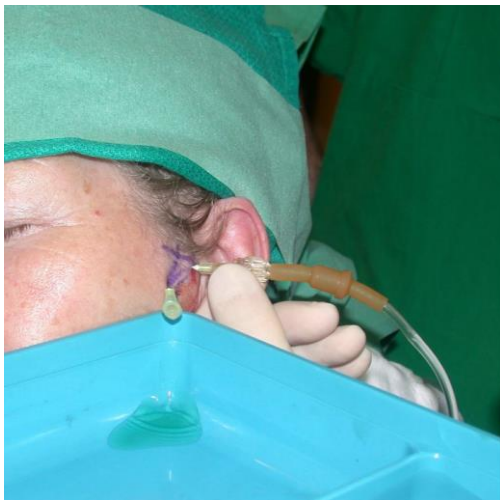

Figure 2. Arthrocentesis. Two needles are placed in the upper compartment of the TMJ. Ringer's solution is flushed through this compartment (courtesy of LKH Feldkirch)

Arthroscopic Lysis and Lavage

Arthroscopic lysis and lavage (ALL) has been successfully employed in internal disorders of TMJ refractory to conservative therapy with occlusal splints and physiotherapy (da Silva, Lopes and Freire, 2015). The arthroscopy was introduced in the 1970s by Ohnishi and former described in the literature as “Lysis” by Sanders in 1986 (Sanders, 1986).

This technique allows the direct observation of disc function, fibrocartilage degeneration, or other pathologies of the TMJ. With this technique, fibrosis and adhesions are disrupted by instrumentation through the working cannula, whilst maintaining a continuous flow of 0.9% saline or Ringer’s solution. Thus, the product of the breakdown of adhesions, and also its inflammatory components, are eliminated. It promotes a better anatomical and physiological condition allowing better mobilization of TMJ, and decreased pain (González-García and JL Gil-Díez Usandizaga, Rodríguez-Campo, 2011). The reported complication rate of this procedure ranges between 1% and 2% in the literature (Carls et al., 1996; da Silva, Lopes and Freire, 2015). These complications were transient and included injury related to the cranial nerves V and VII, instrument breakage, foreign body reactions, bleedings, and tympanic membrane perforation (da Silva, Lopes and Freire, 2015).

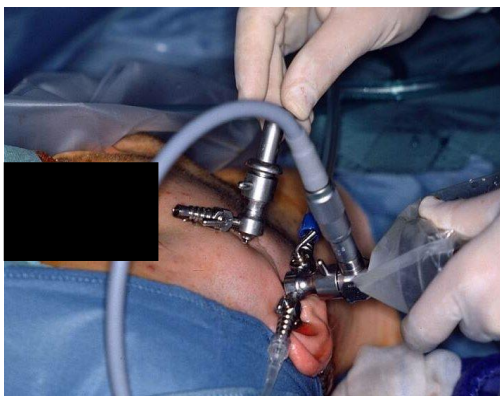

Figure 3. Arthroscopic lysis and lavage. Arthroscopy probes inserted into joint space (courtesy of LKH Feldkirch)

1.3 Orthognathic surgery

Orthognathic surgery is a surgical intervention to correct dentofacial deformities and improve the conditions of the jaw and lower face, facial aesthetics, airway issues and extensive skeletal or dental malocclusion problems. A further indication for OGS is the surgical therapy of TMD. The TMJ underlies adaptive developmental changes on mandibular condyles and post-developmental degenerative changes of mandibular condyles and can create alteration to the facial skeleton and dental occlusion. Also, trauma or developmental deformity causing the changes in morphology and occlusion can alter the biomechanics of TMJ and consequently induce signs and symptoms of TMD. (Inui et al., 1999; Mongini, 1983; Schellhas et al., 1993; Shen & Darendeliler, 2005). Moreover, skeletal class II malocclusion, longer posterior facial height, and hyperdivergent profile tend to show increased severity in internal derangement of TMJ (W. S. Jung et al., 2013).

In a retrospective study including children younger than 14, the presence of TMD affects a normal development of facial bones and can result in mandibular asymmetry. Thus, the severity of TMD and disc displacement can lead to mandibular hypoplasia or facial asymmetry. (Schellhas et al., 1993)

Also, degenerative changes and resorption of the mandibular condyle beyond growth completion can lead to changes in skeletal shape (H.-D. Jung et al., 2015; Schellhas et al., 1990). Patients who seek OGS are primarily motivated by desire to improve facial aesthetics, oral function, as well as TMD symptoms (Buttke & Proffit, 1999; Farella et al., 2007). OGS procedures involve surgical movements of upper jaw via Le Fort I osteotomy and lower jaw via ramus osteotomy (H.-D. Jung et al., 2015).

1.3.1 Presurgical orthodontic treatment

Planning and enforcement of OGS is an interdisciplinary challenge and involves a multidisciplinary team, including the oral and maxillofacial surgeon, orthodontist and in some cases a speech therapist. After the initial evaluation in agreement with the surgeon, the orthodontist leads the presurgical phase. The main goal of the initial evaluation is to define the deformity and to address the aims of the treatment. This is done by carefully collecting and analyzing orthodontic records, along with a thorough clinical evaluation. The aim of presurgical orthodontics is to decompensate the angulation and rotation of the teeth and to align the dental arches. If the teeth are not decompensated prior to OGS, dental interferences may occur that prevent ideal positioning of the skeletal subunits. Recent literature has been published that suggests certain advantages to foregoing presurgical orthodontics and performing surgery first (Liou et al., 2011).

Advantages of this surgery first protocol include - ability to address the patient's chief complaint early; immediate improvement of dental function and facial aesthetics; possible shorter overall treatment times; faster dental movement due to the phenomenon of postoperative accelerated orthodontic tooth movement; the ability to achieve difficult dental movements, such as torque of the maxillary incisors, through segmental osteotomies and repositioning of the skeletal segments. (Wirthlin and Shetye, 2013)

When performing orthognathic surgical planning the limits of skeletal movement must be defined individually for every patient and the goals of the surgery must then be prioritized. After the presurgical orthodontics, the surgical planning and the OGS will be taken over by the maxillofacial surgeon.

1.3.2 Surgical planning

Surgical planning is performed by the maxillofacial surgeon either two-dimensionally (2D) or three-dimensionally (3D). In case of 2D planning, conventional radiographs and cast models are used for the simulation steps. Using the 3D procedure, the surgical planning steps are mostly digital and can be visualized via personal computer.

Conventional surgical planning

The process involves presurgical clinical measurements; intraoral and extraoral photographs; radiographic analysis and manual 2D cephalometric tracing; dental impressions; bite registration and facebow recording; dental cast fabrication; mounting on articulator with transfer of facebow recording; setting of dental landmarks and horizontal and vertical marker on articulated models. After determining the amount of correction of the maxilla and mandible in all three planes, surgery is performed on the cast models. The surgical splints are fabricated with acrylic based on the dental cast movements. This technique has stood the test of time, although this method requires a wide-ranging process of analytical and radiographic analysis, dental model fabrication, and splint preparation. Conventional surgical planning requires an extensive time commitment, a firm grasp of dental materials, and has the potential for inaccuracies to be exaggerated during the algorithmic process. (Hammoudeh et al., 2015; Levine et al., 2012; Steinhuber et al., 2018)

Model Surgery

Cephalometric prediction must be done prior to the model surgery because its analysis is mandatory for the positioning of the casts. Conventional surgical planning allows a quantitative analysis of various occlusal relationships and discrepancies as they relate to overbite, overjet, and dental relation of the first molar and canine. There are numerous analyses available to the

clinician to define the various malocclusions as well as a quantitative analysis that helps define the sella turcica to traditional A and B points of the maxilla and mandible, respectively. The following presurgical imaging, dental analysis, and model surgery then allow the surgeon to transfer records, completed with a presurgical examination, to a set of casts. To correct the underlying dentofacial deformity, these casts can then be studied to plan 3-dimensional maxillary and mandibular movements. Performing model surgery enables a surgeon to determine the blueprint for surgery and to directly fabricate an exact dental template for precise and accurate surgical movements and results. (Hammoudeh et al., 2015) The final occlusal wafer splint is constructed using the casts positioned as they will be at the completion of surgery (Figure 4).




Figure 4. Articulator simulation with the KD-MMS system by Ehmer and Joos.
A. The situation before movement of the segments, red plate visible;
B. Movement of the upper jaw, white plaster indicates the position of the upper jaw;
C. Final position of both jaws, white plaster in each segment (courtesy of LKH Feldkirch)

3D Planning (Virtual surgical planning)

Virtual Surgical Planning (VSP), or computer-aided design/computer-aided manufacturing (CAD/CAM), is rapidly replacing conventional 2D model surgery. For VSP, the surgeon needs a cone beam CT (CBCT) with 3D reconstruction, which provides superior quality to plain radiographs, aligns the maxilla and the mandible in the appropriate relationship, eliminating the need for a facebow transfer and aligning the Frankfort horizontal plane, or Natural Horizontal Line to the maxilla and the mandible. The models are scanned by laser, and the digital data is combined with that obtained from the CBCT.

Afterwards an accurate 3D model is created, including the patient's maxillofacial skeleton, the dental arches and soft tissue. Model surgery is performed on the VSP software. This allows a computer assisted design and manufacturing of the required surgical splints (Hammoudeh et al., 2015; Levine et al., 2012). The ability of cone beam and/or medical CTs to capture the occlusal surfaces of the maxilla and mandible is limited, requiring additional scanning of occlusal surface of dental casts for integration into the DICOM images. Moreover, virtual maxillary segmental surgeries are currently not practicable (Figure 14) (Hammoudeh et al., 2015).

1.3.3 Surgical treatment

Indication

Patients who are affected by dentofacial deformities are often handicapped in two ways. First, jaw function is compromised, and second, dental and facial appearance often leads to discrimination in social interactions. (Miguel et al., 2014)

Often, the execution of solely orthodontic treatment that improves dental malocclusion is not able to correct the underlying skeletal problem. This is due to the fact that there are limits to

how far a tooth can be moved, and these limits become important when bite relationships must be changed to correct severe vertical and horizontal deformities. This is especially relevant for adults when modification of growth is no longer an option to correct the skeletal discrepancy.

Le Fort I

Rene Le Fort originally described the fracture pattern in 1901, named Le Fort I osteotomy, which extends from the nasal septum, along the tooth apices, and through the pterygomaxillary junction. The difference between the fracture pattern described by Le Fort and the osteotomy relates to the status of the pterygoid plates. The Le Fort I osteotomy spares the pterygoid plates by cutting at the pterygomaxillary junction. This osteotomy is commonly used for the correction of malocclusion and maxillomandibular deformities. It allows movements in all three planes and can be used to treat class II and III malocclusions, as well as dentofacial asymmetries. (Buchanan & Hyman, 2013)

To achieve a neutral head position, the patient is placed in a supine position with a shoulder roll. Prior to entering the oral cavity an external reference is established at the nasofrontal area. The desired vertical movements are measured via the outer reference. To minimize bleeding during the procedure, local anesthetic with epinephrine (2% lidocaine with 1:200 000 epinephrine) is infiltrated along the entire facial surface of the maxilla. Then the intraoral incision is made from the zygomaticomaxillary buttress region above the first molar to the midline of the maxilla bilaterally. Once through the mucosa and into the loose areolar tissue in the submucosal plane, dissection should proceed directly to the bone using a periosteal elevator. Dissection of the nasal mucosae should be mindful. The bone resection is carried out 4 mm above the root tips with an oscillating saw through the facial maxillary sinus walls. The nasal septum and lateral nasal wall are cut through on the level of the nasal floor with a septal chisel.

After final separation, the maxilla gets down-fractured with gentle pressure in the caudal direction and with the use of two mobilization forceps. The mobilization and segmentation of the maxilla follows the individual preoperative model surgery. In relation to the external reference points, the desired movements can be performed. Then the preoperatively fabricated surgical splints are inserted to ensure the correct positioning of the maxilla. Fixation of the maxilla in its new position is achieved with at least four L-shaped miniplates, two on each side (Figure 5). The occlusion and maxillary midline will be checked intraoperatively before fixation and additionally, vertical measurements are taken according to the reference points set initially to confirm the surgical plan was accurately executed. Following this, the incision is closed with an absorbable suture. (Buchanan & Hyman, 2013)

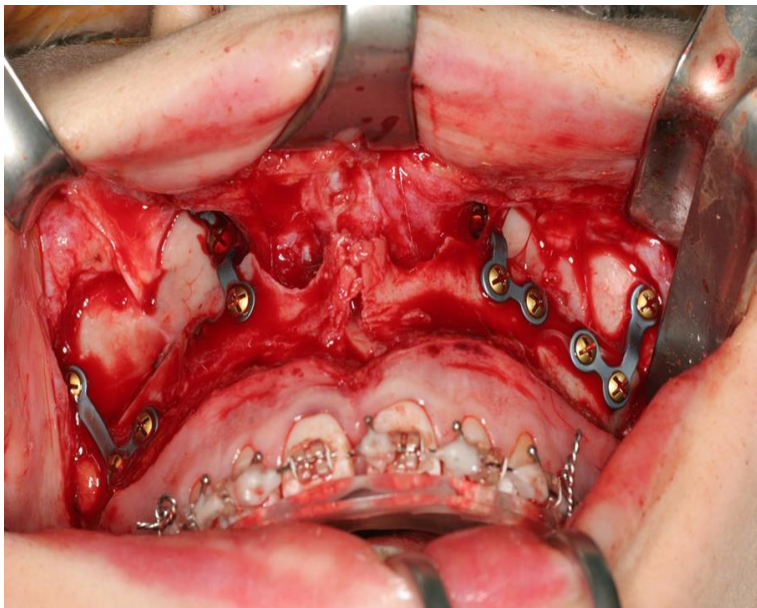


Figure 5. Le Fort I osteotomy. Fixation with 2.0 miniplates and screws done following osteotomy (courtesy of LKH Feldkirch)

Bilateral Sagittal Split Osteotomy (BSSO)

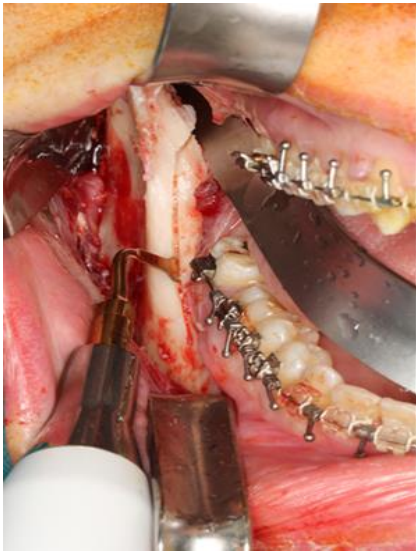The basic surgical concept of BSSO was originally described by Obwegeser (1965) with the remaining advantage of great flexibility in repositioning the distal tooth-bearing segment, broad bony overlap of the segments that ensures stable healing capability and minimal alterations in the positions of the muscles of mastication and the temporomandibular joint. With the aim of improving surgical convenience, minimizing morbidity, and maximizing procedural stability several modifications of the technique have been introduced over the last decades (Takahashi et al., 2010). These modifications include the technique described by Dal Pont (1959), who suggested increasing the surface of the buccal plate by extending it into the proximal mandibular body area (Böckmann et al., 2014).

In contrast to the past, many surgeons use the Hunsuck/Epker modification, which vary from the Obwegeser/Dal Pont procedure in the extent of the lingual osteotomy. The lingual plate osteotomy is extended to the area just posterior to the lingula rather than the whole width of the ramus. This technique has the advantage of reduced soft tissue dissection lingually, but it can cause difficulties when used for a backward sliding osteotomy (Böckmann et al., 2014; Huppa & Mack, 2017).

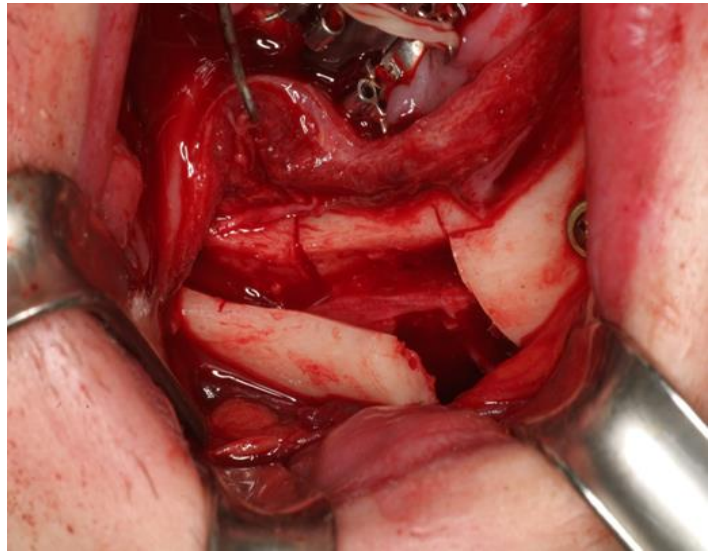
The BSSO is accomplished via an intraoral approach with an incision starting on the anterior aspect of the vertical ramus and carried inferiorly through the lateral aspect of the retromolar fossa to the buccal of the second or third molar. Periosteum and mucosa are reflected to expose the lateral cortex of the mandible. On the medial side, identification of the sigmoid notch superiorly, and the entrance of the neurovascular bundle to the lingual foramen inferiorly, is important. Splitting the distance between these two structures allows for an appropriate medial osteotomy. Using adequate retraction and irrigation, osteotomy is performed through single cortex from medial to lateral, using a choice of rotary, reciprocating or piezoelectric saw (Figure 6 – A). Observation of the neurovascular bundle is important when one is completing the lateral

bony cut. Bone separation is completed with careful use of specially designed osteotomes and separating pliers (Figure 6-B). If the nerve is encountered, it is carefully separated from the proximal segment, usually with a curette or a Woodson instrument. The procedure is completed bilaterally, and the mandible is passively advanced into the planned occlusion. Afterwards, the prefabricated surgical splint is applied, and osteosynthesis performed with miniplates and screws (Figure 6-C) (Takahashi et al., 2010). Intraoperative, heavy elastics are used for intermaxillary fixation before the osteosyntheses plates are applied. The proximal segment is pushed back in an upper most posterior position in the TMJ to avoid early relapse. After the fixation of the osteotomy and removal of the elastics, the occlusion will be checked.

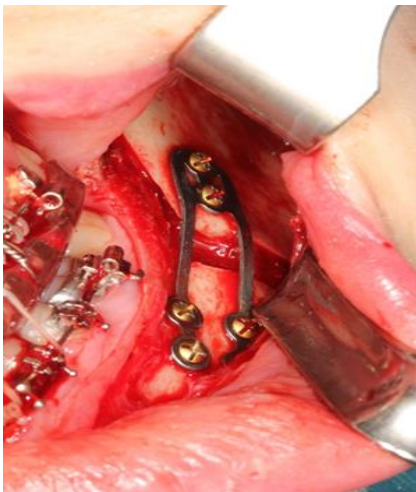A



B



C



D

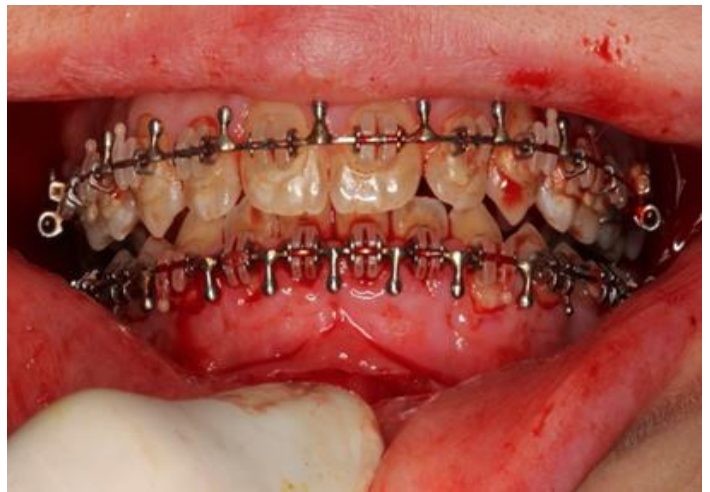

Figure 6. Intraoperative pictures of bilateral sagittal split osteotomy. A. osteotomy with piezoelectric device, B. splitting of bone segments, C. bone fixation with titanium plates, D. occlusal check (courtesy of LKH Feldkirch)

Expansion techniques (SARPE, 2-piece segment, 3-piece segment)

Surgical correction of maxillo-mandibular transverse discrepancies may be achieved by either segmental osteotomy or surgically assisted rapid palatal expansion (SARPE). Segmental osteotomy is the preferred choice for the correction of maxillo-mandibular transverse discrepancies when a single surgical procedure is planned to correct the maxillo-mandibular discrepancies. (Koudstaal et al., 2005). Normally, an orthodontist can manage transverse maxillomandibular discrepancies of less than 5 mm with orthopedic or orthodontic forces alone. When the transverse maxillomandibular discrepancy is greater than 5 mm, surgical assistance is necessary (Suri & Taneja, 2008). Although both SARPE and segmental osteotomy are used for surgically assisted maxillary expansion, segmental osteotomy is reported to be unstable, especially when there is desire for more than an 8 mm expansion (Woods et al., 1997).

The main indications for SARPE are skeletal maturity, correction of maxillary transverse deficiency (MTD), either unilateral or bilateral anterior crowding and buccal corridors. Besides, the indications for SARPE include any case where orthodontic maxillary expansion was not satisfactory and resistance of the sutures must be overcome. (Koudstaal et al., 2005)

Surgical technique

From a technical point of view, surgical treatment of dentoskeletal malformations has evolved from the use of rotating instruments and reciprocating saws to the use of piezoelectric devices (Labanca et al., 2008). Piezoelectric surgery is an innovative and soft tissue-sparing system for bone cutting based on ultrasonic microvibrations (Figure 6-A). The main advantages of piezoelectric surgery include soft tissue protection, optimal visibility in the surgical field, decreased blood loss, less vibration and noise, increased comfort for the patient, and protection of the tooth structure (Labanca et al., 2008; Pavlíková et al., 2011; Rude et al., 2019). Shock

waves in the fluid environment can lead to a reduction of bacteria and deliver a disinfecting effect (Walsh, 2007).

The principle of piezoelectric surgery is ultrasonic transduction, obtained by piezoelectric ceramic contraction and expansion. Thus, the vibrations obtained are amplified and transferred onto the insert of a drill, which results, in the cavitation phenomenon, with a mechanical cutting effect exclusively on mineralized tissues. The procedure is performed with slight pressure upon the bony tissue in the presence of irrigation with physiological solution. (Crosetti et al., 2009)

Microscopic examination of the cut bone has shown no signs of coagulative necrosis (M Robiony et al., 2007). Piezoelectric surgery has been used for minor orthodontic microsurgical procedures, as well as for orthognathic surgeries such as BSSO, SARPE and Le Fort I osteotomy (Landes et al., 2008; M Robiony et al., 2007). The main advantage of piezoelectric surgery during BSSO is the improved protection of the inferior alveolar nerve. Landes *et al.*, (2008) reported inferior alveolar nerve sensitivity was retained in 98% of cases, compared with 84% after conventional osteotomy patients, measured at three months postoperatively. Operation time remained the same and blood loss was reduced. Geha *et al.*, (2006) observed 75% to 80% recovery of inferior alveolar nerve sensory functions, measured by the pinprick test, light touch sensitivity and 2- point discrimination tests two months after BSSO performed by piezoelectric surgery. In a systematic review from Rude, Svensson and Starch-Jensen (2019), the neurosensory disturbances after BSSO varied from 1.8% to 23% with piezoelectric surgery and from 7.3% to 52.0% with conventional techniques after two to twelve months.

Osteosynthesis

There is a large spectrum of available systems for fixation of the segments of the mandible after BSSO. In general, two different techniques are presently used: 1) fixation using two or three bicortical position screws for fixation of the proximal segment, or 2) one or two mini plates with monocortical screws for fixation. When using the plating system, several types with different profile thickness exist; the rigidity ranges from rigid, semi-rigid to more or less flexible plates (Figure 7) (Huppa & Mack, 2017). Using the position screws, a trans-buccal approach is normally used, leaving tiny scars on the skin of the cheeks. These scars are usually inconspicuous, but cause cosmetic concern in some patients. Generally, surgeons always try to avoid scars on the face. Therefore, many surgeons nowadays perform the surgery entirely intraorally without the need for a trans-buccal approach. (Huppa & Mack, 2017; Luhr et al., 1991)



Figure 7 – A flexible osteosynthesis plate by Medartis (courtesy of Medartis)

1.3.4 Postsurgical orthodontic treatment

Stabilization of the skeletal movements and the refinement of the dental occlusion are the two primary goals during postsurgical orthodontic treatment.

Intermaxillary fixation with elastics will find application in the postoperative period to refine minor movements that need to occur and counterbalance the soft tissue pull that may lead to relapse. In traditional OGS, where the majority of dental decompensation occurs before surgery, the postoperative orthodontic period usually lasts between two to twelve months to refine the occlusion and evaluate possible relapse potential.

After end of treatment, especially patients who had symptoms of TMD preoperative or suffer from new-developed symptoms should receive close monitoring and if necessary additional support by physiotherapists.

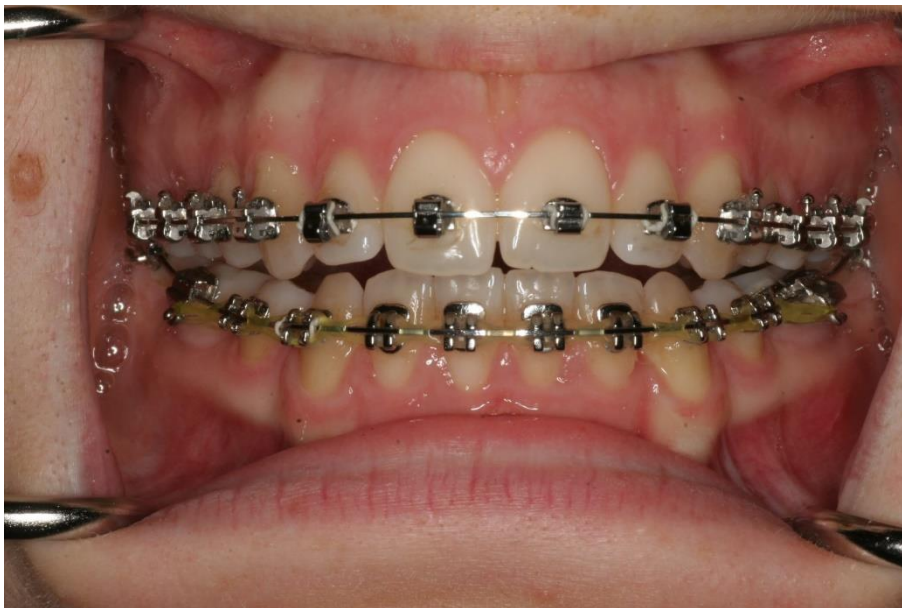

Figure 8. Use of fixed orthodontic appliance in pre-surgical orthodontic treatment phase after alignment of the upper and lower arch (courtesy of LKH Feldkirch)

2 Patients and Methods

The longitudinal cohort study was conducted at the Department of Oral and Maxillofacial Surgery, Academic Teaching Hospital, Feldkirch, Austria. For this study, a sample of 582 patients diagnosed with a skeletal dentofacial deformity and treated with OGS between 2006 and 2016, was composed. Moreover, the following additional inclusion criteria were applied: patients requiring BSSO or BSSO/Le Fort I in combination, an availability of complete clinical dataset, and at least two postoperative follow-ups at the Department. The following factors were applied as exclusion criteria: previous history of BSSO or Le Fort osteotomy, former facial trauma, cleft palate, syndromic deformities, and the presence of systemic joint disorders, neurological diseases, cervical spine alterations, facial paralysis, and previous TMJ surgery. Figure 9 gives an overview of the patient selection and drop-outs (n = 207). The study design was approved by the local ethics committee (number EK-2-2014/0016) and individually written consent was obtained from all subjects. The guidelines of the Declaration of Helsinki regarding human patients were read and respected.

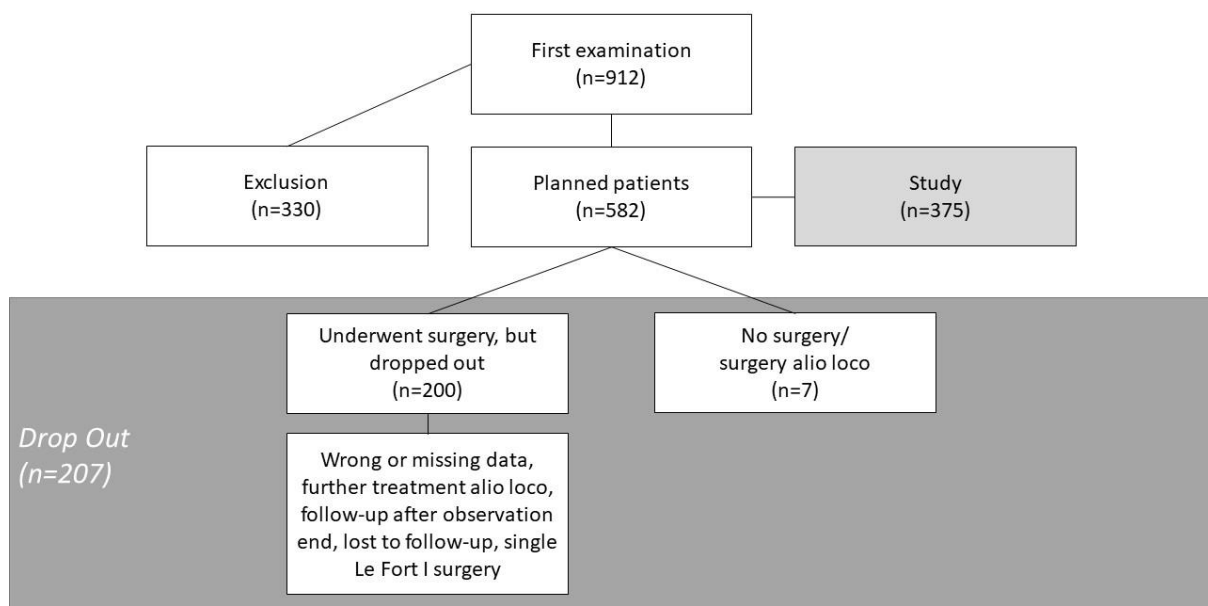


Figure 9. Chart showing patient selection

2.1 Outcome measures

Demographic variables were age at the time of initial examination and gender. Predictor variables included surgery (type of rotation of the maxillomandibular complex and the amount of advancement or setback of the mandibular segment) and skeletal variables (class II and class III). The primary outcome variables were TMJ functions (MMO, lateral excursion and protrusion) and signs and symptoms of TMD findings consisting of pain, crepitus and clicking. TMD data was categorized according to a modified Di by Helkimo (0 = no, 1 = slight, 2 = moderate, and 3 = severe dysfunction) (Table 2).

2.2 Study design

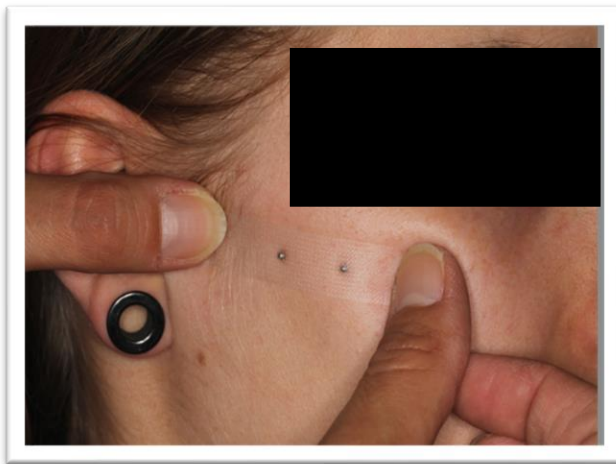2.2.1 Preoperative planning

All patients planned with conventional or virtual surgical planning followed the same procedure in the Department.

At the beginning of the planning consultation, a careful facial, aesthetic and occlusal analysis, and a physical examination were carried out to establish a correct diagnosis. This was done by two senior maxillofacial surgeons and two residents specialized in maxillofacial surgery. All patients until 2015 underwent conventional planning, and from 2016 onwards the patients undertook a VSP protocol. Impressions of the upper and lower jaw with a wax-bite were taken. The natural head position was defined using a laser light (Bosch PCL 1, Robert Bosch GmbH, Leinfelden-Echterdingen, Germany), and two radiopaque skin markers (CT-SPOT, Beekley Medical, diameter 2.3 mm, Bristol, USA) were placed on the displayed horizontal line of the face (Figure 10, Figure 11). A lateral and frontal photograph were taken in sitting position with the radiopaque markers kept leveled horizontally with the condyles seated in the joint, lips in relaxed position, and teeth in first tooth contact using a wax bite. Thereafter, a cone beam CT

(KaVo 3D eXam, KaVo Dental GmbH, Biberach, Germany) was performed in natural head position with the same bite registration and the same facial expression as for the photographs. The digital imaging and communications in medicine (DICOM) data were exported from the hospital's picture archiving and communication system (PACS) and imported into the software's database (Dolphin Imaging Software version 11.9; Dolphin Imaging and Management Solutions, Chatsworth, CA, USA) (Figure 12). Steinhuber *et al.*, 2018 summarized the schedules for the planning methods as a dental surgeon of the Department.

A



B

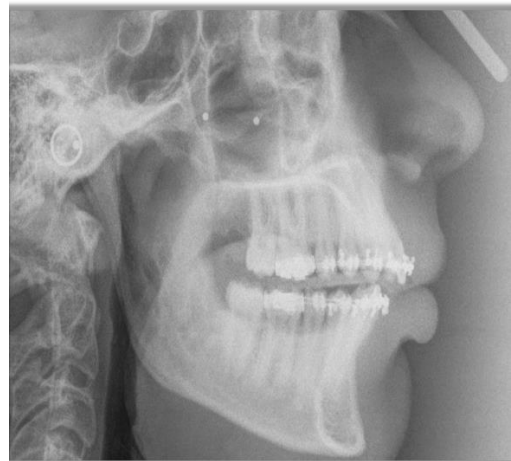


Figure 10. Use of radioopaque skin markers. A. placement of the markers. B. markers visible in radiograph (courtesy of LKH Feldkirch)

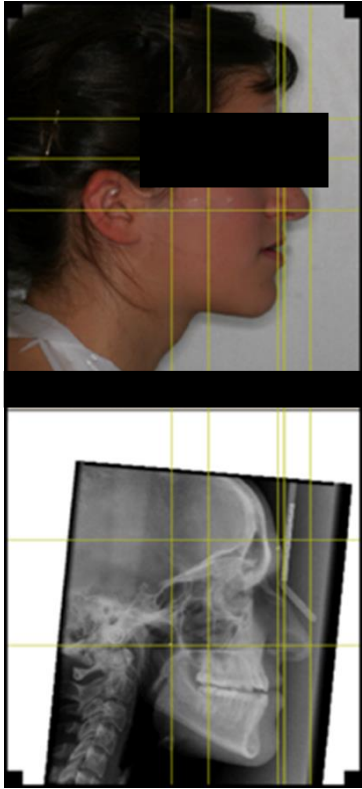


Figure 11. Patient in Natural Head Orientation (NHO) (courtesy of LKH Feldkirch)

Conventional surgical planning

An experienced resident of the department completed the 2-dimensional OGS planning until 2015. The intra- and extraoral photographs (closed, relaxed, smile from front and side), lateral and frontal cephalograms and a panoramic radiograph created from the CBCT data were imported into the Dolphin imaging database. For the analysis of the lateral cephalogram the standard landmarks were used. The facial photographs were superimposed onto the traced cephalogram. The final planning was completed by the senior surgeon based on the findings of the planning consultation. A laboratory technician prepared the manufactured casts and mounted them in an articulator (SAM IIP, SAM-Dental, Munich, Germany) using a double split cast system.

Office-based virtual surgical planning

For VSP, the impressions were poured in stone and trimmed. The upper and lower arch models were scanned separately and in final occlusion with a 3-dimensional scanner (Ortho Insight® Scanner, Mountain View, Chattanooga, TN), and saved as Stereolithography (STL) files by a dental technician of a local out-office laboratory. For VSP, the 3-dimensional module of the Dolphin Imaging software was used (version 11.9; Dolphin Imaging and Management Solutions, Chatsworth, CA). The CBCT images were imported (“import DICOM”) and the orientation of the CBCT volume was set to natural head position and corrected in the axial, frontal and sagittal plane (“set orientation”). Alignment of the frontal photograph in relaxed lip position to the CBCT data was established (“2D photo wrap”). After importing the virtual upper and lower arch models, the alignment between the CBCT volume and the models was carried out using a semi-automatic procedure, starting from a surface registration in selected zones where accurate tooth information was available in the CBCT images. If necessary, the result was further fine-tuned by manually moving and rotating the models while inspecting the overlap of the contours in the CBCT images. As a final quality check, the contours were inspected using the built-in colour mapping (“import models” and “edit models”). A panoramic X-ray was constructed from the CBCT images as provided for the VSP procedure (“build X-ray”)(Figure 13). Major areas involved in the surgery were located using the constructed panoramic X-ray (“setup”) and the CBCT volume (“crop”). Extraneous information was cut out of the volume (“clean-up”). Further steps in the VSP workflow included the definition of the osteotomies, digitizing soft tissue and skeletal landmarks (“osteotomy” and “landmarks”). After moving the segments according to the treatment plan, the final occlusion was achieved using the piggyback function (“treat”) and visualized 3-dimensionally on the monitor (“present”) (Figure 14). After virtual constructions of the intermediate (for double jaw surgery) and the final splint (“splint design”), an STL file was created and transferred to a local external

laboratory. In the case of a segmented osteotomy of the maxilla, the upper arch model was ultimately separated and fixed with wax, and then scanned. In their final position, the scanned models were superimposed onto the CBCT volume and the maxilla incisor tip was used as a reference point to superimpose the segmented maxilla models onto the CBCT volume. (Steinhuber et al., 2018)

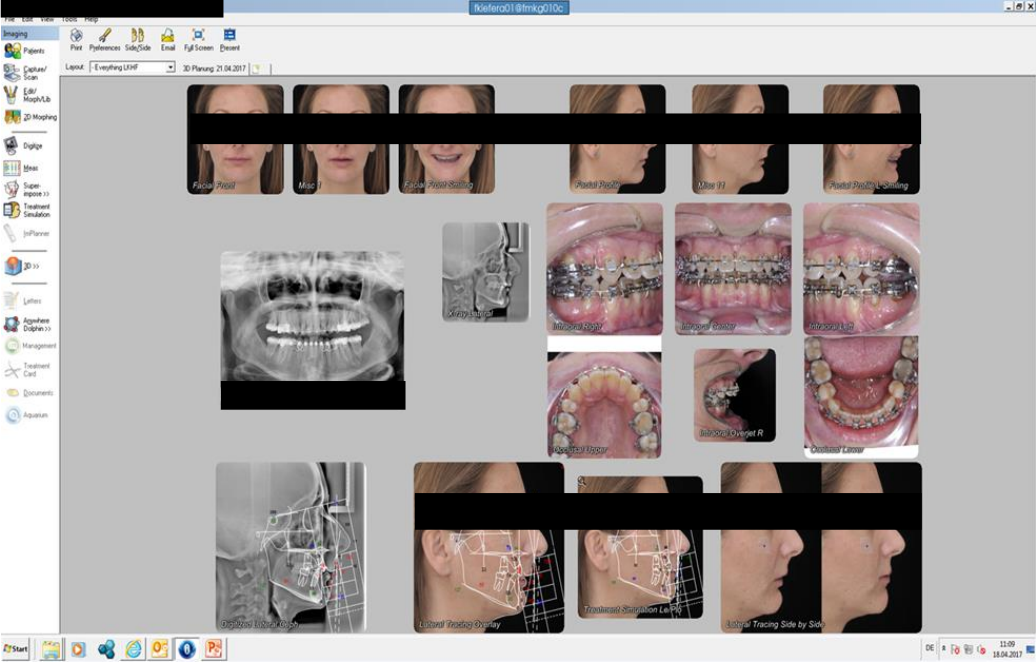


Figure 12. Patient digital photographs imported into Dolphin orthognathic surgery planning software (courtesy of LKH Feldkirch)

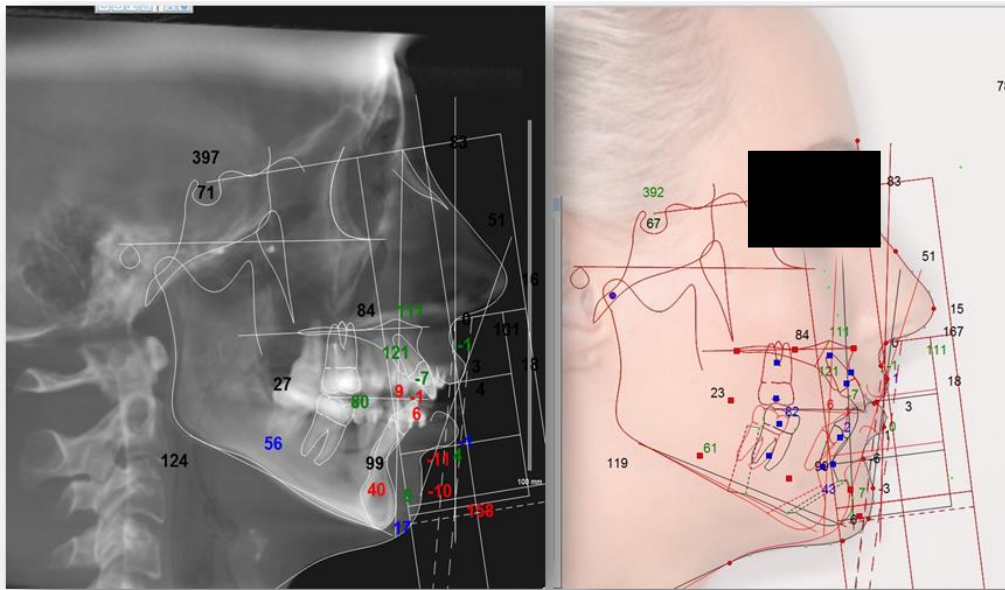


Figure 13. 2D planning. Without soft tissue imposition and as a soft tissue overlay (courtesy of LKH Feldkirch)

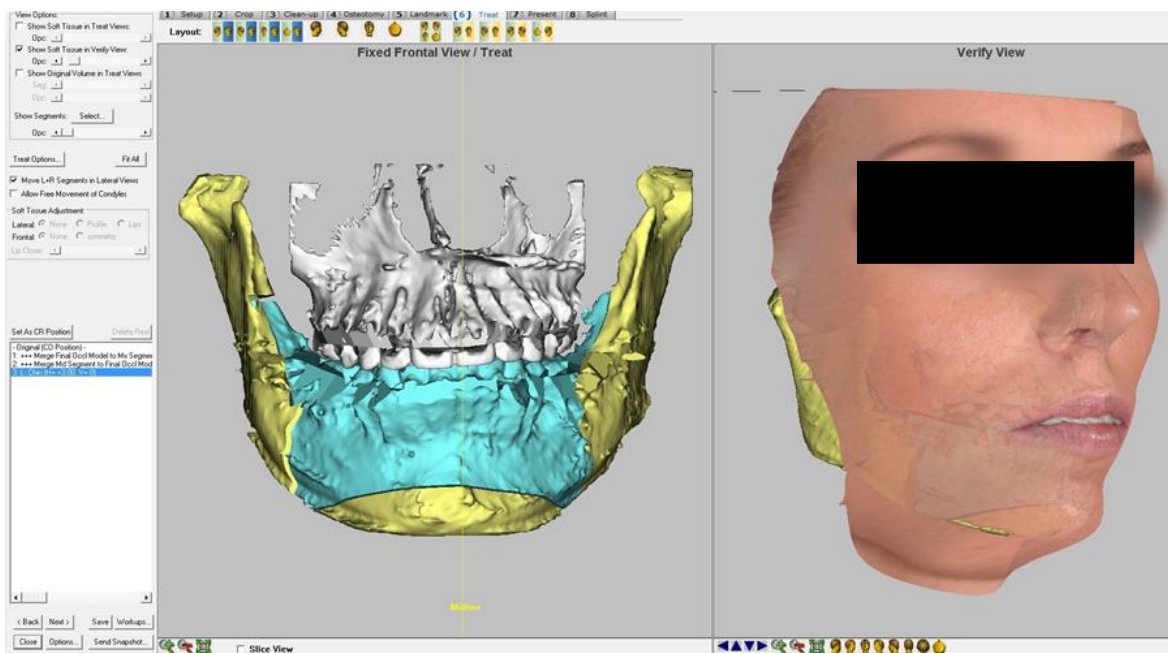


Figure 14. 3D planning. The tooth-bearing segment is indicated blue and the condyles yellow. The blue segment will be moved forward to the final dental occlusion. Changes to facial appearance are visualized on the overlay of the pictures (courtesy of LKH Feldkirch)

CAD/CAM-Fabrication of surgical splints

The splint data files were imported to the software of the milling machine (Ceramill Inhouse Digital 300; Amann Girrbach, Götzis, Austria) by a dental technician of a local external laboratory (Figure 15). After post-processing and conversion of the datasets into STL files for the machine, the splints were fabricated from a polymethylmethacrylate (PMMA) block (Ceramill Splintec Standard 71, Amann Girrbach, Götzis, Austria) by a five-axis wet-milling unit (Ceramill Motion 2, Amann Girrbach, Götzis, Austria). The steps include data export and import, thresholding, processing, cross-checking, uploading of STL files and administration by the laboratory technician.

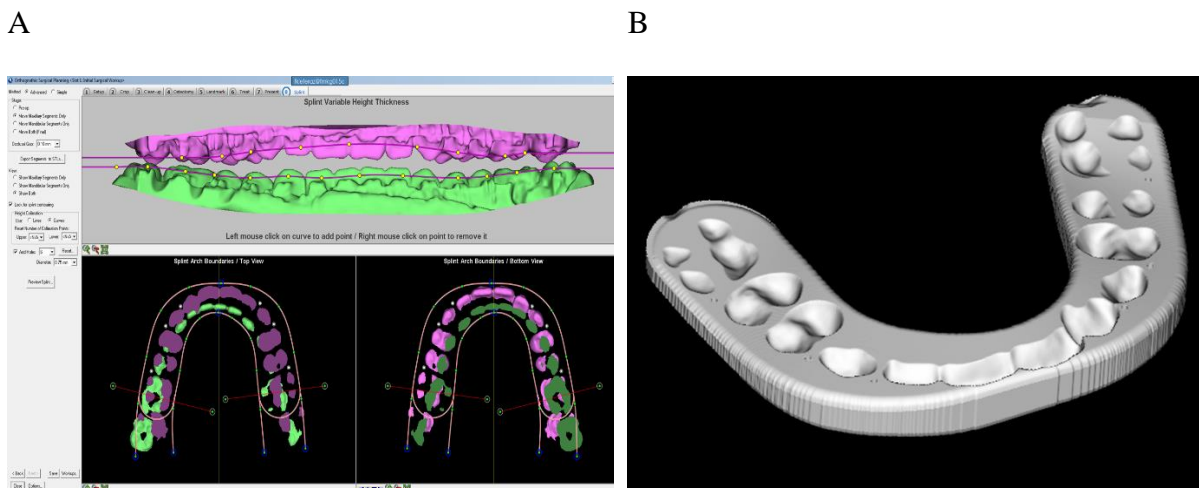


Figure 15. Computer-aided design to fabricate the surgical splint. A. wafer design. B. 3D-view of the splint (courtesy of LKH Feldkirch)

2.2.2 Surgical technique

All patients were operated on by one senior surgeon on one side and by one junior surgeon on the opposite side, using the same surgical technique.

In case of a Le Fort I osteotomy, the osteotomy was performed using a microsaw (Elan 4, Aesculap, Tuttlingen, Germany) at the lateral maxillary buttress and directed to the ipsilateral piriform rim. On the contralateral side the steps followed the same pattern. To complete the posterior osteotomies of the lateral and medial maxillary buttresses a thin osteotome, while for the following separation of the nasal septum from the maxilla a U-shaped osteotome was used. The lateral nasal wall and the posterior maxillary wall was then also fractured with an osteotome. Furthermore, the pterygomaxillary junction was separated with a curved osteotome. To ensure the proper position, the medial extent of this osteotomy was palpated by fingers inside the mouth by feeling the hamulus. Once the osteotomies are completed, the down fracture is performed with digital pressure. Mobilization of the maxilla is done with mobilization forceps. If impaction was planned, the appropriate amount of anterior maxillary bone, septum, and vomer should be reduced. Bone grafts are inserted to provide more stable movements. The external reference points measured preoperatively are used for orientation purposes of the planned movements. Then the surgical splint is used to position the maxilla by placing the patient in maxillomandibular fixation using elastics. The proper position of the maxilla is fixed with titanium plates and screws. For the fixation of the upper jaw, two L-shaped miniplates were attached on each side (ModusOSS 2.0, Medartis, Basel, Switzerland). They are individualized by the surgeon in an orientation that ensures the desired position of the maxilla. In the lower jaw, the BSSO was performed according to the modified technique by Hunsuck (Hunsuck, 1968). In all cases, the splitting technique was performed using a piezoelectronic device with a round cutting tip (Piezoelectric system, DePuy Synthes, Solothurn, Switzerland). Physiological sodium chloride solution was used for irrigation at room temperature

(approximately 20°-21°C). For all osteotomies, the machine was adjusted to “bone - quality 1” and the water pump was set at 120 ml per minute. For completion of the sagittal split the segments were physically separated by using a 6-mm osteome (KLS Martin, Tuttlingen, Germany), a 6-mm chisel (Lexer International, Sialkot, Pakistan) and a Smith-separator (KLS Martin, Tuttlingen, Germany). Care was taken to ensure that the chisels were in constant contact with the inner side of the vestibular cortical bone. The inferior alveolar nerve and osseous surfaces were inspected macroscopically for damage (i.e. without magnification). After repositioning the mandible by using a surgical splint and manual repositioning of the proximal segment into the correct position (i.e. seated condyle position), fixation was performed using a single 2.0 mm osteosynthesis plate, and 5-mm-long screws (ModusOSS 2.0, Medartis, Basel, Switzerland). The intraoperative wafers were stabilized to the maxillary arch with wires placed through the buccal flange of the splint and around the adjacent orthodontic brackets on the teeth. In case of counterclockwise rotation of the MMC the mandible was operated on first, utilizing a BSSO. In all other cases (CR or without rotational changes of the MMC) the upper jaw was operated on first. The wafers and intermaxillary fixation with elastics were only used intraoperatively.

2.2.3 Postoperative follow-up

Immediately after surgery, patients were instructed to use guiding elastics (Bugtastic Latex Cricket 4.8 mm x-heavy or Spider 6.4 mm x-heavy, Dentsply International Raintree Essix, Sarasota, US) for two weeks, depending on the respective surgery. For advancement class II and for setback of the mandible class III elastics were used. All patients were instructed by the surgeon to perform the home-stretching exercises two weeks after surgery. The patient visited the surgeon and/or orthodontist every alternate week until week six to check the occlusion,

patient progress, and make any indicated changes in the elastic or orthodontic mechanics to maximize occlusal inter-relationship. A soft diet was maintained for the first six weeks after surgery. Thereafter, patients began progression to normal food consistency and safely loading the jaw structures with normal masticatory forces. Radiographic assessments (orthopantomogram, lateral- and posteroanterior cephalometric radiographs) were performed at each timepoint (T0 to T4).

2.3 Evaluation and data collection

Patients were clinically evaluated at five timepoints; pre-surgery (T0), postoperatively at six weeks (T1), six months (T2), one (T3), and two years (T4). At each timepoint (T0-T4) the clinical examination was performed by the oral and maxillofacial surgeons of the Departement. Before orthodontic treatment had started, the first examination took place. The evaluation consisted of occlusal classification according to Angle and the assessment of the overjet, overbite, MMO, lateral and protrusive movements, pain while moving the jaw (temporary or permanent), palpation and auscultation of the joints, and palpation of the masticatory muscles. The underlying deformity was assessed on lateral cephalograms and the evaluation of WITS value.

During the initial consultation the history of present illness including TMD-related symptom location, onset of occurrence (permanent/temporary) as well as alleviating or aggravating factors were reviewed. The physical examination of TMJ function (maximum mouth opening, lateral and protrusive movements) was done with the patient in a supine position and was assessed using measurements with a caliper in millimeter. Objective signs of TMD (such as TMJ sounds including clicking and crepitation) and subjective symptoms (such as pain at rest or palpatory tenderness of the masticatory muscles or of the TMJ area) were registered and categorized with yes/no answers.

All data (sex, age, skeletal class, type of surgery, type and amount of movement) were entered into selected fields of a database (FrontEnd_Kiefer licensed to O. Ploder) created using Microsoft Access® (2007, Microsoft Corp, WA, USA) to ensure consistent data collection at each timepoint (Figure 16 - Figure 19). This database was programmed with interfaces for preoperative and postoperative follow-ups to avoid missing, invalid or incorrect data. Preoperative, a summary of orthodontic and surgical planning was individually added at “orthodontic findings and therapy proposal”. The interface at T0 included the anamnesis, detailed medical history, and chief complaint of the patient.

The third part of the interfaces documented the TMJ function (yes/no). TMJ function represents the results of the statistical analyses regarding “at least one clinical symptom” and was set at “yes” if the patient suffered from at least one clinical TMJ symptom (temporary or permanent pain, clicking, crepitus, or incisal edge distance < 35 mm).

The calculated score and the resulting Helkimoindex (A_i/D_i) were added directly below (Table 2). At the end of the interface the examiner entered the measured values of incisal edge distance, laterotrusion, protrusion, overjet, overbite, septum deviation and deviation during mouth opening as well as individual comments if needed.

Moreover, the postoperative interface contained further informations about paraesthesia, haematoma, and the occlusion (class I/II/III) left and right of the canines and of the first molars. Patient’s digital photographs (intra- and extraoral), cephalometric measurements and planning were managed with Dolphin Imaging Software (version 11.9; Dolphin Imaging and Management Solutions, Chatsworth, CA, USA).

KFO-Erstuntersuchung

Erstuntersuchung

Name:

Untersucher:

Datum:

Zuweiser:

Zuweisungsgrund:

Gesundheitsfragebogen:

Röntgen und Modelle: SKL ja nein

Diagnose:

Kieferorthopädischer Befund und Therapievorschlag:

Chief complaint:

Was stört den Patient/in hauptsächlich:

Ästhetik: Zähne Gesicht andere

Funktion: Essen Sprechen andere

Schmerzen: Kiefergelenk Muskel andere

Hatte der Patient eine KFO-Vorbehandlung:

Ja Nein abnehmbar festsitzend

Hatte der Patient einen chirurgischen Eingriff im Gesicht:

Ja Nein wenn ja, welche

Familienanamnese: Dysgnathie oder angeborene Anomalien

Ja Nein Verwandtschaft

Unfall mit Schädelbeteiligung:

Ja Nein dentoalveolär UK-Fraktur OK-Fraktur KG-Fraktur

Mittelgesicht Frontobasis Sonstige

Kiefergelenksfunktion: Probleme wenn ja, welche: immer temporär Knacken re li

Reiben re li

Schmerzen re li

Helkimo Index: Ai Di Punkte: VAS

SKD: mm Protusion: mm Overjet: mm

Laterotrusion: mm (re) mm (li) Overbite: mm

Deflexion Deviation nach re li in mm Kommentar:

Parafunktionen: Daumenlutschen Mundatmen Zungenpressen Sprache

Ja Nein

Besonderheiten (Weichteilsituation, Syndrom, Myoarthropathie, Wachstum):

Figure 16. Screenshot of the database (Frontend_Kiefer® licensed to O. Ploder). Selected fields of the first exam prior to orthodontic treatment. Timepoint T0 (courtesy of Prof. Ploder)

KFO-Kontrolle

Kontrolle

Name:

Untersucher:

Datum:

andere
 6 Wochen
 6 Monate
 12 Monate
 24 Monate

OPTG Tsd Foto postoperativ

	Normästhesie	re	li	Parästhesie
Wange	<input checked="" type="checkbox"/>	100	100	<input type="checkbox"/>
Nase	<input checked="" type="checkbox"/>	100	100	<input type="checkbox"/>
Oberlippe	<input checked="" type="checkbox"/>	100	100	<input type="checkbox"/>
Unterlippe	<input checked="" type="checkbox"/>	100	100	<input type="checkbox"/>
Kinn	<input type="checkbox"/>	90	90	<input type="checkbox"/>

Hämatom:

Okklusion

	re	li
Klasse I	<input checked="" type="checkbox"/>	<input checked="" type="checkbox"/>
Klasse II	<input type="checkbox"/>	<input type="checkbox"/>
Klasse III	<input type="checkbox"/>	<input type="checkbox"/>

Eckzahn

	re	li
	<input checked="" type="checkbox"/>	<input checked="" type="checkbox"/>
	<input type="checkbox"/>	<input type="checkbox"/>
	<input type="checkbox"/>	<input type="checkbox"/>

Molaren

	re	li
	<input checked="" type="checkbox"/>	<input checked="" type="checkbox"/>
	<input type="checkbox"/>	<input type="checkbox"/>
	<input type="checkbox"/>	<input type="checkbox"/>

Kiefergelenksbeschwerden: Ja Nein

temporär permanent Schmerzen re li
 permanent Knacken re li
Reiben re li
SKD < 35 mm

VAS:

wenn ja, welche:

Helkimo Index: Ai Di

Punkte:

SKD: mm Protrusion: mm

Laterotrusion: mm (re) mm (li) Overjet: mm

Overbite: mm

Deflexion Deviation nach re li in mm Kommentar:

Septumdeviation: Ja Nein um mm nach re li

Sonstige:

Kommentar:

Figure 17. Screenshot of the database (Frontend_Kiefer® licensed to O. Ploder). Selected fields of the exam six months after orthognathic surgery. Timepoint T2 (courtesy of Prof. Ploder)

Kontrolle

Name:

Untersucher:

Datum:

andere
 6 Wochen
 6 Monate
 12 Monate
 24 Monate

OPTG Tsd Foto postoperativ

	Normästhesie	re	li	Parästhesie
Wange	<input type="checkbox"/>	<input type="text"/>	<input type="text"/>	<input type="checkbox"/>
Nase	<input type="checkbox"/>	<input type="text"/>	<input type="text"/>	<input type="checkbox"/>
Oberlippe	<input type="checkbox"/>	<input type="text"/>	<input type="text"/>	<input type="checkbox"/>
Unterlippe	<input type="checkbox"/>	<input type="text"/>	<input type="text"/>	<input type="checkbox"/>
Kinn	<input type="checkbox"/>	<input type="text"/>	<input type="text"/>	<input type="checkbox"/>

Hämatom:

Okklusion

	Klasse I	re	li
Eckzahn	<input type="checkbox"/>	<input type="text"/>	<input type="text"/>
Molaren	<input type="checkbox"/>	<input type="text"/>	<input type="text"/>
	<input type="checkbox"/>	<input type="text"/>	<input type="text"/>
	<input type="checkbox"/>	<input type="text"/>	<input type="text"/>

Kiefergelenksbeschwerden: Ja Nein

temporär Schmerzen re li
 permanent Knacken re li
 Reiben re li
 SKD < 35 mm

wenn ja, welche:

Helkimo Index: Ai Di Punkte:
 SKD: mm Protrusion: mm Overjet: mm
 Laterotrusion: mm (re) mm (li) Overbite: mm

Deflexion Deviation nach re li in mm Kommentar:

Septumdeviation: Ja Nein um mm nach re li

Sonstige:

Kommentar:

Figure 18. Screenshot of the database (Frontend_Kiefer® licensed to O. Ploder). Selected fields of the exam twelve months after orthognathic surgery. Timepoint T3 (courtesy of Prof. Ploder)

Kontrolle

Name:

Untersucher:

Datum:

andere
 6 Wochen
 6 Monate
 12 Monate
 24 Monate

OPTG Tsd Foto postoperativ

	Normästhesie	re	li	Parästhesie
Wange	<input checked="" type="checkbox"/>	100	100	<input type="checkbox"/>
Nase	<input checked="" type="checkbox"/>	100	100	<input type="checkbox"/>
Oberlippe	<input checked="" type="checkbox"/>	100	100	<input type="checkbox"/>
Unterlippe	<input checked="" type="checkbox"/>	100	100	<input type="checkbox"/>
Kinn	<input checked="" type="checkbox"/>	100	100	<input type="checkbox"/>

Hämatom:

Okklusion

	Klasse I	re	li
Eckzahn	<input checked="" type="checkbox"/>	<input checked="" type="checkbox"/>	<input checked="" type="checkbox"/>
Molaren	<input checked="" type="checkbox"/>	<input checked="" type="checkbox"/>	<input checked="" type="checkbox"/>
	<input type="checkbox"/>	<input type="checkbox"/>	<input type="checkbox"/>
	<input type="checkbox"/>	<input type="checkbox"/>	<input type="checkbox"/>

Kiefergelenksbeschwerden: Ja Nein

temporär permanent
 Schmerzen: re li
 Knacken: re li
 Reiben: re li
 SKD < 35 mm:

VAS:

wenn ja, welche:

Helkimo Index: Ai Di

Punkte:

SKD: mm Protrusion: mm

Laterotrusion: mm (re) mm (li) Overjet: mm

Overbite: mm

Deflexion Deviation nach re li in mm Kommentar:

Septumdeviation: Ja Nein um mm nach re li

Sonstige:

Kommentar:

Figure 19. Screenshot of the database (Frontend_Kiefer® licensed to O. Ploder). Selected fields of the exam 24 months after orthognathic surgery. Timepoint T4 (courtesy of Prof. Ploder)

2.4 Helkimo Index

The examination of the “Clinical Dysfunction” was calculated with a modified version of Helkimo’s dysfunction index to enable clear and fast results during all follow-ups. The clinical examination included the measurement of the incisal edge distance, deviation of the mandible, dysfunction of TMJ and pain (permanent or temporary). There was no distinction between pain arising from TMJ, from preauricular region or from masticatory muscles. The assigned scores of the five criteria were summed up. A high Helkimo score (10 to 25 points) stands for severe (Di3), while Di2 (5 to 9 points) for moderate, and Di1 (1 to 4 points) for light disorders. Patients without any symptoms have a Di of 0. The individual Helkimo score was calculated as follows (Table 2).

Table 2. Clinical assessment of Helkimo score

Mouth opening (mm)	Deviation (mm)	TMJ function	Pain	Permanent or temporary	Helkimo Score
> 40	< 2	No impairment	No pain	No pain	0
30 - 40	2 – 5	Palpable clicking, crepitus	Palpable pain	temporary	1
≤ 30	> 5	Clicking, locking and luxation	Palpebral reflex	permanent	5

2.5 Statistical analysis

For the statistical evaluation, all parameters from the database were exported into an Excel spreadsheet (Excel[®] 2010, Microsoft Corp, WA, USA), which was transferred to the R program (version 3.5.2. R Foundation for Statistical Computing, Vienna, Austria) after having checked the entire dataset and an individual script was written. Continuous variables are presented as mean and standard deviation, if not indicated otherwise. Frequency tables for qualitative variables, means, and SDs for quantitative variables were calculated and displayed in tables and charts. For lateral excursion the average from left and right was determined. The values from left and right were combined in order to ensure greater clarity of presentation. Patients with pain, clicking or crepitus on both sides were summarized as one, and summed up with patients with symptoms on only one side. The basic data from the clinical examination was categorized according to the clinical dysfunction index into two groups: Di0/1 and Di2/3. Moreover, the amount of mandibular advancement after BSSO was categorized into two groups: < 7 mm and ≥ 7 mm. To measure the bivariate association between TMD and the relevant study variables collected (age, gender, skeletal class, type of surgery, type of rotation of the MMC, amount of advancement of the mandible, pain, clicking, crepitus, and TMJ function) the Student t-test, χ^2 , and the Fisher exact-test were computed and a binomial logistic regression model was created. The McNemar χ^2 test was used to test the independence of a 2x3 contingency table of paired variables (Di, TMD symptoms) before and after OGS. Statistical significance was defined at $P < .05$.

3 Results

3.1 Descriptive statistics

In a total number of 582 patients undergoing OGS, 375 (247 female and 128 male patients; mean age, 28.1 ± 9.4 years, range from 15.9 to 69.6 years) met the inclusion criteria. 317 visited the follow-up at T1, 291 at T2, 222 at T3 and 146 at T4, respectively. Most patients ($n = 202$, 53.9%) had been treated with a combined Le Fort I osteotomy and BSSO, whereas 173 (46.1%) were treated with sole BSSO. In 39 patients, a segmented osteotomy of the maxilla was additionally performed. Detailed descriptive statistics are presented in Table 3.

Table 3. Descriptive statistics

Descriptive statistics		Sample Size (n)	Percentage (%)
Sample Size		375	
Gender	male	128	34.1
	female	247	65.9
Skeletal class	I and II	269	71.7
	III	106	28.3
Advancement	overall	319	85.0
Amount of advancement	< 7 mm	208	65.2
	≥ 7 mm	111	34.8
Setback	overall	48	15.0
Rotation of the MMC	no rotation	258	68.8
	clockwise	76	20.3
	counterclockwise	41	10.9

Abbreviations: MMC = maxillomandibular complex

3.2 TMJ function

Functional and clinical parameters and symptoms of the TMJ before and after OGS are displayed in Table 4. Lateral excursion from left and right were summarized as mean excursion. The results show that MMO was significantly reduced at timepoints T1 to T3, and lateral excursions differed significantly at all moments when compared to the preoperative baseline values. Protrusion was significantly reduced at timepoint T1 and T2. MMO and protrusion have returned to normal at T4.

Table 4. TMJ function before and after orthognathic surgery (MMO, excursion, protrusion)

in mm	T0	T1	T2	T3	T4
	n = 375	n = 317	n = 291	n = 222	n = 146
MMO	47.2 ± 6.4	30.9 ± 7.2**	43.6 ± 7.1**	45.1 ± 6.7**	46.7 ± 6.7
Excursion	10.4 ± 2.4	6.4 ± 2.6**	9.0 ± 2.5**	9.3 ± 2.3**	9.7 ± 2.2**
Protrusion	7.2 ± 2.3	4.5 ± 2.0**	6.7 ± 2.0**	7.1 ± 2.1	7.3 ± 1.8

Abbreviations: MMO = Maximal mouth opening, T0 = preoperative, T1 = six weeks, T2 = six months, T3 = twelve months, T4 = two years, **statistically significant $P < .001$

The TMJ functions (MMO, lateral excursion left and right, and protrusion) before and after OGS are displayed in Figure 20 to Figure 23.

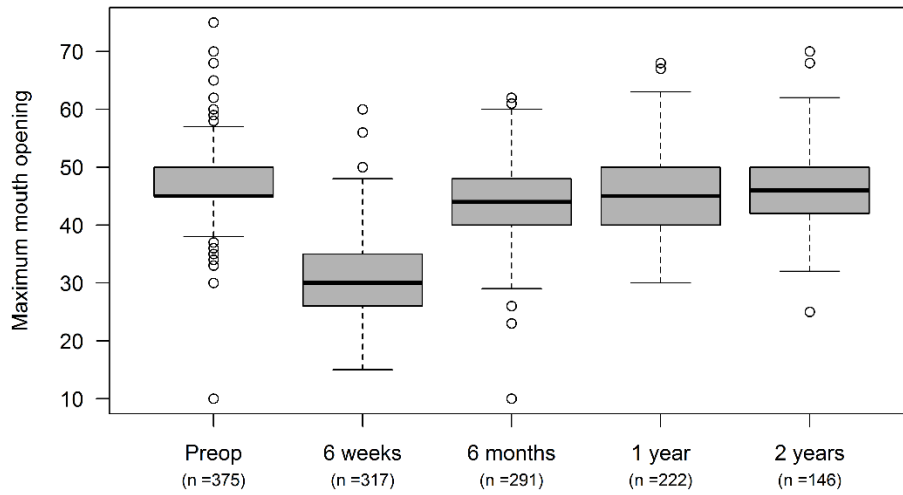


Figure 20. Maximum mouth opening before and after orthognathic surgery (mm)

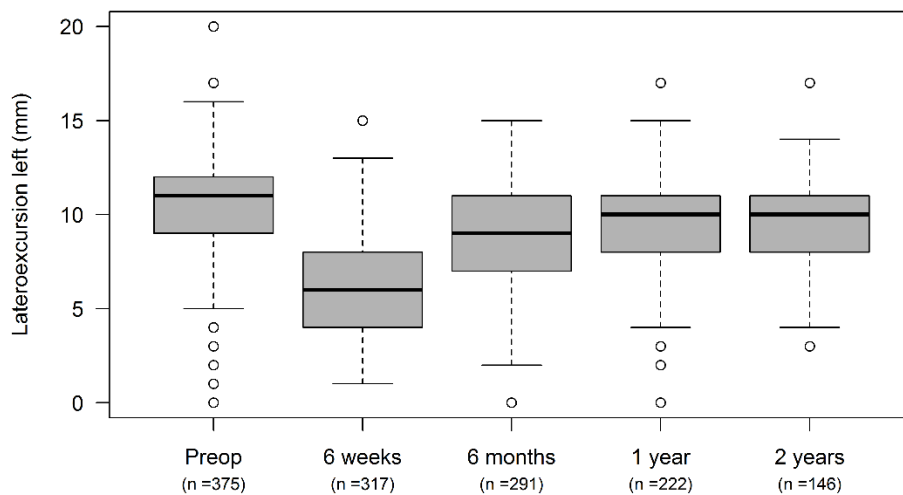


Figure 21. Lateral excursion left side before and after orthognathic surgery

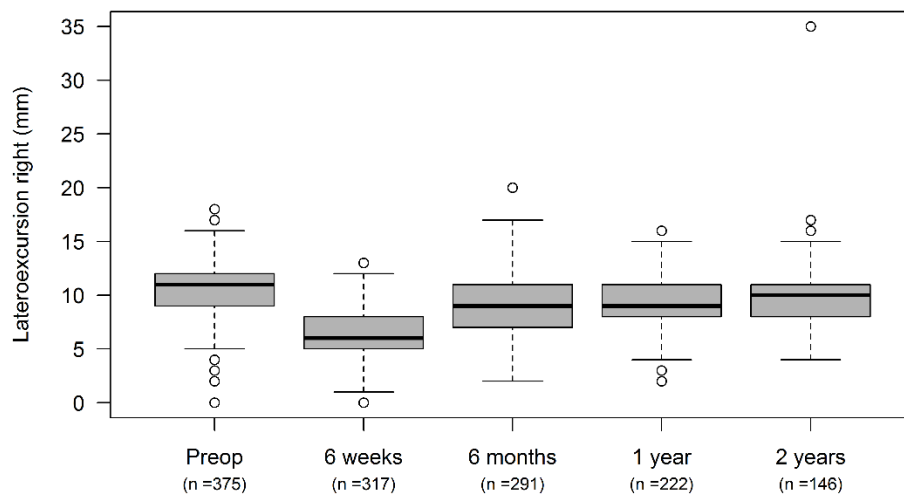


Figure 22. Lateral excursion right side before and after orthognathic surgery

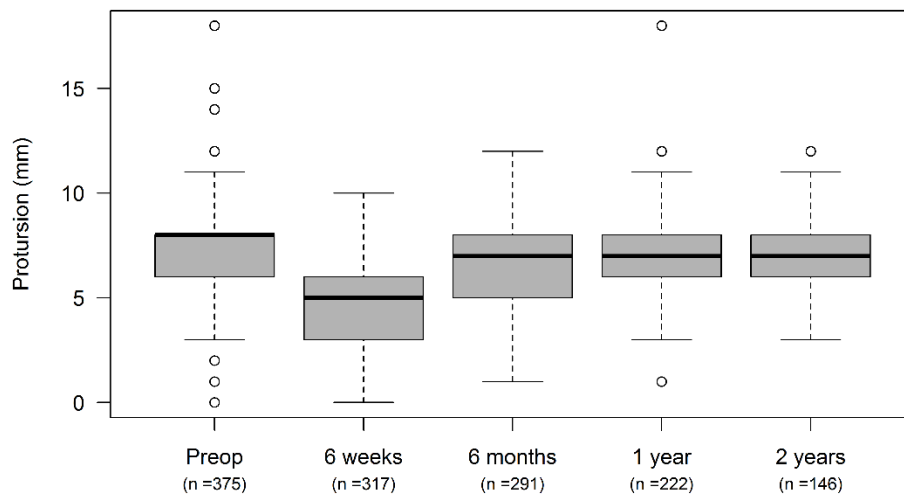


Figure 23. Protrusion before and after orthognathic surgery

3.3 Clinical signs and symptoms

Our results show that there are risk factors for short-term TMD symptoms, but no predictors could be identified for long-term TMD problems.

The evaluation showed that female patients had statistically significant more TMD symptoms (at least one symptom: 39.7%) and clicking (28.7%) before OGS ($P = .009$, $P = .016$, respectively). Moreover, female patients had more severe dysfunctions Di 2/3 (7.7%). As the latter subgroup benefited more from OGS in terms of long-term relief of TMD findings, the gender difference was only evident at the first timepoints T1 and T2 after OGS ($P = .042$; $P = .015$, respectively).

Of the 44 patients with pain at T0, 34 (77.3%) reported no pain, however, ten (22.7%) still reported pain after six months. Of the twelve patients belonging to the initial group with pain at T0, who were still included in the study at T4, eight patients (66.7%) were relieved from pain while four patients (33.3%) still complained of pain.

The prevalence of patients with clinical finding (pain, clicking or crepitus) and the frequencies of these symptoms at the respective timepoints are displayed in Table 5. Regarding each clinical sign, only the difference of clicking between pre- and post-treatment after six weeks was statistically significant ($P < .001$). Additionally, there was a statistical significance six weeks and two years postoperative for suffering from at least one sign of TMD ($P < .001$, $P = .028$). The relative frequencies of pain, clicking and crepitus are displayed in Figure 24, Figure 25, Figure 26.

Table 5. TMD symptoms (pain, clicking, crepitus) before and after orthognathic surgery

	T0 (n = 375)		T1 (n = 317)		T2 (n = 291)		T3 (n = 222)		T4 (n = 146)	
	yes	no	yes	no	yes	no	yes	no	yes	no
Pain	51 (13.6%)	324 (86.4%)	45(14.2%)	272 (85.8%)	29 (10.0%)	262 (90.0%)	23 (10.4%)	199 (89.6%)	15 (10.3%)	131 (89.7%)
Clicking	93 (24.8%)	282 (75.2%)	37 (11.7%)**	280 (88.3%)	57 (19.6%)	234 (80.4%)	50 (22.5%)	172 (77.5%)	30 (20.5%)	116 (79.5%)
Crepitus	5 (1.3%)	370 (98.7%)	1 (0.3%)	316 (99.7%)	7 (2.4%)	284 (97.6%)	9 (4.1%)	213 (95.9%)	6 (4.1%)	140 (95.9%)

Abbreviations: T0 = preoperative; T1 = six weeks; T2 = six months; T3 = one year; T4 = two years postoperative, ** statistically significant $P < .001$; * statistically significant $P < .05$

The relative frequencies of pain before and after OGS are displayed in Figure 24.

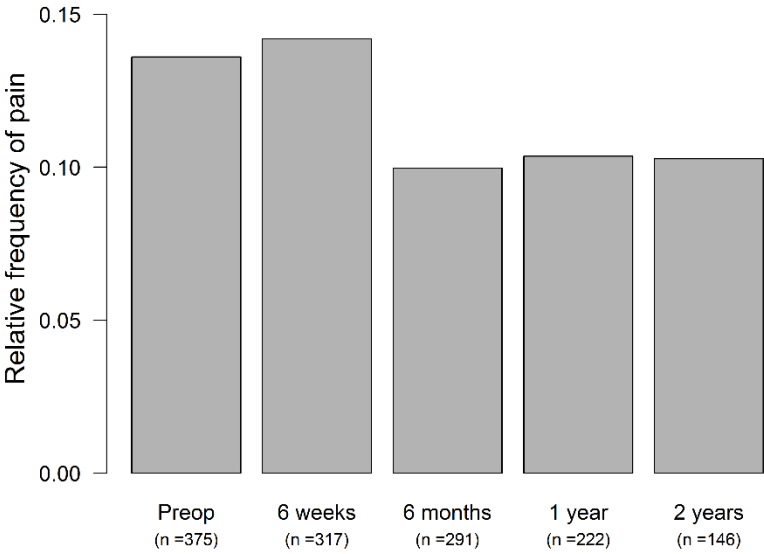


Figure 24. Relative frequency of pain before and after orthognathic surgery

The relative frequencies of clicking before and after OGS are displayed in Figure 25

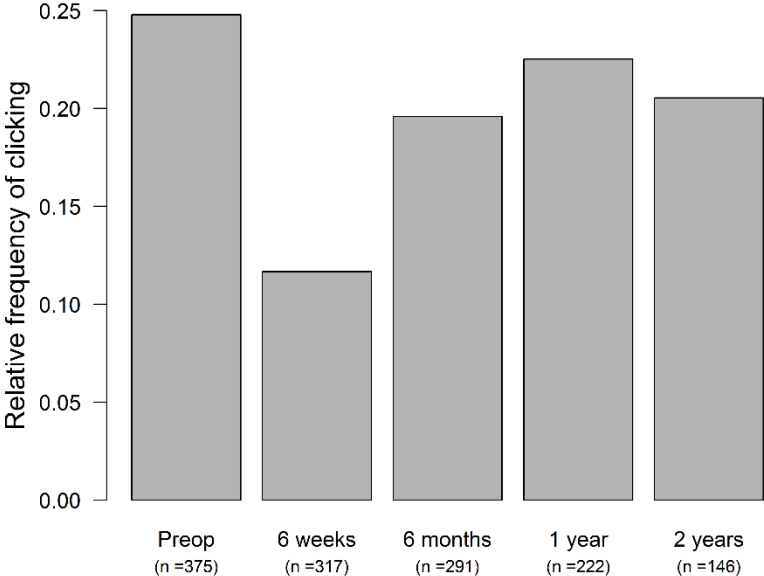


Figure 25. Relative frequencies of clicking before and after orthognathic surgery

The relative frequencies of crepitus before and after OGS are displayed in Figure 26.

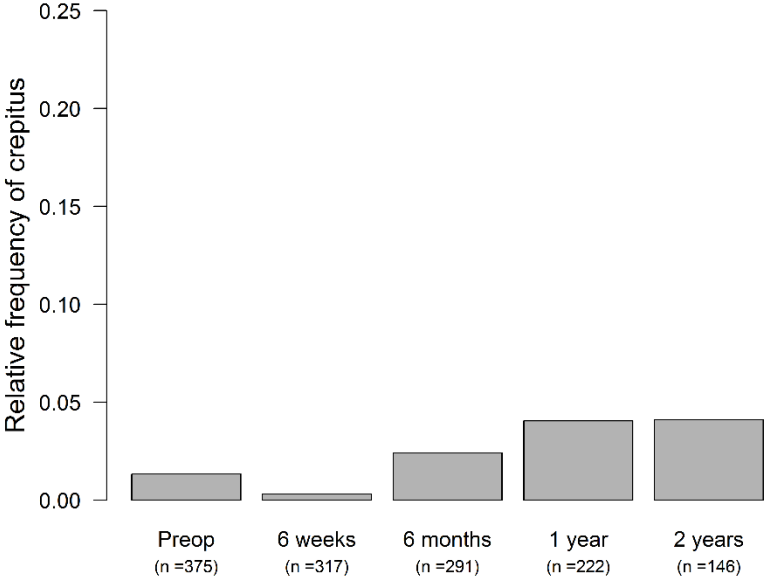


Figure 26. Relative frequency of crepitus before and after orthognathic surgery

3.4 Risk factors for patients without TMD symptoms at T0

As an additional evaluation, we used all patients without symptoms preoperative and examined possible changes of TMD functions and symptoms during the follow-up period.

37% of the patients without any signs or symptoms before OGS reported at least one joint symptom after two years.

105 patients without presurgical TMD at T0 were also examined at T2; 66 (62.9%) reported no clinical symptoms and 39 (37.1%) developed at least one TMD symptom after six months. Of the 41 patients without any TMD symptoms before OGS, who were also examined after two years, 23 (56.1%) reported no signs and 18 (43.9%) developed at least one clinical TMD symptom after two years.

To identify risk factors independently associated with the occurrence of at least one TMD sign and symptom after OGS, a binomial logistic regression model was created, including all patients without any signs or symptom of TMD before OGS (Table 6, Table 7, Table 8).

The model returned three variables independently associated with the occurrence of at least one TMD symptom at T1. Those were female versus male patients (odds ratio [OR] = 2.5; confidence interval [CI] = 1.2–5.6; $P < .013$), class II versus class III (OR = 5.0; CI = 1.9–17.2; $P = .001$), and CCR of the MMC (OR = 5.5; CI = 1.9–16.6; $P = .001$) (Table 7). At the further timepoints (T2-T4) for all variables (age, skeletal class, type of rotation of the MMC, and the amount of movement of the mandibular segment) no association was established. Table 8 displays that gender, skeletal class, and CCR of the MMC were significantly associated with the occurrence of pain at T1 and T2 for patients without any signs or symptoms before surgery ($P = .010$, $P = .013$, and $P = .003$, respectively). Table 6 shows that there was also no predictive confounder for postoperative severe dysfunctions (Di 2/3) in relation to preoperative symptom-free patients.

Regarding gender, the frequency of preoperative symptom-free patients with at least one or without clinical symptoms of TMD at T1 and T4 are displayed in Figure 27 and Figure 28.

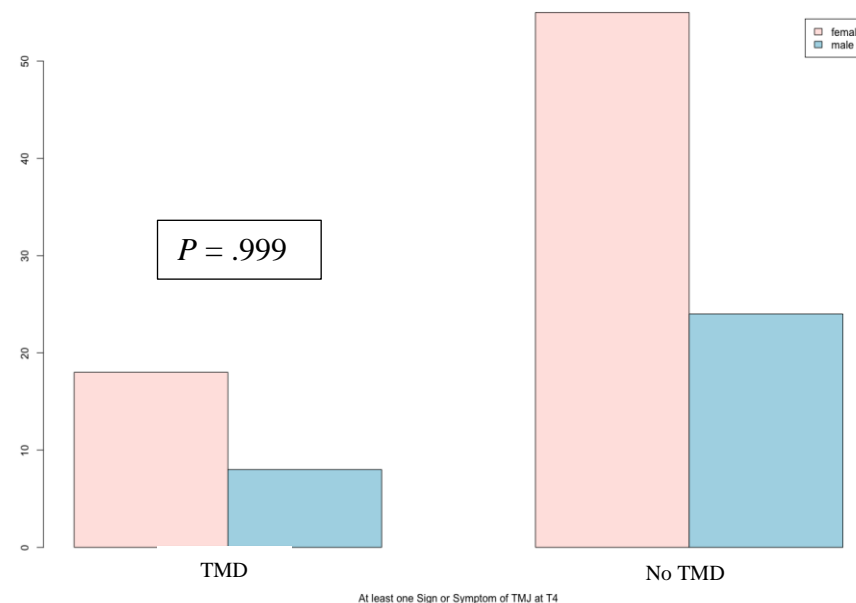
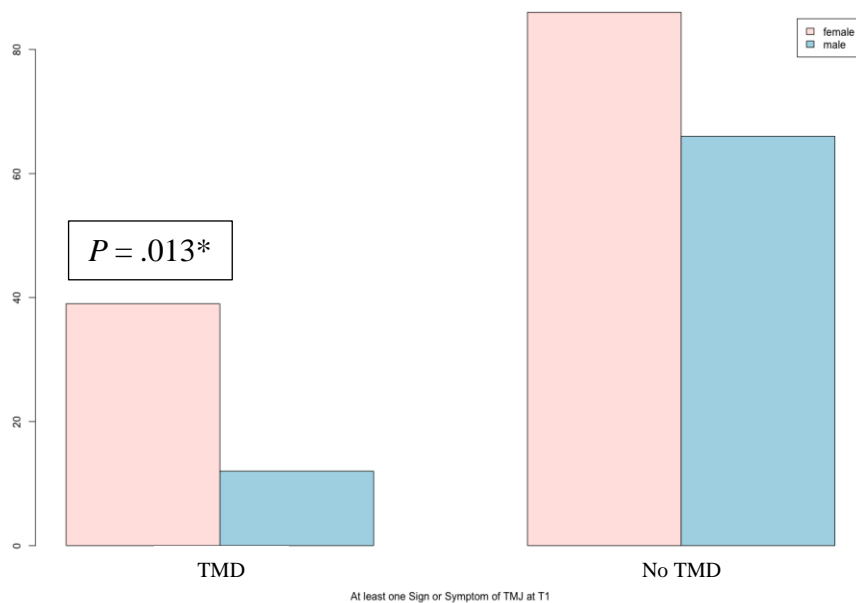


Figure 27. Barplot: Frequency of preoperative symptom-free patients (female/male) with at least one or without clinical symptoms at T1

Figure 28. Barplot: Frequency of preoperative symptom-free patients (female/male) with at least one or without clinical symptoms at T4

There was a statistical significance ($P = .001^*$) at T1 for female patients without symptoms preoperative, who showed at least one clinical symptom of TMD at T1 ($n = 39$).

Regarding the skeletal class, the frequency of preoperative symptom-free patients with at least one or without clinical symptoms of TMD at T1 and T4 are displayed in Figure 29 and Figure 30.

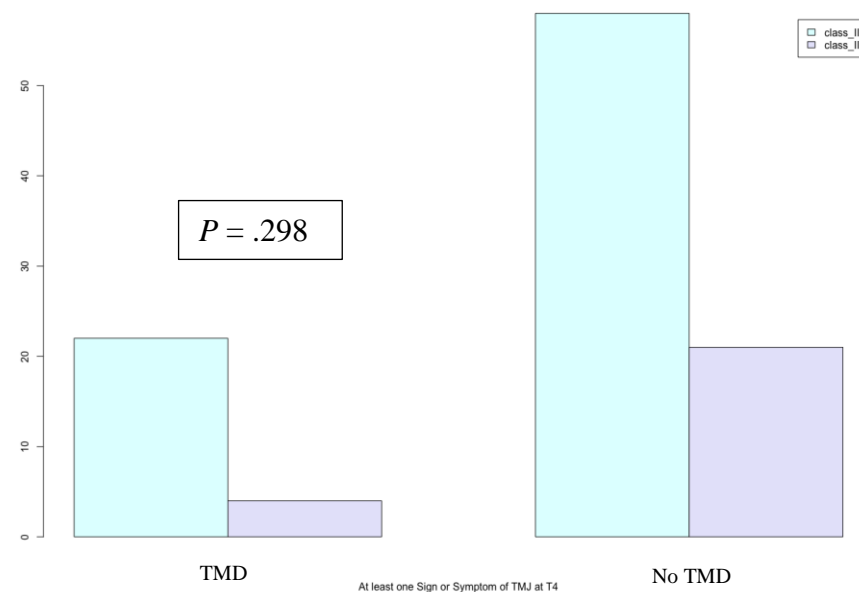
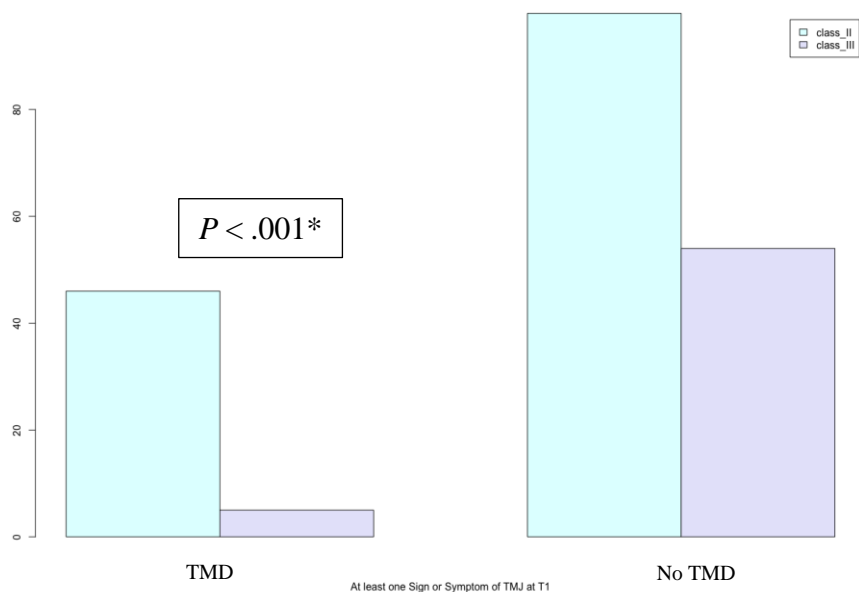


Figure 29. Barplot: Frequency of preoperative symptom-free patients (class II/class III) with at least one or without clinical symptoms at T1

Figure 30. Barplot: Frequency of preoperative symptom-free patients (class II/class III) with at least one or without clinical symptoms at T4

There was a statistical significance ($P < .001^*$) at T1 for class II patients without symptoms preoperative, who showed at least one clinical symptom of TMD at T1 ($n = 46$).

Regarding the movement of the MMC complex (advancement or setback), the frequency of preoperative symptom-free patients with at least one or without clinical symptoms of TMD at T1 and T4 are displayed in Figure 31 and Figure 32.

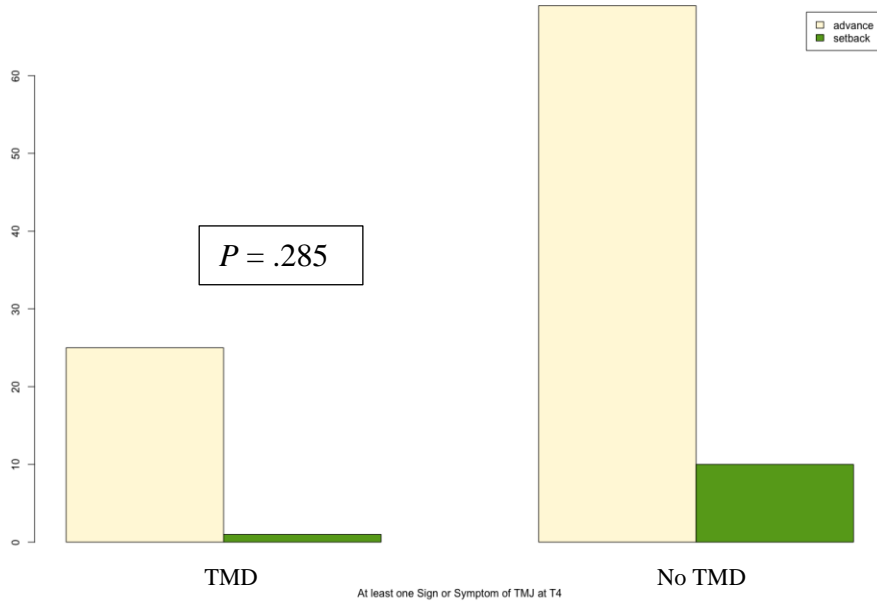
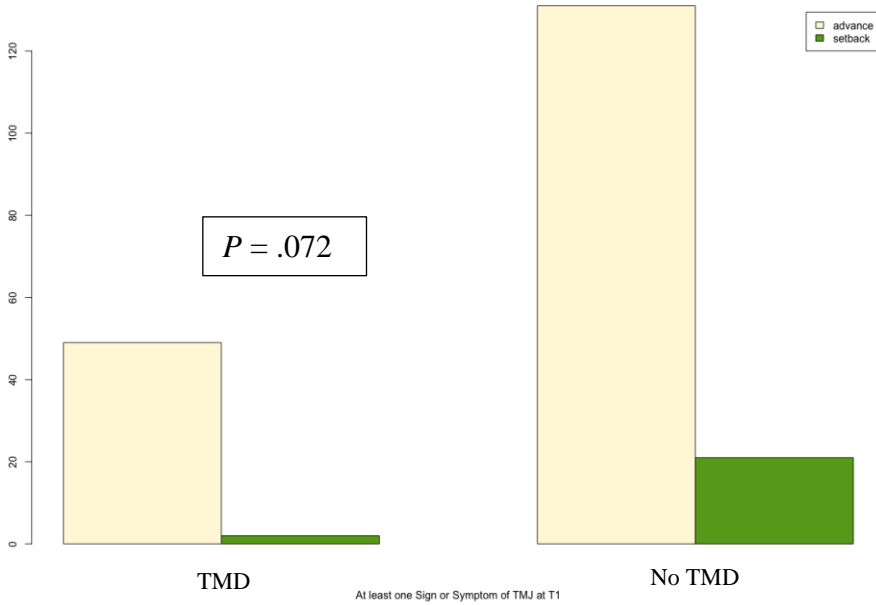


Figure 31. Barplot: Frequency of preoperative symptom-free patients (advancement/setback) with at least one or without clinical symptoms at T1

Figure 32. Frequency of preoperative symptom-free patients (advancement/setback) with at least one or without clinical symptoms at T4

Regarding the amount of advancement, the frequency of preoperative symptom-free patients with at least one or without clinical symptoms of TMD at T1 and T4 are displayed in Figure 33 and Figure 34.

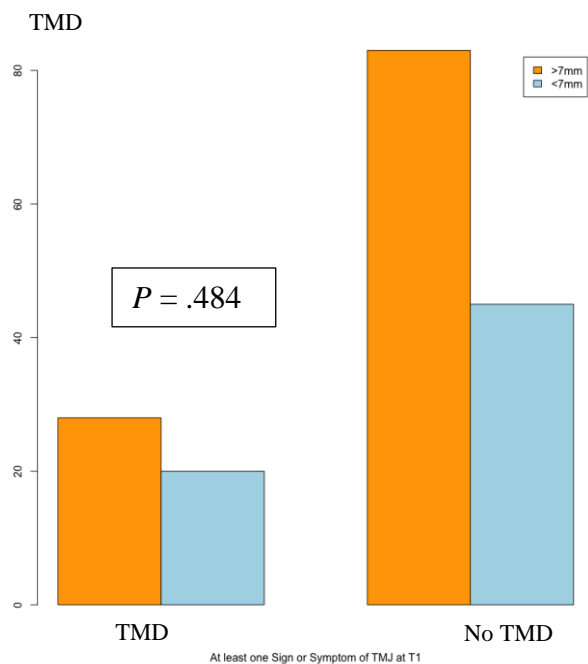


Figure 33. Barplot: Frequency of preoperative symptom-free patients (advancement $\geq 7\text{mm}$ / $< 7\text{mm}$) with at least one or without clinical symptoms at T1

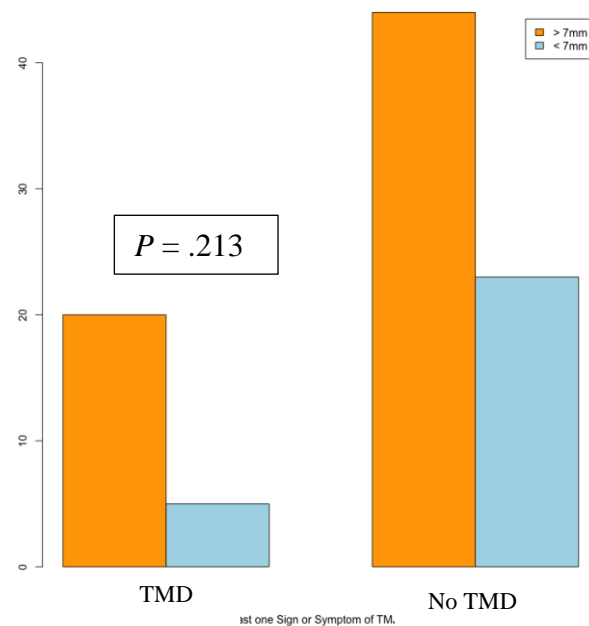


Figure 34. Barplot: Frequency of preoperative symptom-free patients (advancement $\geq 7\text{mm}$ / $< 7\text{mm}$) with at least one or without clinical symptoms at T4

Regarding the type of rotation (CCR), the frequency of preoperative symptom-free patients with at least one or without clinical symptoms of TMD at T1 and T4 are displayed in Figure 35 and Figure 36.

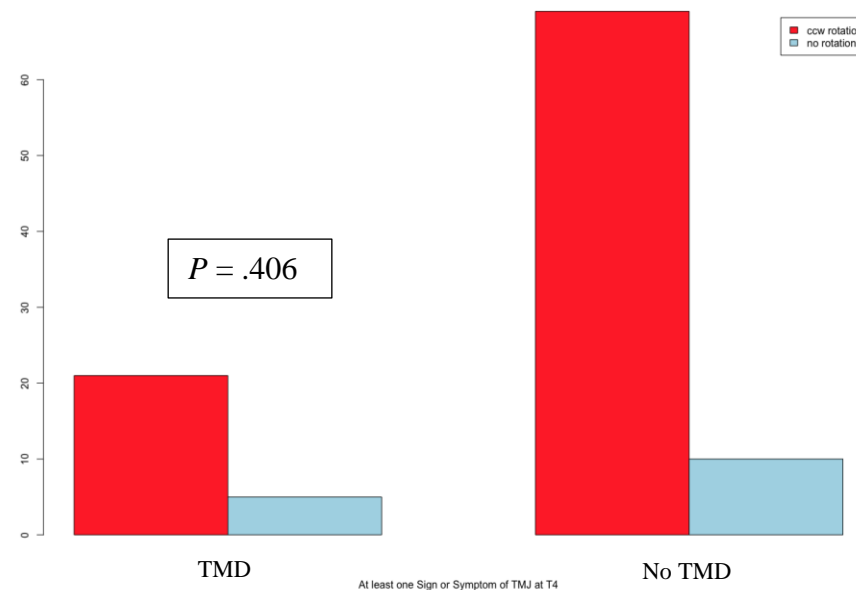
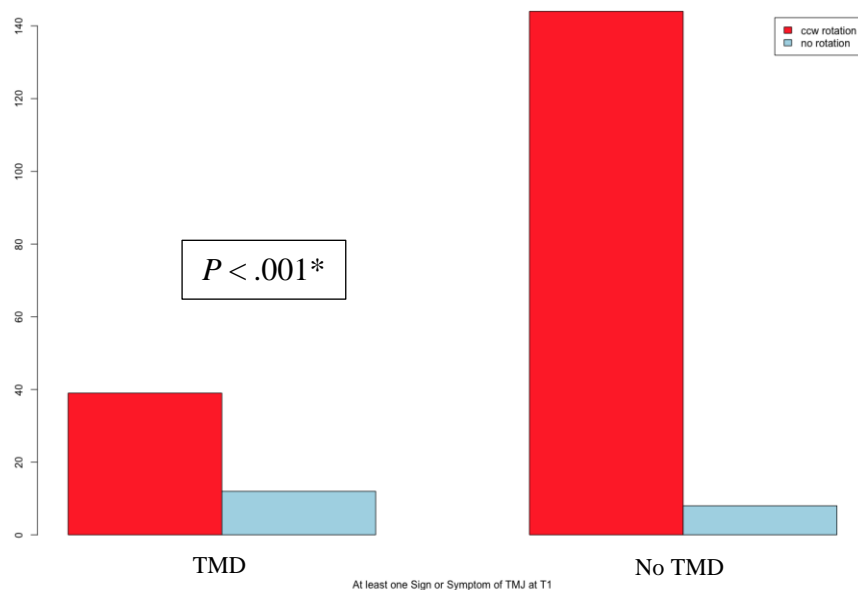


Figure 35. Barplot: Frequency of preoperative symptom-free patients (CCR/ No rotation) with at least one or without clinical symptoms at T1

Figure 36. Barplot: Frequency of preoperative symptom-free patients (CCR/ No rotation) with at least one or without clinical symptoms at T4

There was a statistical significance ($P < .001^*$) at T1 for patients (CCR rotation) without symptoms preoperative, who showed at least one clinical symptom of TMD at T1 (n = 39).

Regarding the type of rotation (CR), the frequency of preoperative symptom-free patients with at least one or without clinical symptoms of TMD at T1 and T4 are displayed in Figure 37 and Figure 38.

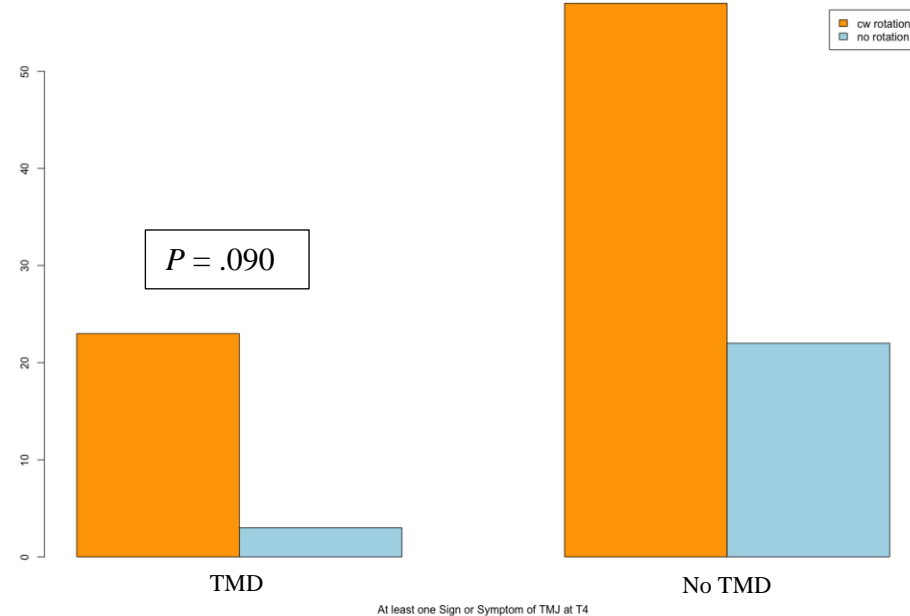
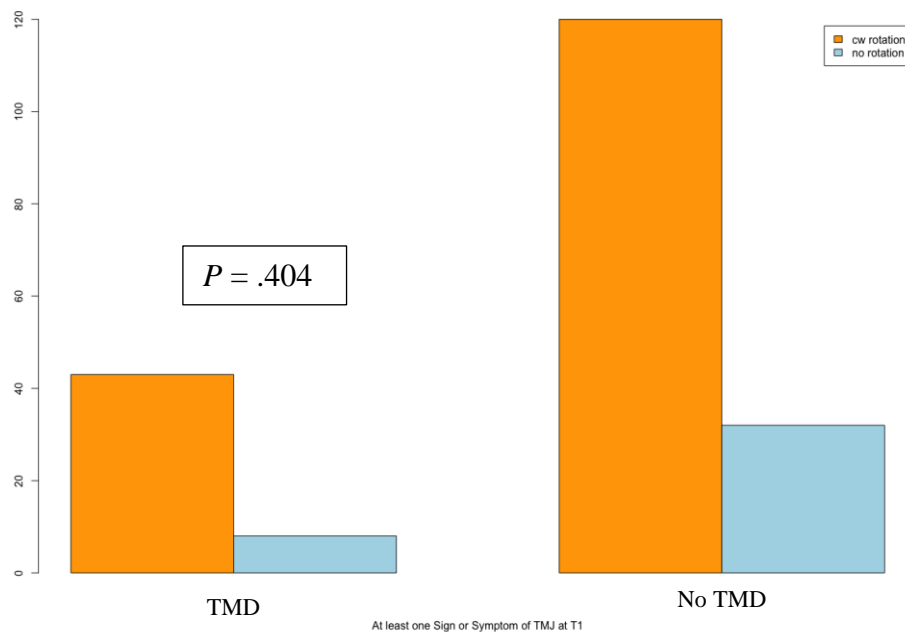


Figure 37. Barplot: Frequency of preoperative symptom-free patients (CR/ No rotation) with at least one or without clinical symptoms at T1

Figure 38. Barplot: Frequency of preoperative symptom-free patients (CR/ No rotation) with at least one or without clinical symptoms at T4

The odds ratios for all patients without any signs or symptoms before surgery were calculated and returned for the variables (gender, skeletal class, movement, CCR rotation and CR rotation, of the MMC) for the timepoints T1-T4 (Table 6).

Table 6. Odds ratios for postoperative severe dysfunction (Di 2/3) at T1 to T4

Variable	T1	T2	T3	T4
Female vs. Male	OR=0.0, 95%CI=0.0-8.54 <i>P</i> = .524	OR=0.0, 95%CI=0.0-1.35 <i>P</i> = .084	OR=0.0, 95%CI=0.0-61.92 <i>P</i> = .999	OR=0.0, 95%CI=0.0-88.85 <i>P</i> = .999
class II vs. III	OR=1.2, 95%CI=0.10-67.15 <i>P</i> = .999	OR=2.4, 95%CI=0.26-117.18 <i>P</i> = .666	OR=1.3, 95%CI=0.02-25.18 <i>P</i> = .999	OR=0.7, 95%CI=0.03-39.81 <i>P</i> = .999
Advancement vs. Setback	OR=0.4, 95%CI=0.03-21.98 <i>P</i> = .405	OR=0.8, 95%CI=0.02-6.82 <i>P</i> = .999	OR=0.3, 95%CI=0.01-16.46 <i>P</i> = .322	OR=0.3, 95%CI=0.13-16.31 <i>P</i> = .319
BSSO (≥ 7 mm vs. < 7 mm)	OR=5.2, 95%CI=0.41-277.57 <i>P</i> = .146	OR=3.6, 95%CI=0.50-40.96 <i>P</i> = .193	OR=0.0, 95%CI=0.0-62.50 <i>P</i> = .428	OR=4.6, 95%CI=0.23-277.51 <i>P</i> = .229
CCR vs. CR	OR=0.0, 95%CI=0.0-49.56 <i>P</i> = .999	OR=1.5, 95%CI=0.03-14.48 <i>P</i> = .535	OR=0.0, 95%CI=0.0-273.99 <i>P</i> = .999	OR=0.0, 95%CI=0.0-233.15 <i>P</i> = .999

Abbreviations: CCR = counterclockwise rotation; CR = clockwise rotation; T1 = six weeks; T2 = six months; T3 = one year; T4 = two years postoperative

The odds ratios for all patients without any signs or symptoms before surgery were calculated and returned for the variables (gender, skeletal class, movement, CCR rotation, and CR rotation of the MMC) for the timepoints T1-T4 (Table 7).

Table 7. Odds ratios for at least one postoperative clinical sign and symptom of TMD (T1 to T4)

At least one clinical sign and symptom (pain, clicking and crepitus) of TMJ				
Variable	T1	T2	T3	T4
Female vs. Male	OR=2.5, 95%CI=1.16-5.64 <i>P</i> = .013*	OR=1.6, 95%CI=0.75-3.39 <i>P</i> = .233	OR=1.5, 95%CI=0.66-3.30 <i>P</i> = .362	OR=1.0, 95%CI=0.35-2.98 <i>P</i> = .999
Skeletal class II vs. III	OR=5.0, 95%CI=1.85-17.21 <i>P</i> < .001**	OR=2.2, 95%CI=0.98-5.46 <i>P</i> = .050	OR=1.6, 95%CI=0.65-3.40 <i>P</i> = .323	OR=2.0, 95%CI=0.57-8.83 <i>P</i> = .298
Advancement vs. Setback	OR=3.9, 95%CI=0.90-35.63 <i>P</i> = .072	OR=2.1, 95%CI=0.67-9.04 <i>P</i> = .232	OR=1.3, 95%CI=0.37-4.38 <i>P</i> = .582	OR=3.6, 95%CI=0.47-163.32 <i>P</i> = .285
BSSO (≥ 7 mm vs. < 7 mm)	OR=0.8, 95%CI=0.37-1.59 <i>P</i> = .484	OR=1.4, 95%CI=0.61-2.93 <i>P</i> = .459	OR=1.9, 95%CI=0.80-4.32 <i>P</i> = .118	OR=2.1, 95%CI=0.64-8.01 <i>P</i> = .213
CCR vs. CR rotation	OR=5.5, 95%CI=1.91-16.63 <i>P</i> < .001**	OR=2.7, 95%CI=0.95-7.30 <i>P</i> = .041*	OR=1.4, 95%CI=0.44-4.41 <i>P</i> = .589	OR=1.6, 95%CI=0.39-5.99 <i>P</i> = .518

Abbreviations: CCR = counterclockwise rotation; CR = clockwise rotation; T1 = six weeks; T2 = six months; T3 = one year; T4 = two years postoperative,

** statistically significant $P < .001$; * statistically significant $P < .05$

The odds ratios for all patients without any signs or symptoms before surgery were calculated and returned for the variables (gender, skeletal class, movement, CCR rotation, and CR rotation of the MMC) for the timepoints T1 to T4 (Table 8).

Table 8. Odds ratios for postoperative clinical signs and symptoms (pain and clicking) at T1 to T4

		At least one clinical sign and symptom (pain, clicking and crepitus) of TMJ			
Variable		T1	T2	T3	T4
Female vs. Male	Pain	OR=5.9, 95%CI=1.35-54.50 <i>P</i> = .011*	OR=9.6, 95%CI=1.40-415.26 <i>P</i> = .010*	OR=4.2, 95%CI=0.88-39.90 <i>P</i> = .080	OR=1.1, 95%CI=0.17-12.19 <i>P</i> = .999
	Clicking	OR=1.2, 95%CI=0.37-3.98 <i>P</i> = .999	OR=1.15, 95%CI=0.48-2.85 <i>P</i> = .841	OR=1.5, 95%CI=0.61-3.91 <i>P</i> = .412	OR=0.6, 95%CI=0.20-2.17 <i>P</i> = .409
Class II vs. III	Pain	OR=8.2, 95%CI=1.24-350.55 <i>P</i> = .015*	OR=8.7, 95%CI=1.28-370.73 <i>P</i> = .013**	OR=2.4, 95%CI=0.51-23.47 <i>P</i> = .351	OR=1.9, 95%CI=0.22-93.15 <i>P</i> = .999
	Clicking	OR=1.4, 95%CI=0.40-5.99 <i>P</i> = .782	OR=1.8, 95%CI=0.69-5.21 <i>P</i> = .292	OR=1.5, 95%CI=0.55-4.43 <i>P</i> = .505	OR=1.1, 95%CI=0.30-5.15 <i>P</i> = .999
Advancement vs. Setback	Pain	OR=2.95, 95%CI=0.43-127.80 <i>P</i> = .480	OR=2.7, 95%CI=0.39-119.37 <i>P</i> = .475	OR=1.7, 95%CI=0.22-76.12 <i>P</i> = .999	OR=1.0, 95%CI=0.11-46.56 <i>P</i> = .999
	Clicking	OR=0.9, 95%CI=0.20-9.20 <i>P</i> = .999	OR=1.6, 95%CI=0.44-9.02 <i>P</i> = .578	OR=0.8, 95%CI=0.23-3.82 <i>P</i> = .754	OR=2.2 95%CI=0.28-101.33 <i>P</i> = .685
BSSO (≥7mm vs. <7mm)	Pain	OR=2.1, 95%CI=0.70-6.01 <i>P</i> = .141	OR=0.8, 95%CI=0.22-2.90 <i>P</i> = .771	OR=2.1, 95%CI=0.54-7.77 <i>P</i> = .243	OR=0.3, 95%CI=0.01-3.21 <i>P</i> = .671
	Clicking	OR=0.8, 95%CI=0.22-2.86 <i>P</i> = .762	OR=1.7, 95%CI=0.70-4.45 <i>P</i> = .193	OR=1.4, 95%CI=0.52-3.55 <i>P</i> = .507	OR=0.3, 95%CI=0.03-1.23 <i>P</i> = .082
CCR vs. CR	Pain	OR=7.5, 95%CI=2.14-25.43 <i>P</i> = .001**	OR=6.4, 95%CI=1.64-23.19 <i>P</i> = .003**	OR=2.1, 95%CI=0.34-9.27 <i>P</i> = .384	OR=1.0, 95%CI=0.02-9.28 <i>P</i> = .999
	Clicking	OR=1.2, 95%CI=0.13-6.07 <i>P</i> = .677	OR=3.5, 95%CI=1.13-10.11 <i>P</i> = .014*	OR=1.4, 95%CI=0.36-4.73 <i>P</i> = .548	OR=1.2, 95%CI=0.20-5.46 <i>P</i> = .719

Abbreviations: CCR = counterclockwise rotation; CR = clockwise rotation; T1= six weeks; T2 = six months; T3 = one year; T4 = two years postoperative;

** statistically significant $P < .001$; * statistically significant $P < .05$

3.5 Dysfunction index by Helkimo

The number of patients with the respective Di (Di0/Di1/Di2/Di3) before and after OGS is displayed in Table 9.

Table 9. Dysfunction index from T0 – T4

	T0	T1	T2	T3	T4
	(n = 375)	(n = 317)	(n = 291)	(n = 222)	(n = 146)
Di0	243	214	203	147	103
Di1	110	98	75	71	40
Di2	20	5	11	4	2
Di3	2	0	2	0	1

Abbreviations: T0 = preoperative; T1 = six weeks; T2 = six months; T3 = one year; T4 = two years postoperative

The relative frequency of Di before and after OGS is displayed in Figure 39.

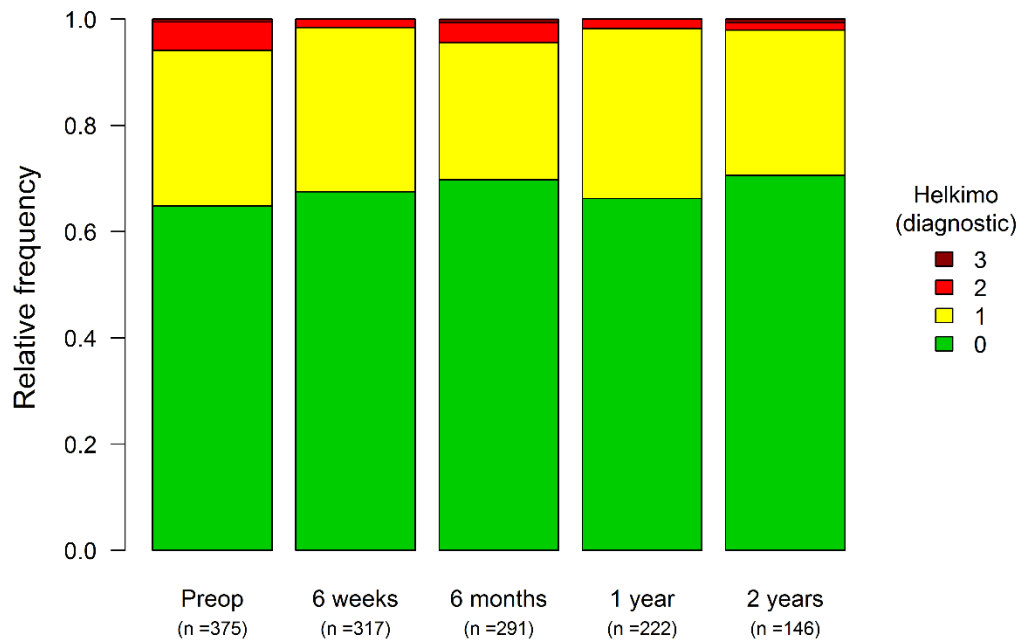


Figure 39. The relative frequency of Di before and after orthognathic surgery

The Di (Di0-Di3) was 243 (64.8%), 110 (29.3%), 20 (5.3%), 2 (0.5%) at T0 (n = 375), 203 (69.8%), 75 (25.8%), 11 (3.8%), 2 (0.7%) at T2 (n = 291), and 103 (70.5%), 40 (27.4%), 2 (1.4%), and 1 (0.7%) at T4 (n = 146), respectively.

Only the differences of Di (Di0/1 and Di2/3) before OGS and after OGS at timepoints T1, and T2 were statistically significant ($P = .028$; $P = .011$, respectively). Severe signs of dysfunction (Di 2/3) were seen in 5.9% of the study participants prior, and in 2.1% of the 146 patients two years after OGS (Table 9).

The preoperative and postoperative Di categorized in Di 0/1 and Di 2/3 for T2 and T4 are displayed in Table 10 and Table 11.

Table 10. Dysfunction index by Helkimo before surgery (T0) and one year postoperative (T2)

T0		T2				
Preoperative (n = 375)		Di0	Di1	Di2	Di3	missing
Di0	243	136	43	5	1	58
Di1	110	59	22	2	1	26
Di2	20	7	9	4	0	0
Di3	2	1	1	0	0	0
		203	75	11	2	84

Table 11. Dysfunction index by Helkimo before surgery (T0) and two years postoperative (T4)

T0		T4				
Preoperative (n = 375)		Di0	Di1	Di2	Di3	missing
Di0	243	79	25	1	0	138
Di1	110	21	11	0	1	77
Di2	20	3	4	0	0	13
Di3	2	0	0	1	0	1
		103	40	2	1	229

4 Discussion

For many years occlusal parameters and skeletal class were the dominating factors that have been considered when making decisions for OGS. This monodirectional worldview is no longer prevalent and the understanding that there is a complex system consisting of a direct context between dentofacial deformity, head posture, cervical spine, pharyngeal airway, temporomandibular, and myofunctional parameters has increased (Abrahamsson et al., 2015; Egermark et al., 2000; Laskin, 1995; T. Magnusson et al., 1990; Mehra et al., 2001; te Veldhuis et al., 2017). Therefore, the interest in the question of whether OGS has a positive or negative impact on this complex context has increasingly gained in importance. So far, the current publications, including meta-analyses, are not very meaningful, as they are based on relatively small, inhomogeneous samples, or on retrospective questionnaires of OGS patients (Arya et al., 2017; Dujoncquoy et al., 2010; Onizawa et al., 1995; Panula et al., 2005; te Veldhuis et al., 2017; Zanetta-Barbosa et al., 2013). Therefore, this study is one of the first to analyze a large number of similar cases, who were all treated by the same experienced surgeon in the exact same surgical setting. The potential impact on TMJ function and clinical signs and symptoms of TMD before and after OGS was supposed to analyze for the differentiation of significant confounder and non-influencing cofactors.

The key questions that have been raised were: Is there a difference in TMD symptoms before and after OGS, and are there risk factors associated with the prevalence of TMD after OGS?

The main findings of the study were: First, the Di showed no significant changes two years after OGS when compared with pre-surgery. In contrast, the prevalence of at least one clinical sign or symptom (either pain, clicking, crepitus, or reduced mouth opening) post-surgery was significantly reduced after six weeks and two years. Second, female gender, skeletal class II and CCR of the MMC were only associated with the occurrence of TMD after six weeks. The

results showed no long-term association for these or any other variables. Third, TMJ function was significantly reduced after six weeks and returned to normal after two years. This is consistent with the findings in several other studies, which examined the changes in MMO after OGS (Ueki et al., 2008; Yazdani et al., 2010). In a review article from Al-Belasy, Tozoglu and Dolwick, 2013 five from seven studies did not support the notion that OGS affects mandibular mobility permanently. Interestingly, in our study lateral excursion was significantly reduced at all timepoints compared to the preoperative values during the follow-up.

Female patients started with a higher incidence of TMD preoperatively, reported significantly more TMD symptoms (39.7%), and had more severe dysfunction (Di 2/3) (7.7%) before OGS. Two years post-surgery signs and symptoms were reduced to 32.4% and severe dysfunction to 2.9% respectively, and the difference in gender was no longer statistically significant. Regarding the clinical joint symptoms only the difference of clicking between pre- and post-treatment after six weeks was statistically significant. 67% of the patients with pain before OGS showed improvement after two years. 37% of the patients without any signs or symptoms before OGS reported at least one joint symptom at T4. Clicking (20%) was the most common sign of TMD at T4, whereas pain was reported in 10% of the patients at the same timepoint.

The prevalence of TMD symptoms in our study was 34.9%, which means that more than one third of the patients showed signs and various severities of internal derangement of the TMJ prior to OGS. This prevalence in our study sample was low compared to the findings of several studies, ranging from 48% to 97% (Onizawa et al., 1995; Panula et al., 2005; Westermarck et al., 2001; White & Dolwick, 1992). In contrast, some studies reported that patients presenting for surgical correction of a skeletal deformity had a lower prevalence of TMD, ranging from 14% to 26% (Declercq et al., 1993; Laskin, 1995). This wide disparity might be explained by differences in pretreatment in adolescence, ethnicity, age, evaluation methods used, and study design. Even in studies on non-patient population, the prevalence of TMD symptoms ranges

from 12% to 68% (Bevilaqua-Grossi et al., 2006; Pedroni et al., 2011). Regarding the symptoms, clicking (24.8%) was the most common finding in our cohort, whereas pain was observed in 13.6%, and crepitus in 1.3% of the patients only. These findings are similar to a retrospective study, where clicking (27.6%), pain (8.8%), and crepitus (4%) were found before surgery (Kretschmer et al., 2019). These results confirm prior research, which showed that noise in the joint area was the most frequent anamnestic symptom of the TMJ before OGS (Carlsson et al., 2002; Dervis & Tuncer, 2002; Mazengo & Kirveskari, 1991). Several authors concluded that noise in the area of the TMJ was a significant predictor of TMD (Al-Moraissi et al., 2017; Carlsson et al., 2002; T. Magnusson et al., 2000; Mazengo & Kirveskari, 1991). But Magnusson et al. (2000) stated that it was not an indication for medical treatment, and there is still uncertainty whether sound, with or without pain, should be considered a sign or a symptom of TMD. Various authors stated that noises may appear with or without the presence of pain or evident diseases and distress in the muscles or the TMJ region (Al-Moraissi et al., 2017; Dodić et al., 2006; Nourallah & Johansson, 1995; Okeson, 2008).

In our study the prevalence of at least one clinical sign was seen in 44 patients (30.1%) at two years post-surgery and indicated a significant improvement to the preoperative examination (34.9%). Of these patients, 28 (63.6%) had newly developed symptoms and 16 patients (36.4%) already had symptoms before OGS. This is similar to the findings of a study conducted by Dervis and Tuncer, 2002 who reported that 38% of the patients undergoing OGS had at least one sign and symptom after the two year follow-up.

In this study, the results of the sample showed less frequent and fewer signs and symptoms of TMD after OGS than before. It was concluded by the authors that the functional status of the TMJ can be improved by OGS. In a study comparing mandibular advancement with setback, Pahkala and Kellokoski, 2007 found that TMD symptoms were significantly improved after advancement with BSSO, but in 12% of the patients symptoms were even worse post-surgery.

In a Finnish sample, after OGS, a decrease in TMD signs and symptoms from 73% pre-operative to 60% at four years post-surgery were reported (Panula et al., 2005). A positive effect on the TMJ was also found in a study when investigating 75 patients before and after OGS: 49% had pre-surgical TMD signs and symptoms, 89% had fewer TMD symptoms post-surgery (White & Dolwick, 1992). However, in 11% of the patients of this study TMD had remained or worsened post-surgery. In contrast, some studies have shown negative effects of OGS on TMD: Based on 25 patients at the two year follow-up, the authors found that OGS may increase postsurgical TMD if the patient had presurgical TMD (Wolford et al., 2003).

In a retrospective study on 57 patients, where a questionnaire was used to evaluate TMJ disorder changes before and after OGS, 56% of the patients presented TMJ symptoms before surgery. 33% had clicking during opening and closing the mouth, and 28% experienced pain. A significant increase in TMJ sounds post-surgery, but no significant change in TMJ pain, was observed. (Dujoncquoy et al., 2010)

In addition to being an indicator of degenerative changes in the TMJ, crepitation is presumed to be present in TMJs with an altered disc. Although condyles have been found to displace only minimally with surgery, an alteration in disc-condyle integrity cannot usually be avoided in OGS. (Pahkala & Heino, 2004)

Furthermore, Harper *et al.*, 1987 have shown in their electromyography investigations that surgical advancement of the mandible in Class II cases normalizes the preoperative hyperactivity of the lateral pterygoid muscle. This may partly explain the decrease in postoperative joint noise, e.g. clicking.

In a systematic review, three prospective studies were evaluated and the aim of this review was to answer the question whether OGS affects the prevalence of signs and symptoms of TMD in patients with malocclusion (Abrahamsson et al., 2007). When comparing signs and symptoms of TMD before treatment, neither study found any significant differences between patients and

control group, nor type of malocclusion. Two of the studies concluded that after treatment both signs and symptoms related to TMD could be improved significantly (Dervis & Tuncer, 2002; Panula et al., 2005). However, in the third study the authors declared that TMD symptoms did not always show improvement after surgical correction, and for some patients symptoms of TMD had become worse (Onizawa et al., 1995). When considering specific signs of TMD, Panula *et al.*, 2005 and Dervis *et al.*, 2013 concluded a statistically significant decrease in muscle palpation tenderness after surgery, whereas in the study by Onizawa, Schmelzeisen and Vogt, 1995 no such change was found. Furthermore, Panula *et al.*, 2005 also reported a significant decrease in joint palpation tenderness. However, no conclusion could be drawn in this systematic review due to the lack of studies located and their unambiguous results (Abrahamsson et al., 2007). To objectivize the extent of TMD, to analyze for differentiation of significance confounder and non-influencing cofactors and to compare the data with the literature in this current study, the Di was used. (Helkimo, 1974a) Generally, the clinical Di is considered useful and is recommended for epidemiological research (Ajanovic & Bejtovic, 2009; Pahkala & Kellokoski, 2007; Van Der Weele & Dibbets, 1987). In our study, a significant difference between the preoperative and postoperative Di was only found after six weeks and six months. At six months, nine patients developed new severe dysfunctions, whereas four remained with severe symptoms of TMD. The results were similar to Pahkala and Heino, 2004, where the severity of the dysfunction was reduced after surgery in 72 patients. In 37 patients the signs disappeared or became less severe with the treatment, while in ten subjects, new signs appeared, or previous signs became worse. Preoperatively, eight patients (11%) had severe signs of dysfunction, but about two years postoperatively nobody suffered from severe dysfunction (Di3) anymore. Moreover, nine out of ten patients in this study were either free of TMD or had only mild symptoms (Pahkala & Heino, 2004).

In the study by Dervis *et al.*, 2013, the severity of TMD was reduced when compared to the preoperative evaluation of TMD. Two years postoperative a statistically distinguishing reduction of the Di was noted for the whole group, mainly because of the substantially reduced muscle tenderness (Dervis & Tuncer, 2002). In a controlled prospective study on 60 patients, the Di showed significant improvement between the preoperative and the final examination after four years (Panula *et al.*, 2005). Compared to our study the prevalence of signs and symptoms of TMD (73.3%) was much higher. An explanation for this difference may either be the criteria for the recorded symptoms, or in the patient's selection itself. Another explanation may be the study design using a questionnaire and a clinical examination for data acquisition. Although the difference of Di was not significant in our study, severe dysfunction of the TMJ was seen in 5.9% of the patients before surgery, and in 2.1% of the patients two years after OGS. Interestingly, the prevalence of at least one clinical sign and symptom was significantly reduced two years after surgery. The risk for postoperative TMD symptoms (at least one sign or symptom of TMD) for patients without symptoms preoperative after six weeks was remarkably associated with female patients, skeletal class II and CCR of the MMC. At this timepoint the odds of developing TMD symptoms in females is estimated to be 2.5 times the odds of males. Interestingly, none of the study variables (age, skeletal class, type of rotation of the MMC, and the amount of movement of the mandibular segment) were associated with clinical signs and symptoms of TMD after one and two years, respectively. These findings support the idea that patients with these co-factors who require OGS should receive preoperative treatment of the TMJ and careful follow-ups including intensive physiotherapy addressing TMD. However, the negative effect of the variables was not seen after one year, which supports the idea of a primarily myogenic process of the TMJ after OGS.

4.1 Sex

It has been widely reported in the literature that TMD symptoms are more common in females than in males. The pattern of TMD signs is also suggested to be more consistent in women than in men (Wänman, 1996). Regarding preoperative and postoperative signs of TMD in orthognathic patients, an increase, especially in clicking in some of the females, but not in males, was found. In a study using multiple regression analyses neither gender nor age of the patients was related to the improvement of the Di (Westermarck et al., 2001).

Although females tended to have numerically more signs of TMD and headaches than males, both preoperatively and postoperatively, the gender differences were statistically significant only in postoperative muscle pain (Pahkala & Heino, 2004). Westermarck, Shayeghi and Thor, 2001 observed no significant difference between gender and improvement of TMD after OGS. However, on the one hand, several authors have observed that females had more TMD than male patients before OGS, but on the other hand benefited more from OGS than males, confirming the study data (Aghabeigi et al., 2001; De Clercq et al., 1995; Westermarck et al., 2001; White & Dolwick, 1992). These results are similar to our study, where the gender difference was only seen before surgery and post-surgery at timepoints T1 and T2. That leads to the conclusion that also in the current study female participants, based on the initial situation of higher incidence of TMD symptoms, benefited more from OGS than their male counterpart. The differences between the study results are probably due to the number of participants and the variability in homogeneity.

4.2 Age

Several studies have reported a positive association between signs and symptoms of TMD and age (Aghabeigi et al., 2001; Dervis & Tuncer, 2002; A. Magnusson et al., 2012; T. Magnusson et al., 2000; Westermarck et al., 2001; White & Dolwick, 1992). The study by Dervis and Tuncer,

2002b found slightly more symptoms of TMD with increasing age at the first examination. Panula *et al.*, 2005 and Westermarck, Shayeghi and Thor, 2001 reported that the older group of patients improved more than the younger group in regards to TMD. Our study observed no significant difference between age and TMD signs and symptoms before and after surgery.

4.3 Skeletal class

No association between TMD signs and symptoms, and malocclusions was found in several studies, which is consistent with our data before OGS and the long-term findings (De Clercq *et al.*, 1995; Dervis & Tuncer, 2002; Laskin, 1995; Onizawa *et al.*, 1995; Panula *et al.*, 2005; Rodrigues-Garcia *et al.*, 1998; Wolford *et al.*, 2003).

In contrast, other studies showed that preoperative symptomatic Class I and Class III patients improved more than Class II patients after treatment (Dervis & Tuncer, 2002; White & Dolwick, 1992). White and Dolwick, 1992 reported similar experiences in class III patients compared to class II. However, in both groups TMD symptoms were reduced after OGS. In an analysis by Dervis and Tuncer, 2002, only focusing on class II malocclusion, the authors showed a significant effect of OGS in the surgical subgroup compared to those class II patients with indication for OGS, but who refused surgical intervention for correction of their skeletal deformity (Paunonen *et al.*, 2019).

In a systematic review, where 29 articles were included in a critical appraisal and meta-analysis to determine whether preexisting TMD symptoms in patients with retrognathism, prognathism, or various other dentofacial deformities would improve, worsen, or remain unchanged after OGS (Al-Moraissi *et al.*, 2017). The results of this meta-analysis showed that a preexisting TMD may improve with orthognathic correction in both Class II and III patients. However, not all surgical procedures resulted in an improvement in TMD symptoms. For patients treated by mandibular advancement, an isolated BSSO resulted in significant

improvement in TMD symptoms, but the bimaxillary surgical procedure did not lead to any further notable enhancement. Conversely, an isolated BSSO to achieve setback of the mandible resulted in no improvement in TMD symptoms, but there was an enhancement when it was combined with Le Fort I osteotomy (Al-Moraissi et al., 2017). The weakness of this systematic review is that most of the studies had a retrospective study design or included questionnaires rather than direct patient examinations. In addition, the follow-up period of the comprised studies had a range between four months and four years and makes the comparability difficult. In our study, the effect of skeletal class was only observed at the first timepoint six weeks after OGS. The odds of TMD in patients with class II was estimated to be 5.0 times the odds of patients with skeletal class III. For all further timepoints this association was not evident. This result supports the idea that the TMJ adapts to the new situation and careful treatment is necessary for these patients during the follow-up process.

4.4 Type of rotation of the maxillo-mandibular complex

Proffit, Turvey and Phillips, 1996 found that coexisting TMJ pathology in patients with dentofacial deformity can jeopardize stability after CCR of the MMC, because of increased joint loading, which can cause TMJ-associated symptoms, condylar resorption, malocclusion, and relapse. The authors raised the question whether preexisting TMJ pathology effects the stability of CCR of the MMC, and whether TMJ pathology should be surgically addressed to improve stability. In our study 41 patients received a CCR of the MMC. The Di showed no difference to the patients who received a CR or a straight movement of the MMC after OGS. Regarding the binomial logistic regression model, the odds of patients with CCR having TMD was estimated to be 5.5 times the odds of patients with CR rotation of the maxilla. This difference was only seen for the timepoints T1 and T2. Interestingly, pain was significantly associated to patients with CCR of the MMC at the timepoints T1 and T2. The odds of having

pain after CCR were up to 7.5 times the odds of patients with CR rotation of the maxilla. Joint symptoms declined over the two-year follow-up period and the regression did not depend on the amount of mandibular advancement or CR of the MMC. Thus, increased TMD symptoms after surgery might be clinically significant only in the short term. Suggesting that CCR and long-distance advancement of the mandible are unlikely to be permanent risks for the development of TMD. This can be explained by the remodeling capacity of the TMJ and the adaptive changes in the fibrous and myogenic tissue structures.

In order to reduce the risk of relapse or occurrence of TMD in cases of CCR of the MMC, postsurgical patient management and orthodontic aftercare are essential factors in the follow-up. This includes long-term orthodontic retention and early correction of postsurgical imbalances that may result.

4.5 Amount of mandibular advancement

In a prospective study of 127 Class II patients, the association between the amount of advancement and rotation of the mandible during BSSO and the development of TMD signs and symptoms were investigated. Counterclockwise rotation of the mandible was associated with more muscle tenderness, especially in patients receiving long advancements. The combination of advancement of more than 7 mm with counterclockwise rotation of the mandible was also associated with increased joint symptoms. All symptoms declined over the two year follow-up period (Frey et al., 2008).

Therefore, the authors concluded that CCR of the mandible is related to a slight temporary increase in muscle symptoms after BSSO. Moreover, a combination of CCR of the mandible with long advancement also might increase joint signs and symptoms.

All symptomatology tended to decline over time, suggesting that the amount of advancement

and mandibular rotation should not be considered as risk factors for the development of TMD in patients without preexisting conditions. Similar findings were seen in our study, where the amount of advancement and the type of rotation of the MMC had no long-term influence on the prevalence of postoperative TMD symptoms. Using CCR of the mandible and/or the MMC in the treatment of dentofacial discrepancies, these patients require more aftercare and physiotherapy in the first postoperative phase than other patients. However, postoperative patient management is essential to provide the optimal outcome for all patients.

5 Drawbacks of the study

The diagnostic tool currently used in the literature for the evaluation of TMD is RDC/TMD. However, this diagnostic screening does not classify TMD into categories of severity, an aspect that should not be forgotten in TMD assessment, as TMD is primarily a chronic pain condition with a great variety in expression. There has been criticism of Helkimo's Di that it does not distinguish between joint and muscle dysfunction, and for producing false-positive results (Bevilaqua-Grossi et al., 2006). Despite these problems we used it as the basis of the present index in order to determine the effectiveness of the OGS on TMD. In the original Helkimo index, there are two categories for TMJ dysfunction (impaired function and pain). There is also one category for muscular dysfunction (muscle pain) and two categories which may relate to the masticatory muscles as well as to the TMJs (impaired range of movement and pain on movement of the mandible). Since headache was not mentioned by any subject it was substituted by other pain. Compared to the previous studies that were consulted, the strength and uniqueness of the present study was its large size being treated with the identical orthodontic-surgical principles by the same referring orthodontists and the same surgeons over the years. Pre-operative TMD status was consistently registered and could be utilized in the present study.

The main problem during data evaluation was that not all patients could be examined until T4. A further limitation in our study was that the preoperative examination was performed before orthodontic and orthognathic treatment. Some of the patients started with orthodontic treatment one year before OGS and, therefore, the possible effect during this pretreatment could not be calculated. For the future, we recommend evaluating the patients a few days before OGS for a second preoperative evaluation to consider a possible effect of the orthodontic treatment. To overcome this problem, the database at our department was adapted to this experience and will be implemented in future research.

6 Conclusion

The results of this study show that dysfunction of the TMJ was not permanently altered by OGS. Negative short-term effects on the TMJ after OGS were associated with female gender, skeletal class II, and CCR of the MMC. There is still no final evidence that OGS cures or prevents signs and symptoms of TMD. This study suggests that patients, undergoing OGS should be aware, that effects on the TMJ can vary from improvement to minor worsening. The diversity of diagnostic criteria and classification schemes used in literature make interstudy comparisons difficult. Even though, this study based on a large sample with homogenous confounders and treatment showed very interesting, reliable first-time results, demonstrating potential risk constellations of cofactors and the need for careful treatment pre- and post-surgery. There is still a need for further well-designed RCT with standardized diagnostic criteria and classification schemes for TMD. Consequently, the answer to the question, if the matter between OGS and TMD is still relevant, is definitely ‘yes’.

7 Acknowledgement

First and foremost, I would like to express my sincere gratitude to my mentor Prof. Dr. Dr. Oliver Ploder for not only having the trust in letting me work at this unique study, but also for his great mentorship, patience, and motivation over the past few years.

Next, I offer my sincere thanks to my supervisor Prof. Dr. Dr. Andreas Kolk for giving me the opportunity to do my doctorate, for the immense support throughout my Ph.D. studies, and for broadening my vision of science.

I would also thank the administrative and medical team of the Department of Oral and Maxillofacial Surgery, Academic Teaching Hospital, Feldkirch, Austria for their support and fruitful cooperation during data evaluation, and for providing me masses of paper.

A special thank you goes to my good old friend Mirella and to Charlotte for the proofreading of this thesis.

Many people I hold with the highest regard, are those that, ironically, probably do not believe or know they had much of an impact at all. So, I would like to thank my colleagues and friends, old and new, for their support, advice, and countless hours of laughter and happiness.

My greatest thanks go to my family, without whom I could not have done it. First, to my loved and brilliant daughter Lilly, for being patient, unbelievably funny, and a good sleeper.

I cannot express my gratitude enough especially to my husband Oliver. You are always a source of strength, and you encourage me every day to keep going and get better – as a doctoral student, dentist, or mum.

Finally, I thank you for everything, mum and dad. Without you, your love and your hard work, this journey would obviously not have been possible. Your endless support throughout my whole life is the foundation for everything I have achieved and become. No words can explain how grateful I am to be your daughter.

8 Publications

“The effect of orthognathic surgery on TMJ function and symptoms. What are the risk factors? A longitudinal analysis of 375 patients.”

O. Ploder, G. Sigron, A. Adekunle, L. Burger-Krebes, B. Haller, A. Kolk

Journal of Oral and Maxillofacial Surgery

9 References

- Abrahamsson, C., Ekberg, E., Henrikson, T., & Bondemark, L. (2007). Alterations of Temporomandibular Disorders before and after Orthognathic Surgery A Systematic Review. *Angle Orthodontist*, 77.
- Abrahamsson, C., Henrikson, T., Bondemark, L., & Ekberg, E. C. (2015). Masticatory function in patients with dentofacial deformities before and after orthognathic treatment - A prospective, longitudinal, and controlled study. *European Journal of Orthodontics*, 37(1), 67–72.
- Aghabeigi, B., Hiranaka, D., Keith, D. A., Kelly, J. P., Crean, S. J., Scale, T. M. J., Checklist, S., & Inventory, S. S. A. (2001). Effect of orthognathic surgery on the temporomandibular joint in patients with anterior open bite. *The International Journal of Adult Orthodontics and Orthognathic Surgery*.
- Ajanovic, M., & Bejtovic, B. (2009). Correlation Between Values of the Helkimo Anamnestic and Clinical Dysfunction Index in Patients Suffering from Post Traumatic Stress Disorder. *Materia Socio Medica*, 21(2), 85–91.
- Al-Belasy, F. A., Tozoglu, S., & Dolwick, M. F. (2013). Mandibular hypomobility after orthognathic surgery: A review article. *Journal of Oral and Maxillofacial Surgery*, 71(11), 1967.e1-1967.e11.
- Al-Dlaigan, Y. H., & Asiry, M. A. (2014). Maximum mouth opening in saudi adolescents. *Journal of International Oral Health : JIOH*, 6(6), 45–49.
- Al-Moraissi, E. A., Wolford, L. M., Perez, D., Laskin, D. M., & Ellis, E. (2017). Does Orthognathic Surgery Cause or Cure Temporomandibular Disorders? A Systematic Review and Meta-Analysis. *Journal of Oral and Maxillofacial Surgery*, 75(9), 1835–1847.
- Alomar, X., Medrano, J., Cabratosa, J., Clavero, J. A., Lorente, M., Serra, I., Monill, J. M., & Salvador, A. (2007). Anatomy of the Temporomandibular Joint. *Seminars in Ultrasound*,

- CT and MRI, 28(3), 170–183.
- Arya, V., Kadagad, P., Alvarez, W., Chigurupati, R., & Mehra, P. (2017). Effects of Orthognathic Surgery on TMJ Function and Dysfunction. *Journal of Oral and Maxillofacial Surgery*, 75(10), e339.
- Bevilaqua-Grossi, D., Chaves, T. C., de Oliveira, A. S., & Monteiro-Pedro, V. (2006). Anamnestic index severity and signs and symptoms of TMD. *CRANIO®*, 24(2), 112–118.
- Böckmann, R., Meyns, J., Dik, E., & Kessler, P. (2014). The Modifications of the Sagittal Ramus Split Osteotomy. *Plastic and Reconstructive Surgery Global Open*, 2(12), e271.
- Buchanan, E. P., & Hyman, C. H. (2013). LeFort i osteotomy. *Seminars in Plastic Surgery*, 27(3), 149–154.
- Buttke, T. M., & Proffit, W. R. (1999). Referring adult patients for orthodontic treatment. *Journal of the American Dental Association*, 130(1), 73–79.
- CA Landes, Stübinger, S., Rieger, J., Williger, B., Ha, T., & Sader, R. (2008). Critical evaluation of piezoelectric osteotomy in orthognathic surgery: operative technique, blood loss, time requirement, nerve and vessel integrity. *J Oral Maxillofac Surg.*, 66(4), 657–674.
- Carlsson, G. E., Egermark, I., & Magnusson, T. (2002). Predictors of signs and symptoms of temporomandibular disorders: A 20-year follow-up study from childhood to adulthood. *Acta Odontologica Scandinavica*.
- Cho, S.-H., & Whang, W.-W. (2010). Acupuncture for temporomandibular disorders: a systematic review. *Journal of Orofacial Pain*, 24(2), 152–162.
- Cox, S. C., & Walker, D. M. (1997). Establishing a normal range for mouth opening: its use in screening for oral submucous fibrosis. *The British Journal of Oral & Maxillofacial Surgery*, 35(1), 40–42.
- Crosetti, E., Battiston, B., & Succo, G. (2009). Piezosurgery in head and neck oncological and

- reconstructive surgery: personal experience on 127 cases. *Acta Otorhinolaryngologica Italica: Organo Ufficiale Della Societa Italiana Di Otorinolaringologia e Chirurgia Cervico-Facciale*, 29(1), 1–9.
- Cunha, S. C. da, Nogueira, R. V. B., Duarte, Â. P., Vasconcelos, B. C. do E., & Almeida, R. de A. C. (2007). Análise dos índices de Helkimo e craniomandibular para diagnóstico de desordens temporomandibulares em pacientes com artrite reumatóide. *Revista Brasileira de Otorrinolaringologia*, 73(1), 19–26.
- da Silva, P. A., Lopes, M. T. de F. F., & Freire, F. S. (2015). A prospective study of 138 arthroscopies of the temporomandibular joint. *Brazilian Journal of Otorhinolaryngology*, 81(4), 352–357.
- David, C. M., & Elavarasi, P. (2016). Functional anatomy and biomechanics of temporomandibular joint and the far-reaching effects of its disorders. *Journal of Advanced Clinical & Research Insights* •, 3(3), 101–106.
- De Clercq, C. A. S., Abeloos, J. S. V., Mommaerts, M. Y., & Neyt, L. F. (1995). Temporomandibular joint symptoms in an orthognathic surgery population. *Journal of Cranio-Maxillofacial Surgery*.
- de Leeuw, R. (2008). Orofacial pain. Guidelines for assessment, diagnosis, and management. The American Association of Oro Facial Pain. (4th ed.).
- De Rossi, S. S., Greenberg, M. S., Liu, F., & Steinkeler, A. (2014). Temporomandibular disorders: Evaluation and management. *Medical Clinics of North America*, 98(6), 1353–1384.
- Declercq, C., Neyt, L., Mommaerts, M., Abeloos, J., & De Mot, B. (1993). Temporomandibular joint symptoms in orthognathic surgery: a retrospective study. *Acta Stomatologica Belgica*, 90(2), 77–85.
- Dervis, E., & Tuncer, E. (2002). Long-term evaluations of temporomandibular disorders in

patients undergoing orthognathic surgery compared with. 554–560.

- Dervis, E., Tuncer, E., Rodrigues, A. de F., Kondo, C. A., Procópio, A. S., Luz, J. G., Frey, D. R., Hatch, J. P., Van Sickels, J., Dolce, C., Rugh, J. D., Moore, K. E., Gooris, P. J. J., Stoelinga, P. J. W., Crawford, J. G., Stoelinga, P. J. W., Blijdorp, P. A., Brouns, J. J. A., Wolford, L. M., ... F., F. (2013). Our experience in complications of orthognathic surgery: A retrospective study on 3236 patients. *Journal of Oral and Maxillofacial Surgery*, 22(3), 1–6.
- Dimitroulis, G. (1998). Temporomandibular disorders: a clinical update. *BMJ (Clinical Research Ed.)*, 317(7152), 190–194.
- Dodić, S., Stanisić-Sinobad, D., Vukadinović, M., Milić, A., & Sinobad, V. (2006). The prevalence of craniomandibular disorders in the military population of the Republic of Serbia. *Medicinski Pregled*.
- Dujoncquoy, J. P., Ferri, J., Raoul, G., & Kleinheinz, J. (2010). Temporomandibular joint dysfunction and orthognathic surgery: A retrospective study. *Head and Face Medicine*.
- Egermark, I., Blomqvist, J. E., Cromvik, U., & Isaksson, S. (2000). Temporomandibular dysfunction in patients treated with orthodontics in combination with orthognathic surgery. *European Journal of Orthodontics*, 22(5), 537–544.
- Fallah HM, C. S. (2012). Use of botulinum toxin A for treatment of myofascial pain and dysfunction. *Journal of Oral and Maxillofacial Surgery*, 70(5), 1243–1245.
- Farella, M., Michelotti, A., Bocchino, T., Cimino, R., Laino, A., & Steenks, M. H. (2007). Effects of orthognathic surgery for class III malocclusion on signs and symptoms of temporomandibular disorders and on pressure pain thresholds of the jaw muscles. *International Journal of Oral and Maxillofacial Surgery*, 36(7), 583–587.
- Frey, D. R., Hatch, J. P., Van Sickels, J. E., Dolce, C., & Rugh, J. D. (2008). Effects of surgical mandibular advancement and rotation on signs and symptoms of temporomandibular

- disorder: A 2-year follow-up study. *American Journal of Orthodontics and Dentofacial Orthopedics*, 133(4), 490.e1-490.e8.
- Gauer, R. L., & Semidey, M. J. (2015). Diagnosis and Treatment of Temporomandibular Disorders. *Am Fam Physician*, 91(6), 378–386.
- Geha, H. J., Gleizal, A. M., Nimeskern, N. J., & Beziat, J. L. (2006). Sensitivity of the inferior lip and chin following mandibular bilateral sagittal split osteotomy using Piezosurgery. *Plastic and Reconstructive Surgery*, 118(7), 1598–1607.
- Hackney, F. L., Van Sickels, J. E., & Nummikoski, P. V. (1989). Condylar displacement and temporomandibular joint dysfunction following bilateral sagittal split osteotomy and rigid fixation. *Journal of Oral and Maxillofacial Surgery*, 47(3), 223–227.
- Hammoudeh, J. A., Howell, L. K., Boutros, S., Scott, M. A., & Urata, M. M. (2015). Current status of surgical planning for orthognathic surgery: Traditional methods versus 3D surgical planning. *Plastic and Reconstructive Surgery - Global Open*, 3(2), e307.
- Harper, R. P., de Bruin, H., Burcea, I., & Engl, B. (1987). Lateral pterygoid muscle activity in mandibular retrognathism and response to mandibular advancement surgery. *American Journal of Orthodontics and Dentofacial Orthopedics*.
- Helkimo, M. (1974a). Studies on function and dysfunction of the masticatory system. *Acta Odontologica Scandinavica*, 32(4), 255–267.
- Helkimo, M. (1974b). Studies on function and dysfunction of the masticatory system. II. Index for anamnestic and clinical dysfunction and occlusal state. *Svensk Tandlakare Tidskrift. Swedish Dental Journal*, 67(2), 101–121.
- Helland, M. M. (1979). Anatomy and function of the temporomandibular joint. *Journal of Orthopaedic and Sports Physical Therapy*, 1(3), 145–152.
- Holmlund, A. B., Axelsson, S., & Gynther, G. W. (2001). A comparison of discectomy and arthroscopic lysis and lavage for the treatment of chronic closed lock of the

- temporomandibular joint: A randomized outcome study. *Journal of Oral and Maxillofacial Surgery*, 59(9), 972–977.
- Hori, M., Okaue, M., Harada, D., Ono, M., Goto, T., Tada, Y., Kamogawa, D., Matsumoto, M., & Tanaka, H. (1999). Releasing severe adhesions around the eminence and the synovial portion of the TMJ: a clinical study of combined treatment using hydraulic lavage, arthroscopic surgery and rehabilitative therapy. *Journal of Oral Science*, 41(2), 61–66.
<http://www.ncbi.nlm.nih.gov/pubmed/10453128>
- Hunsuck, E. E. (1968). A modified intraoral sagittal splitting technic for correction of mandibular prognathism. *Journal of Oral Surgery (American Dental Association : 1965)*, 26(4), 250–253.
- Huppa, C., & Mack, G. (2017). Sagittal Split Osteotomy and Mandibular Advancement. In F. B. Naini & D. S. Gill (Eds.), *Orthognathic Surgery: Principles, Planning and Practice* (pp. 428–439). John Wiley & Sons, Ltd.
- Iannetti, G., Fadda, T. M., Riccardi, E., Mitro, V., & Filiaci, F. (2013). Our experience in complications of orthognathic surgery: A retrospective study on 3236 patients. *European Review for Medical and Pharmacological Sciences*, 17(3), 379–384.
- Ingervall, B. (1971). Variation of the range of movement of the mandible in relation to facial morphology in young adults. *Scandinavian Journal of Dental Research*, 79(2), 133–140.
- Inui, M., Fushima, K., & Sato, S. (1999). Facial asymmetry in temporomandibular joint disorders. *Journal of Oral Rehabilitation*, 26(5), 402–406.
- John, M. T., Miglioretti, D. L., LeResche, L., Von Korff, M., & Critchlow, C. W. (2003). Widespread pain as a risk factor for dysfunctional temporomandibular disorder pain. *Pain*, 102(3), 257–263.
- Jung, H.-D., Kim, S. Y., Park, H.-S., & Jung, Y.-S. (2015). Orthognathic surgery and temporomandibular joint symptoms. *Maxillofacial Plastic and Reconstructive Surgery*,

37(1).

- Jung, W. S., Kim, H., Jeon, D. M., Mah, S. J., & Ahn, S. J. (2013). Magnetic resonance imaging-verified temporomandibular joint disk displacement in relation to sagittal and vertical jaw deformities. *International Journal of Oral and Maxillofacial Surgery*, 42(9), 1108–1115.
- Khare, N., Patil, S. B., Kale, S. M., Sumeet, J., Sonali, I., & Sumeet, B. (2012). Normal Mouth Opening in an Adult Indian Population. *Journal of Maxillofacial and Oral Surgery*, 11(3), 309–313.
- Klasser, G. D., & Greene, C. S. (2009). Oral appliances in the management of temporomandibular disorders. *Oral Surgery, Oral Medicine, Oral Pathology, Oral Radiology, and Endodontology*, 107(2), 212–223.
- Koudstaal, M. J. M. J., Poort, L. J. J., van der Wal, K. G. H. G. H., Wolvius, E. B. B., Prah Andersen, B., & Schulten, A. J. M. J. M. (2005). Surgically assisted rapid maxillary expansion (SARME): A review of the literature. *International Journal of Oral and Maxillofacial Surgery*, 34(7), 709–714.
- Kretschmer, W. B., Baciut, G., Baciut, M., & Sader, R. (2019). Effect of bimaxillary orthognathic surgery on dysfunction of the temporomandibular joint: a retrospective study of 500 consecutive cases. *British Journal of Oral and Maxillofacial Surgery*.
- Kropmans, T. J., Dijkstra, P. U., Stegenga, B., & de Bont, L. G. (1999). Therapeutic outcome assessment in permanent temporomandibular joint disc displacement. *Journal of Oral Rehabilitation*, 26(5), 357–363.
- La Touche, R., Goddard, G., De-la-Hoz, L., Wang, K., Alba Paris-Aleman, Angulo-Díaz-Parren, S., Mesa, J., & Hernandez, M. (2010). Acupuncture in the Treatment of Pain in Temporomandibular Disorders: A Systematic Review and Meta-analysis of Randomized Controlled Trials. In *Clin J Pain* (Vol. 26, Issue 6).
- Labanca, M., Azzola, F., Vinci, R., & Rodella, L. F. (2008). Piezoelectric surgery: Twenty

- years of use. *British Journal of Oral and Maxillofacial Surgery*, 46(4), 265–269.
- Landes, C. A., Stübinger, S., Ballon, A., & R., S. (2008). Piezoosteotomy in orthognathic surgery versus conventional saw and chisel osteotomy. *Oral Maxillofac Surg*, 12, 139–147.
- Laskin, D. M. (1995). The clinical diagnosis of temporomandibular disorders in the orthodontic patient. *Seminars in Orthodontics*, 1(4), 197–206.
- Leamari, V. M., Rodrigues, A. de F., Camino Junior, R., & Luz, J. G. C. (2019). Correlations between the Helkimo indices and the maximal mandibular excursion capacities of patients with temporomandibular joint disorders. *Journal of Bodywork and Movement Therapies*, 23(1), 148–152.
- LeResche, L. (1997). Epidemiology of temporomandibular disorders: Implications for the investigation of etiologic factors. In *Critical Reviews in Oral Biology and Medicine* (Vol. 8, Issue 3, pp. 291–305). International and American Associations for Dental Research.
- Levine, J. P., Patel, A., Saadeh, P. B., & Hirsch, D. L. (2012). Computer-Aided Design and Manufacturing in Craniomaxillofacial Surgery. *Journal of Craniofacial Surgery*, 23(1), 288–293.
- Liou, E. J. W., Chen, P.-H., Wang, Y.-C., Yu, C.-C., Huang, C. S., & Chen, Y.-R. (2011). Surgery-First Accelerated Orthognathic Surgery: Orthodontic Guidelines and Setup for Model Surgery. *Journal of Oral and Maxillofacial Surgery*, 69(3), 771–780.
- Luhr, H. G., Kubein-Meesenburg, D., & Schwestka-Polly, R. (1991). The importance and technic of temporomandibular joint positioning in the sagittal splitting of the mandible. *Fortschritte Der Kieferorthopadie*, 52(2), 66–72.
- M Robiony, Polini, F., Costa, F., Zerman, N., & Politi, M. (2007). Ultrasonic bone cutting for surgically assisted rapid maxillary expansion (SARME) under local anaesthesia. *Int J Oral Maxillofac Surg*, 36(3), 267–269.

- Magnusson, A., Bjerklin, K., Kim, H., Nilsson, P., & Marcusson, A. (2012). Three-dimensional assessment of transverse skeletal changes after surgically assisted rapid maxillary expansion and orthodontic treatment: A prospective computerized tomography study. *American Journal of Orthodontics and Dentofacial Orthopedics*, 142(6), 825–833.
- Magnusson, T., Ahlborg, G., & Svartz, K. (1990). Function of the masticatory system in 20 patients with mandibular hypo- or hyperplasia after correction by a sagittal split osteotomy. *International Journal of Oral and Maxillofacial Surgery*.
- Magnusson, T., Egermark, I., & Carlsson, G. E. (2000). A Longitudinal Epidemiologic Study of Signs and Symptoms of Temporomandibular Disorders from 15 to 35 Years of Age. *Journal of Orofacial Pain*.
- Maixner, W., Diatchenko, L., Dubner, R., Fillingim, R. B., Greenspan, J. D., Knott, C., Ohrbach, R., Weir, B., & Slade, G. D. (2011). Orofacial pain prospective evaluation and risk assessment study - The OPPERA study. *Journal of Pain*, 12(11 SUPPL.), T4-11.e1-2.
- Manfredini, D., Guarda-Nardini, L., Winocur, E., Piccotti, F., Ahlberg, J., & Lobbezoo, F. (2011). Research diagnostic criteria for temporomandibular disorders: A systematic review of axis i epidemiologic findings. *Oral Surgery, Oral Medicine, Oral Pathology, Oral Radiology and Endodontology*, 112(4), 453–462.
- Mazengo, M. C., & Kirveskari, P. (1991). Prevalence of craniomandibular disorders in adults of Ilala District, Dar-es-Salaam, Tanzania. *Journal of Oral Rehabilitation*, 18(6), 569–574.
- Mehra, P., Downie, M., Pita, M. C., & Wolford, L. M. (2001). Pharyngeal airway space changes after counterclockwise rotation of the maxillomandibular complex. *American Journal of Orthodontics and Dentofacial Orthopedics*, 120(2), 154–159.
- Melis, M., Di Giosia, M., & Zawawi, K. H. (2012). Low Level Laser Therapy for the Treatment of Temporomandibular Disorders: A Systematic Review of the Literature. *CRANIO®*, 30(4), 304–312.

- Mense, S. (2003). The pathogenesis of muscle pain. *Current Pain and Headache Reports*, 7(6), 419–425.
- Mezitis, M., Rallis, G., & Zachariades, N. (1989). The normal range of mouth opening. *Journal of Oral and Maxillofacial Surgery : Official Journal of the American Association of Oral and Maxillofacial Surgeons*, 47(10), 1028–1029.
- Miguel, J. A. M., Palomares, N. B., & Feu, D. (2014). Life-quality of orthognathic surgery patients: the search for an integral diagnosis. *Dental Press Journal of Orthodontics*, 19(1), 123–137.
- Mongini, F. (1983). Influence of function on temporomandibular joint remodeling and degenerative disease. *Dental Clinics of North America*, 27(3), 479–494.
- Mujakperuo, H. R., Watson, M., Morrison, R., & Macfarlane, T. V. (2010). Pharmacological interventions for pain in patients with temporomandibular disorders. *Cochrane Database of Systematic Reviews*, 10, CD004715.
- Nokar, S., Sadighpour, L., Shirzad, H., Shahrokhi Rad, A., & Keshvad, A. (2018). Evaluation of signs, symptoms, and occlusal factors among patients with temporomandibular disorders according to Helkimo index. *CRANIO®*, 1–6.
- Nourallah, H., & Johansson, A. (1995). Prevalence of signs and symptoms of temporomandibular disorders in a young male Saudi population. *Journal of Oral Rehabilitation*, 22(5), 343–347.
- Okeson, J. P. (2008). Management of Temporomandibular Disorders and Occlusion. In *Journal of Prosthetic Dentistr.*
- Okeson, J. P., & de Leeuw, R. (2011). Differential Diagnosis of Temporomandibular Disorders and Other Orofacial Pain Disorders. In *Dental Clinics of North America* (Vol. 55, Issue 1, pp. 105–120).
- Onizawa, K., Schmelzeisen, R., & Vogt, S. (1995). Alteration of temporomandibular joint

- symptoms after orthognathic surgery. Comparison with healthy volunteers. *Journal of Oral and Maxillofacial Surgery*.
- Pahkala, R. H., & Heino, J. P. (2004). Effects of sagittal split ramus osteotomy on temporomandibular disorders in seventy-two patients. *Acta Odontologica Scandinavica*, 62(4), 238–244.
- Pahkala, R. H., & Kellokoski, J. K. (2007). Surgical-orthodontic treatment and patients' functional and psychosocial well-being. *American Journal of Orthodontics and Dentofacial Orthopedics*, 132(2), 158–164.
- Panula, K., Somppi, M., Finne, K., & Oikarinen, K. (2005). Effects of orthognathic surgery on temporomandibular joint dysfunction. *International Journal of Oral and Maxillofacial Surgery*, 29(3), 183–187.
- Paunonen, J., Helminen, M., Sipilä, K., & Peltomäki, T. (2019). Temporomandibular disorders in Class II malocclusion patients after surgical mandibular advancement treatment as compared to non-treated patients. *Journal of Oral Rehabilitation*, 46(7), joor.12790.
- Pavlíková, G., Foltán, R., Horká, M., Hanzelka, T., Borunská, H., & Šedý, J. (2011). Piezosurgery in oral and maxillofacial surgery. *International Journal of Oral and Maxillofacial Surgery*, 40(5), 451–457.
- Pawar, R., Gulve, N., Nehete, A., Dhope, S., Deore, D., & Chinglembi, N. (2016). Examination of the Temporomandibular Joint- A Review. *Journal of Applied Dental and Medical Sciences*, 2(1).
- Pedroni, C., Oliveira Furquin, T., Nunes Ferreira, H., Cristina Trugilio, R., Silva Nitsch, G., Morais De Oliveira, F., Sakai, E., & Siriani De Oliveira, A. (2011). Posture, TMJ and cervical range of motion in different occlusal classes. *Physiotherapy (United Kingdom)*.
- Posselt, U., & Nevstedt, P. (1961). Registration of the condyle path inclination by intraoral wax records-Its practical value. *The Journal of Prosthetic Dentistry*, 11(1), 43–47.

- Proffit, W. R., Turvey, T. A., & Phillips, C. (1996). Orthognathic surgery: a hierarchy of stability. *The International Journal of Adult Orthodontics and Orthognathic Surgery*, 11(3), 191–204.
- Rani, S., Pawah, S., Gola, S., & Bakshi, M. (2017). Analysis of Helkimo index for temporomandibular disorder diagnosis in the dental students of Faridabad city: A cross-sectional study. *Journal of Indian Prosthodontic Society*, 17(1), 48–52.
- Reston, J. T., & Turkelson, C. M. (2003). Meta-analysis of surgical treatments for temporomandibular articular disorders. *Journal of Oral and Maxillofacial Surgery*, 61(1), 3–10.
- Rodrigues-Garcia, R. C., Sakai, S., Rugh, J. D., Hatch, J. P., Tiner, B. D., van Sickels, J. E., Clark, G. M., Nemeth, D. Z., & Bays, R. A. (1998). Effects of major Class II occlusal corrections on temporomandibular signs and symptoms. *Journal of Orofacial Pain*, 12(3), 185–192.
- Rude, K., Svensson, P., & Starch-Jensen, T. (2019). Neurosensory Disturbances After Bilateral Sagittal Split Osteotomy Using Piezoelectric Surgery: A Systematic Review. *Journal of Oral and Maxillofacial Surgery*, 77(2), 380–390.
- Schellhas, K. P., Piper, M. A., & Omlie, M. R. (1990). Facial skeleton remodeling due to temporomandibular joint degeneration: an imaging study of 100 patients. *AJNR. American Journal of Neuroradiology*, 11(3), 541–551.
- Schellhas, K. P., Pollei, S. R., & Wilkes, C. H. (1993). Pediatric internal derangements of the temporomandibular joint: Effect on facial development. *American Journal of Orthodontics and Dentofacial Orthopedics*, 104(1), 51–59.
- Schiffman, E. L., Look, J. O., Hodges, J. S., Swift, J. Q., Decker, K. L., Hathaway, K. M., Templeton, R. B., & Friction, J. R. (2007). Randomized effectiveness study of four therapeutic strategies for TMJ closed lock. *Journal of Dental Research*, 86(1), 58–63.

- Schiffman, E. L., Velly, A. M., Look, J. O., Hodges, J. S., Swift, J. Q., Decker, K. L., Anderson, Q. N., Templeton, R. B., Lenton, P. A., Kang, W., & Fricton, J. R. (2014). Effects of four treatment strategies for temporomandibular joint closed lock. *International Journal of Oral and Maxillofacial Surgery*, 43(2), 217–226.
- Scrivani, Steven J.; Keith David A.. Kaban, L. B. (2008). Temporomandibular disorders. *The New England Journal of Medicine*, 221–228.
- Seward, G. R. (1983). Clinical management of temporomandibular disorders. *Journal of Dentistry*, 11(4), 364.
- Shen, G., & Darendeliler, M. A. (2005). The Adaptive Remodeling of Condylar Cartilage— A Transition from Chondrogenesis to Osteogenesis. *Journal of Dental Research*, 84(8), 691–699.
- Singh, S., & Varghese, D. (2013). Single puncture arthrocentesis of temporomandibular joint; introducing a novel device: A pilot study. *National Journal of Maxillofacial Surgery*, 4(2), 193.
- Sinialu, V., & Akermann, S. (2016). Temporomandibular disorders. *Eesti Arst*, 95(7), 455–459.
- Sostmann, M., Meyer, J., & Berten, J. L. (1991). TMJ-function following orthognathic surgery. *Deutsche Stomatologie (Berlin, Germany : 1990)*, 41(12), 487–489.
- Steinhuber, T., Brunold, S., Gärtner, C., Offermanns, V., Ulmer, H., & Ploder, O. (2018). Is Virtual Surgical Planning in Orthognathic Surgery Faster Than Conventional Planning? A Time and Workflow Analysis of an Office-Based Workflow for Single- and Double-Jaw Surgery. *Journal of Oral and Maxillofacial Surgery*, 76(2), 397–407.
<https://www.sciencedirect.com/science/article/pii/S0278239117310042>
- Suri, L., & Taneja, P. (2008). Surgically assisted rapid palatal expansion: A literature review. *American Journal of Orthodontics and Dentofacial Orthopedics*, 133(2), 290–302.

- Takahashi, H., Moriyama, S., Furuta, H., Matsunaga, H., Sakamoto, Y., & Kikuta, T. (2010). Three lateral osteotomy designs for bilateral sagittal split osteotomy: Biomechanical evaluation with three-dimensional finite element analysis. *Head and Face Medicine*, 6(1), 4.
- te Veldhuis, E. C., te Veldhuis, A. H., Bramer, W. M., Wolvius, E. B., & Koudstaal, M. J. (2017). The effect of orthognathic surgery on the temporomandibular joint and oral function: a systematic review. *International Journal of Oral and Maxillofacial Surgery*, 46(5), 554–563.
- Tozoglu, S., Al-Belasy, F. A., & Dolwick, M. F. (2011). A review of techniques of lysis and lavage of the TMJ. *British Journal of Oral and Maxillofacial Surgery*, 49(4), 302–309.
- Trauner, R., & Obwegeser, H. (1957). The surgical correction of mandibular prognathism and retrognathia with consideration of genioplasty. *Oral Surgery, Oral Medicine, Oral Pathology*, 10(7), 677–689.
- Tvrdy, P., Heinz, P., & Pink, R. (2015). Arthrocentesis of the temporomandibular joint: A review. *Biomedical Papers*, 159(1), 031–034.
- Ueki, K., Marukawa, K., Hashiba, Y., Nakagawa, K., Degerliyurt, K., & Yamamoto, E. (2008). Assessment of the Relationship Between the Recovery of Maximum Mandibular Opening and the Maxillomandibular Fixation Period After Orthognathic Surgery. *Journal of Oral and Maxillofacial Surgery*, 66(3), 486–491.
- Van Der Weele, L. T., & Dibbets, J. M. H. (1987). Helkimo's index: a scale or just a set of symptoms? *Journal of Oral Rehabilitation*, 14(3), 229–237.
- Van Sickels, J. E., Tiner, B. D., & Alder, M. E. (1997). Condylar torque as a possible cause of hypomobility after sagittal split osteotomy: Report of three cases. *Journal of Oral and Maxillofacial Surgery*, 55(4), 398–402.
- Walsh, B. L. J. (2007). Piezosurgery: an increasing role in dental hard tissue surgery.

- Australasian Dental Practice, *October*, 3–5.
- Wänman, A. (1996). Longitudinal course of symptoms of craniomandibular disorders in men and women: A 10-year follow-up study of an epidemiologic sample. *Acta Odontologica Scandinavica*, 54(6), 337–342.
- Westermarck, A., Shayeghi, F., & Thor, A. (2001). Temporomandibular dysfunction in 1,516 patients before and after orthognathic surgery. *The International Journal of Adult Orthodontics and Orthognathic Surgery*.
- White, C. S., & Dolwick, M. F. (1992). Prevalence and variance of temporomandibular dysfunction in orthognathic surgery patients. *The International Journal of Adult Orthodontics and Orthognathic Surgery*, 7(1), 7–14.
- Wirthlin, J. O., & Shetye, P. R. (2013). Orthodontist's Role in Orthognathic Surgery. *Seminars in Plastic Surgery*, 27(3), 137–144.
- Woelfel, J. B., Igarashi, T., & Dong, J.-K. (2014). Faculty-supervised measurements of the face and of mandibular movements on young adults. *The Journal of Advanced Prosthodontics*, 6(6), 483–490.
- Wolford, L. M., Reiche-Fischel, O., & Mehra, P. (2003). Changes in temporomandibular joint dysfunction after orthognathic surgery. *Journal of Oral and Maxillofacial Surgery*, 61(6), 655–660. <https://www.sciencedirect.com/science/article/pii/S027823910300106X>
- Wolford, L. M., Rodrigues, D. B., & Limoeiro, E. (2011). Orthognathic and TMJ surgery: Postsurgical patient management. *Journal of Oral and Maxillofacial Surgery*, 69(11), 2893–2903.
- Woods, M., Wiesenfeld, D., & Probert, T. (1997). Surgically-assisted maxillary expansion. *Australian Dental Journal*, 42(1), 38–42.
- Yazdani, J., Ebrahimi, H., Talesh, K. T., Khashabi, E., Pourshahidi, S., & Tadbir, A. A. (2010). Comparing the effect of 3 orthognathic surgical methods on the mandibular range of

movement. *Journal of Craniofacial Surgery*, 21(3), 703–705.

Young, A. (2016). Internal derangements of the temporomandibular joint: A review of the anatomy, diagnosis, and management. *The Journal of Indian Prosthodontic Society*, 15(1), 2.

Zanetta-Barbosa, D., Castro, V., Cunha, L. R., Marques, K. L., Miranda, W., & Prado, C. J. (2013). Orthognathic surgery associated or not to TMJ surgery: a pilot study. *International Journal of Oral and Maxillofacial Surgery*, 42(10), 1341.

10 List of figures

Figure 1. Anatomy of the pterygomandibular joint (sagittal section). A. open, B closed. Adapted from Buhmann & Lotzmann, 2000	11
Figure 2. Arthrocentesis. Two needles are placed in the upper compartment of the TMJ. Ringer’s solution is flushed through this compartment (courtesy of LKH Feldkirch)	20
Figure 3. Arthroscopic lysis and lavage. Arthroscopy probes inserted into joint space (courtesy of LKH Feldkirch).....	21
Figure 4. Articulator simulation with the KD-MMS system by Ehmer and Joos. A. The situation before movement of the segments, red plate visible; B. Movement of the upper jaw, white plaster indicates the position of the upper jaw; C. Final position of both jaws, white plaster in each segment (courtesy of LKH Feldkirch).....	25
Figure 5. Le Fort I osteotomy. Fixation with 2.0 miniplates and screws done following osteotomy (courtesy of LKH Feldkirch).....	28
Figure 6. Intraoperative pictures of bilateral sagittal split osteotomy. A. osteotomy with piezoelectric device, B. splitting of bone segments,.....	31
Figure 7 – A flexible osteosynthesis plate by Medartis (courtesy of Medartis).....	34
Figure 8. Use of fixed orthodontic appliance in pre-surgical orthodontic treatment phase after alignment of the upper and lower arch (courtesy of LKH Feldkirch).....	35
Figure 9. Chart showing patient selection.....	36
Figure 10. Use of radioopaque skin markers. A. placement of the markers. B. markers visible in radiograph (courtesy of LKH Feldkirch).....	38
Figure 11. Patient in Natural Head Orientation (NHO) (courtesy of LKH Feldkirch).....	39
Figure 12. Patient digital photographs imported into Dolphin orthognathic surgery planning software (courtesy of LKH Feldkirch)	41
Figure 13. 2D planning. Without soft tissue imposition and as a soft tissue overlay (courtesy of LKH Feldkirch)	42
Figure 14. 3D planning. The tooth-bearing segment is indicated blue and the condyles yellow. The blue segment will be moved forward to the final dental occlusion. Changes to facial appearance are visualized on the overlay of the pictures (courtesy of LKH Feldkirch).....	42

Figure 15. Computer-aided design to fabricate the surgical splint. A. wafer design. B. 3D-view of the splint (courtesy of LKH Feldkirch).....	43
Figure 16. Screenshot of the database (Frontend_Kiefer® licensed to O. Ploder). Selected fields of the first exam prior to orthodontic treatment. Timepoint T0 (courtesy of Prof. Ploder)	48
Figure 17. Screenshot of the database (Frontend_Kiefer® licensed to O. Ploder). Selected fields of the exam six months after orthognathic surgery. Timepoint T2 (courtesy of Prof. Ploder)	49
Figure 18. Screenshot of the database (Frontend_Kiefer® licensed to O. Ploder). Selected fields of the exam twelve months after orthognathic surgery. Timepoint T3 (courtesy of Prof. Ploder)	50
Figure 19. Screenshot of the database (Frontend_Kiefer® licensed to O. Ploder). Selected fields of the exam 24 months after orthognathic surgery. Timepoint T4 (courtesy of Prof. Ploder)	51
Figure 20. Maximum mouth opening before and after orthognathic surgery (mm).....	56
Figure 21. Lateral excursion left side before and after orthognathic surgery.....	56
Figure 22. Lateral excursion right side before and after orthognathic surgery	57
Figure 23. Protrusion before and after orthognathic surgery	57
Figure 24. Relative frequency of pain before and after orthognathic surgery	60
Figure 25. Relative frequencies of clicking before and after orthognathic surgery	60
Figure 26. Relative frequency of crepitus before and after orthognathic surgery	61
Figure 27. Barplot: Frequency of preoperative symptom-free patients (female/male) with at least one or without clinical symptoms at T1	63
Figure 28. Barplot: Frequency of preoperative symptom-free patients (female/male) with at least one or without clinical symptoms at T4	63
Figure 29. Barplot: Frequency of preoperative symptom-free patients (class II/class III) with at least one or without clinical symptoms at T1	64
Figure 30. Barplot: Frequency of preoperative symptom-free patients (class II/class III) with at least one or without clinical symptoms at T4	64
Figure 31. Barplot: Frequency of preoperative symptom-free patients (advancement/setback) with at least one or without clinical symptoms at T1	65
Figure 32. Frequency of preoperative symptom-free patients (advancement/setback) with at least one or without clinical symptoms at T4	65

Figure 33. Barplot: Frequency of preoperative symptom-free patients (advancement ≥ 7 mm / < 7 mm) with at least one or without clinical symptoms at T1	66
Figure 34. Barplot: Frequency of preoperative symptom-free patients (advancement ≥ 7 mm / < 7 mm) with at least one or without clinical symptoms at T4	66
Figure 35. Barplot: Frequency of preoperative symptom-free patients (CCR/ No rotation) with at least one or without clinical symptoms at T1	67
Figure 36. Barplot: Frequency of preoperative symptom-free patients (CCR/ No rotation) with at least one or without clinical symptoms at T4	67
Figure 37. Barplot: Frequency of preoperative symptom-free patients (CR/ No rotation) with at least one or without clinical symptoms at T1	68
Figure 38. Barplot: Frequency of preoperative symptom-free patients (CR/ No rotation) with at least one or without clinical symptoms at T4	68
Figure 39. The relative frequency of Di before and after orthognathic surgery	73

11 List of tables

Table 1. AAOP Diagnostic classification of TMD	17
Table 2. Clinical assessment of Helkimo score.....	52
Table 3. Descriptive statistics	54
Table 4. TMJ function before and after orthognathic surgery (MMO, excursion, protrusion)	55
Table 5. TMD symptoms (pain, clicking, crepitus) before and after orthognathic surgery	59
Table 6. Odds ratios for postoperative severe dysfunction (Di 2/3) at T1 to T4.....	69
Table 7. Odds ratios for at least one postoperative clinical sign and symptom of TMD (T1 to T4)	70
Table 8. Odds ratios for postoperative clinical signs and symptoms (pain and clicking) at T1 to T4.....	71
Table 9. Dysfunction index from T0 – T4	72
Table 10. Dysfunction index by Helkimo before surgery (T0) and one year postoperative (T2)	74
Table 11. Dysfunction index by Helkimo before surgery (T0) and two years postoperative (T4).....	74