

**CASE REPORT**

# Clinical implications of the incidental finding of a free-floating thrombus in the internal carotid artery

Johanna Härtl MD<sup>1</sup> | Mark Mühlau MD<sup>1</sup> | Verena Pernpeintner MD<sup>1</sup> |  
 Chistian Seifert MD<sup>1</sup> | Kornelia Kreiser MD<sup>2</sup> | Christoph Schäffer MD<sup>3</sup> |  
 Silke Wunderlich MD<sup>1</sup> | Benno Ikenberg MD<sup>1</sup>

<sup>1</sup>Neurologische Klinik und Poliklinik, Klinikum rechts der Isar, TU-München, München, Germany

<sup>2</sup>Abteilung für Diagnostische und Interventionelle Neuroradiologie, Klinikum rechts der Isar, TU-München, München, Germany

<sup>3</sup>Klinik und Poliklinik für Vaskuläre und Endovaskuläre Chirurgie, Klinikum rechts der Isar, TU-München, München, Germany

**Correspondence**

Benno Ikenberg, Klinik für Neurologie, Klinikum rechts der Isar der Technischen Universität München, Ismaningerstraße 22, 81675 München, Germany.  
 Email: benno.ikenberg@tum.de

**Abstract**

We present an 81-year old male in whom a routine carotid artery ultrasonographic follow-up examination incidentally revealed a large, free-floating thrombus (FFT) of the right internal carotid artery. This case focuses on the clinical decision-making regarding FFTs, which constitute a rare condition lacking a diagnostic gold standard with few available data concerning optimum treatment and natural course—in particular regarding patients in whom FFT is an incidental finding. We were able to demonstrate the accuracy of carotid artery ultrasonography in the detection as well as follow-up of FFT. Of clinical interest is furtherly a possible partial disappearance by spontaneous re-adhesion or resolution of the FFT.

**KEYWORDS**

carotid ultrasonography, free-floating thrombus, incidental findings

## 1 | INTRODUCTION

Ultrasonography of the extra- and intracranial arteries is an established routine diagnostic tool in the etiological classification of acute ischemic strokes.<sup>1</sup> Further, it provides a dynamic tool in follow-up examinations of the suspected etiology of brain ischemia, such as progressive artery disease, dissection, or floating structures.<sup>2,3</sup> Due to its widespread availability, the number of applications may further increase in the future. Hereby, it may also result in a growing number of incidental findings.<sup>4</sup> In the following case, we demonstrate the clinical implications of an incidental finding on a carotid ultrasonographic examination.

## 2 | CLINICAL CASE

An 81-year old male patient presented in our outpatient clinic for neurovascular diseases for a follow-up ultrasonographic

examination of extra- as well as intracranial arteries and clinical examination. The previous year, he had been diagnosed with a symptomatic high-grade stenosis of the basilar artery. In the routine carotid ultrasonographic examination of the anterior and posterior circulation, the stenosis of the basilar artery was considered stable with a peak systolic velocity of 180 cm/s. Additionally, a new and large inhomogeneous mobile structure, which we considered as free-floating thrombus (FFT) of the right internal carotid artery, became apparent (Figure 1; Videos S1 and S2). Although no clinical symptoms were present at consultation, urgent stationary admission to our stroke unit was initiated for further clinical and neurosonographic monitoring as well as evaluation of therapeutic procedures. A first cranial magnetic-resonance imaging (cMRI) did not reveal a brain infarction. A MR-Angiography of intracranial as well as neck vessels showed known atherosclerotic pathologies, but nothing corresponding to the

This is an open access article under the terms of the Creative Commons Attribution-NonCommercial License, which permits use, distribution and reproduction in any medium, provided the original work is properly cited and is not used for commercial purposes.

© 2020 The Authors. *Journal of Clinical Ultrasound* published by Wiley Periodicals, Inc.

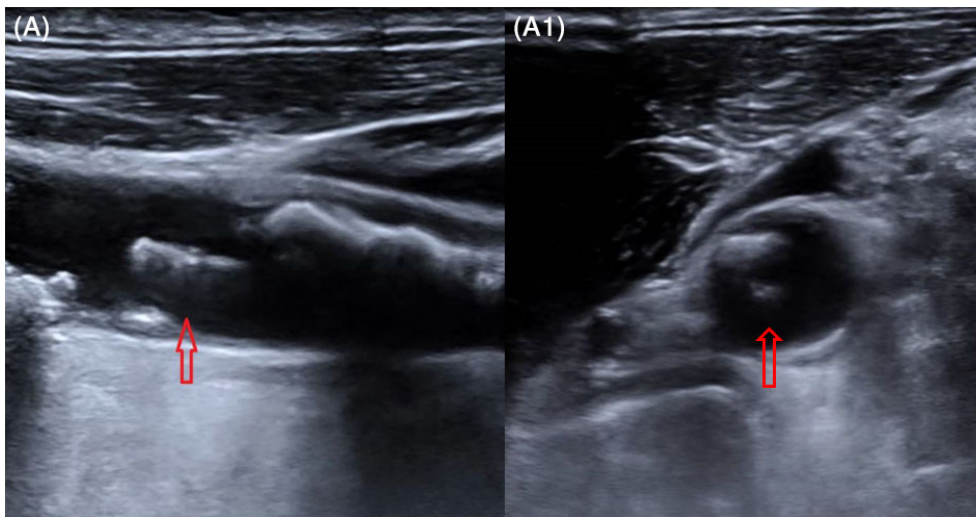
floating structure detected by ultrasonography. Interdisciplinary consideration regarding optimum treatment included surgical, interventional, and medicinal approaches. The risk of a severe embolic stroke was considered significant and an immediate emergency operation offered. This was declined by the patient. Following a watchful waiting strategy, a preexisting medication with aspirin 100 mg was continued and a lipid lowering statin therapy was increased to 80 mg atorvastatin. Furtherly, a more aggressive medical treatment or an endovascular mechanical thrombectomy were discussed. Two days after diagnosis, the FFT could not be detected by ultrasound examination anymore (Figure 2). The patient was still asymptomatic. A thereupon performed second cMRI showed a subacute infarction in the superior occipital gyrus, which, in this patient, belonged to the territory of the right carotid artery because of a congenital variant of the posterior cerebral artery (Figure 3). The patient was discharged in an unchanged general condition with the diagnosis of silent brain infarction caused by an incidentally discovered FFT. During regular follow-up examinations in our outpatient clinic over 15 months, he was clinically and sonographically stable—without

detection of another FFT under a continuing medication of 100 mg aspirin and 80 mg atorvastatin.

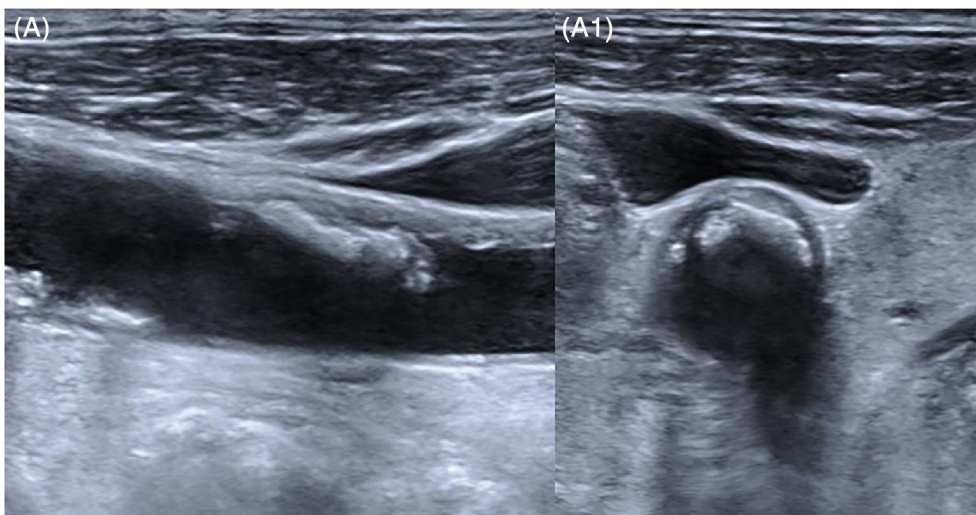
### 3 | DISCUSSION

We present an 81-year old male with the incidental finding of a large, inhomogeneous FFT of the right internal carotid artery resulting in a clinically silent brain infarction. The patient gave informed consent for publication of his case.

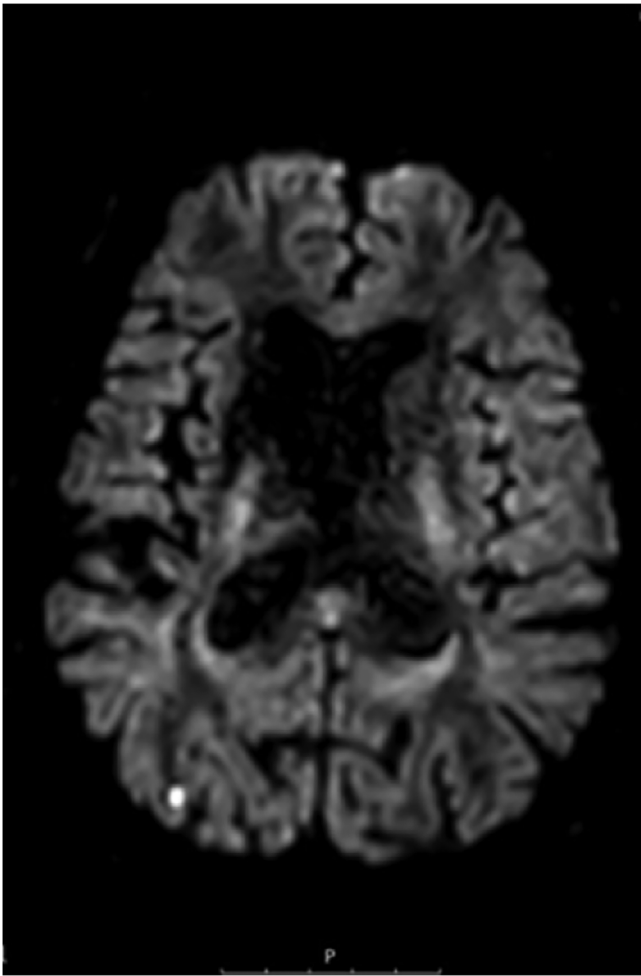
FFT are commonly defined as “an elongated thrombus attached to the arterial wall with circumferential blood flow at its distal most aspect with cyclical motion relating to cardiac cycle.”<sup>5</sup> In this context, we critically point to the large overlap and lack of consistent definition in literature concerning FFT and mobile plaques. Although the above definition seems appropriate for our case, the mobile structure presented partly fulfills characteristics of a mobile plaque.<sup>6</sup> Despite this uncertainty, we argue that the clinical significance is based on the mobile component of both pathologies and, therefore, our case-report and its conclusions are most likely valid for both entities.



**FIGURE 1** Initial carotid ultrasonographic image showing a free-floating thrombus or plaque in the right internal carotid artery attached to a known arteriosclerotic plaque. A = longitudinal projection, A1 = transversal projection



**FIGURE 2** Ultrasonographic examination of the right internal carotid artery 2 days after stroke unit admission. The free-floating structure could no longer be detected. A = longitudinal projection, A1 = transversal projection



**FIGURE 3** Cranial magnetic-resonance imaging (cMRI) detecting a subacute infarction in the right posterior media territory or posterior territory based on a congenital variant of the posterior cerebral artery

FFT constitute a rare, but known, cause of cerebral ischemia. The prevalence of FFT is described at about 1.5% to 1.6% in stroke or transient ischemic attack (TIA) patients.<sup>7,8</sup> Carotid artery ultrasonography is not only of importance for a first diagnosis, but furthermore provides an ideal monitoring method.<sup>7,9</sup> Regarding the prognosis, Fridman et al found a 17.1% risk of TIA, silent brain ischemia, stroke, or death in a 30-day follow-up of patients admitted to hospital for acute ischemic stroke. Despite this high short-term morbidity and mortality, a therapeutic gold standard has not been established: There are several studies, including a recent prospective work and a meta-analysis, as well as case reports on medical, surgical, and interventional approaches without a clear superiority regarding the clinical outcome. Inter alia, there are reports of different types of antiplatelet therapy including aspirin, clopidogrel, and ticlopidine, anticoagulation by either heparin, enoxaparin, dalteparin, or warfarin, off-label uses of dabigatran or apixaban, surgical thrombectomy, and interventional stent-retriever maneuvers<sup>7,8,10,11</sup> (Table 1). Based on the infrequency of description, none of these studies particularly addresses incidental findings but rather focus on symptomatic patients admitted to hospital for stroke or TIA. Overall, incidental cases have rarely been reported; Bhatti et al found asymptomatic patients in only 4% of FFTs observed.<sup>5</sup>

Furtherly, it may be discussed whether the usage of a high-intensity transient signals (HITS) detection by transcranial Doppler ultrasonography could have posed a diagnostic advantage. A large number of HITS could have been a marker of thrombus instability. However, this was not assessed in our case.

Few data are available on the natural course of an FFT.<sup>5,7,8</sup> Besides detachment with distal embolization, a spontaneous re-adhesion or resolution have been discussed in the literature.<sup>8,12</sup> Considering the impressive mismatch between thrombus size and infarction in our case, we assumed a partial disappearance by either of

**TABLE 1** Overview of selected literature on floating mobile structures of the carotid artery, their treatment, and clinical outcome

	Year	Study	Patients included	Therapy	Result
Yonemura et al, "Disappearance of an oscillating intraluminal thrombus in the carotid artery demonstrated by ultrasonography"	2003	Case report	1	OAC: i.v. heparin, bridging warfarin INR 2.0-2.5	Good clinical outcome—Thrombus dissolved over 2 weeks
Bhatti et al, "Free-Floating Thrombus of the carotid artery: literature review and case reports"	2007	Meta-analysis	145	33 OAC 9 TAH 1 Steroids 6 Carotid artery Stenting 3 Carotid artery bypass 85 Carotid endarterectomy	Medical treatment: 20% improved, 77% stable, 3% worsened Surgery: 37% improved, 54% stable, 9% worsened
Bajkó et al, "Acute ischaemic stroke secondary to a mobile thrombus in the common carotid artery—case report"	2015	Case report	1	TAH: Aspirin, low-dose heparin	Thrombus dissolved within 1 week
Bae et al, "Carotid Artery Angioplasty and Stenting for Atherosclerotic Plaque with Mobile Intimal Flap"	2018	Case report	2	Carotid artery stenting	Good clinical outcome

(Continues)

**TABLE 1** (Continued)

	Year	Study	Patients included	Therapy	Result
Fitzpatrick et al, "Expanding the role of stent-retriever endovascular thrombectomy: a case series of free-floating thrombus"	2018	Case series	3	Endovascular thrombectomy by Stent retriever	Good clinical outcome
Singh et al, "Intraluminal Thrombi in the Cervico-Cephalic Arteries Clinical-Imaging Manifestations, Treatment Strategies, and Outcome"	2019	Prospective study	61	57 Heparin + TAH 15 Carotid endarterectomy 9 Carotid artery stenting	Good clinical outcome if treated with combination antithrombotic therapy
Fridman et al, "Diagnosis and Management of Carotid Free-Floating Thrombus: A Systematic Literature Review"	2019	Literature review	525	311 TAH (aspirin, clopidogrel, ticlopidine, cilostazol, ozagrel, dipyridamole) + OAK (heparin, enoxaparin, dalteparin, and warfarin) 24 rt-PA 7 Argatroban 5 Tirofiban 3 Edaravone 1 Dabigatran 1 Apixaban 94 Early carotid thrombectomy 64 Late carotid thrombectomy	Lack of consensus
Tolaymat et al, "Considerations beyond Stenosis for Carotid Endarterectomy in Treating Free-Floating Thrombus of the Carotid Artery"	2019	Retrospective analysis	6	6 Carotid endarterectomy (four cases of preoperative OAC)	Good clinical outcome: 4 Without restenosis 1 Clinically asymptomatic restenosis 1 Case without follow-up
Yamaguchi et al, "Rare Case of Floating Intimal Flap Associated with Atheromatous Carotid Plaque"	2019	Case report	1	Carotid endarterectomy	Good clinical outcome

Abbreviations: I.V., intravenous; OAC, oral anticoagulation; TAH, platelet inhibition therapy.

those mechanisms. Retrospectively, based on the complexity of the preexisting plaque morphology and application of two-dimensional ultrasound only, this hypothesis could not be proven and a complete detachment cannot be excluded. Nevertheless, the possibility of a spontaneous re-adhesion or resolution rather than a detachment could be of interest for the clinician as it may seem counter-intuitive and bias towards invasive options.

Lastly, the necessity of examining the anterior circulation by carotid ultrasonography in a patient who presented for a follow-up of a basilar artery stenosis may be discussed. We argue that simply monitoring the known pathology is not sufficient. In our opinion, there is a definite benefit of an entire examination of brain-supplying vessels as a coherent statement has to be based on complete hemodynamic considerations. However, a sensible indication is required in order to prevent overdiagnosis and subsequent overtreatment. This not only meets economic reasoning, but furtherly reduces the related physical and psychological stress of the patient treated due to diagnostic and therapeutic procedures.<sup>4</sup>

Concluding, we present a case that addresses two different topics of medical interest. Firstly, it raises the issue of the rare, but clinical significant, treatment, clinical management, and natural course of FFT.

Secondly, it serves as a good example of the universal medico-ethical issue of incidental findings based on non-invasive screening devices. Consequently, it reminds us to apply diagnostics, which are considered as non-invasive and therefore harmless, carefully only.

#### ORCID

Johanna Härtl  <https://orcid.org/0000-0002-2672-0175>

#### REFERENCES

- Kristensen T, Hovind P, Iversen HK, Andersen UB. Screening with Doppler ultrasound for carotid artery stenosis in patients with stroke or transient ischaemic attack. *Clin Physiol Funct Imaging*. 2018;38:617-621.
- Bennett GM, Bluth EI, Larson ML, Luo Q. Recommendations for low-grade carotid stenosis follow-up based on a single-institution database. *J Ultrasound Med*. 2018;37:439-445.
- Vicenzini E, Giannoni MF, Ricciardi MC, et al. Noninvasive imaging of carotid arteries in stroke: emerging value of real-time high-resolution sonography in carotid occlusion due to cardiac embolism. *J Ultrasound Med*. 2010;29:1635-1641.
- Brownlee S, Chalkidou K, Doust J, et al. Evidence for overuse of medical services around the world. *Lancet*. 2017;390:156-168.

5. Bhatti AF, Leon LR Jr, Labropoulos N, et al. Free-floating thrombus of the carotid artery: literature review and case reports. *J Vasc Surg.* 2007;45:199-205.
6. Coombs PR, Downie R, Phan TG. Disappearing flapping plaque in the internal carotid artery. *Ann Vasc Surg.* 2010;24:254.e7.
7. Fridman S, Lownie SP, Mandzia J. Diagnosis and management of carotid free-floating thrombus: a systematic literature review. *Int J Stroke.* 2019;14:247-256.
8. Singh RJ, Chakraborty D, Dey S, et al. Intraluminal thrombi in the cervico-cephalic arteries. *Stroke.* 2019;50:357-364.
9. Yonemura K, Kimura K, Yasaka M, et al. Disappearance of an oscillating intraluminal thrombus in the carotid artery demonstrated by ultrasonography. *Intern Med.* 2003;42:746-749.
10. Bae E, Vo TD. Carotid artery angioplasty and stenting for atherosclerotic plaque with mobile intimal flap. *Ann Vasc Surg.* 2018;49:310.e1-310.e3.
11. Fitzpatrick N, Motyer R, Gibney B, et al. Expanding the role of stent-retriever endovascular thrombectomy: a case series of free-floating thrombus. *J Neurointerv Surg.* 2018;10:1164-1167.
12. Yarnell P, Earnest M, Kelly G, Sanders B. Disappearing carotid defects. *Stroke.* 1978;9:258-262.

#### SUPPORTING INFORMATION

Additional supporting information may be found online in the Supporting Information section at the end of this article.

**How to cite this article:** Härtl J, Mühlau M, Pernpeintner V, et al. Clinical implications of the incidental finding of a free-floating thrombus in the internal carotid artery. *J Clin Ultrasound.* 2020;1-5. <https://doi.org/10.1002/jcu.22811>