

## Case Report

# Augmentation of simultaneous acetabular and femoral neck fracture in osteogenesis imperfecta using photodynamic bone stabilization — A case report

Sebastian Pesch\*, Alexander Gromer, Marc Beirer, Stefan Huber-Wagner, Peter Biberthaler, Chlodwig M. Kirchhoff

Department of Trauma Surgery, Klinikum rechts der Isar, Technical University of Munich, Ismaninger Str. 22, 81675 Munich, Germany

## ARTICLE INFO

## Keywords:

Osteogenesis imperfecta  
Fracture treatment  
Bone augmentation  
Photodynamic bone stabilization system  
Illuminoss®

## ABSTRACT

**Background:** Surgical fracture treatment in patients suffering from “osteogenesis imperfecta” (OI) is challenging and often results in unsatisfactory fixation of implants due to altered bone quality. Even the use of locking plates bears a residual risk to develop a loss of reduction leading to secondary fracture dislocation. However, the augmentation with an intramedullary photodynamic bone stabilization system (PBS) (e.g. Illuminoss®) may increase bone stability and allow for a sufficient anchorage of established implants even in OI patients.

**Case presentation:** We report the case of a 41-year-old male patient with the diagnosis of OI. He sustained a medial femoral neck fracture (Garden type IV, Pauwels type III) and a fracture of the acetabulum (AO-Type 62-B.3) – both right-sided – after a blunt trauma during a bicycle accident. The medial femoral neck fracture was subsequently surgically treated to preserve the femoral head. After augmentation of the proximal femur with the PBS, a Dynamic Hip Screw (DHS) was implanted. After a short recovery, the acetabular fracture was surgically treated by intramedullary augmentation and locking plate fixation.

The patient was discharged seven days after the surgical intervention of the acetabular fracture. Partial weight-bearing activities of the right lower extremity were performed on crutches for 6 weeks. The patient was able to do his outpatient rehabilitation program without any complications. He returned to work eight weeks after surgery. After a follow-up of four months, the patient presented full weight-bearing without assistance. No physical complaints were reported 14 months after surgery (Harris Hip Score 90).

**Conclusion:** To the best of our knowledge, we report the augmentation with a photodynamic bone stabilization system of internal fixation techniques in an OI patient with fractures of the femoral neck and the acetabulum for the first time. This advanced surgical procedure shows the high potential of intramedullary photodynamic bone stabilization in patients with minor bone quality.

## Introduction

Osteogenesis imperfecta (OI) presents a group of genetic disorders which mainly decrease bone quality resulting in an excessive bone fragility. The cause is a gene mutation that affects formation and strength of bone as well as the structure of further tissues [1].

\* Corresponding author.

E-mail address: [sebastian.pesch@mri.tum.de](mailto:sebastian.pesch@mri.tum.de) (S. Pesch).

<https://doi.org/10.1016/j.tcr.2019.100200>

Accepted 21 April 2019

Available online 14 May 2019

2352-6440/ © 2019 The Authors. Published by Elsevier Ltd. This is an open access article under the CC BY-NC-ND license (<http://creativecommons.org/licenses/by-nc-nd/4.0/>).

More precisely, the mutation is related to the collagen type I alpha 1 and collagen type I alpha 2 genes, which encode the alpha 1 and alpha 2 chain of type I procollagen, respectively. Molecular genetic studies identified > 150 mutations of these genes. The clinical classification of Sillence et al. [2] is most reliable concerning prognosis and genetic counseling. OI is categorized in four classes: type I: mild, type II: perinatal lethal, type III: progressively deforming, and type IV: moderate deforming (see Table 1). Therefore, the fracture incidence in OI-patients is increased compared to the healthy population. However, no fracture register is available for the allocation and prevalence of distinct fracture patterns in OI. In the current literature, several studies focus on improvement of bone quality in children and young patients (< 5–16 years) [3]. The surgical management of fractures in OI patients has not yet been scientifically targeted. Basically, the principles of open reduction and internal fixation according to the “Arbeitsgemeinschaft für Osteosynthesefragen” (AO) are also applicable to OI patients. However, the conventional techniques – even when using modern locking plates – are prone to secondary loss of fixation due to the altered poor bone quality in OI.

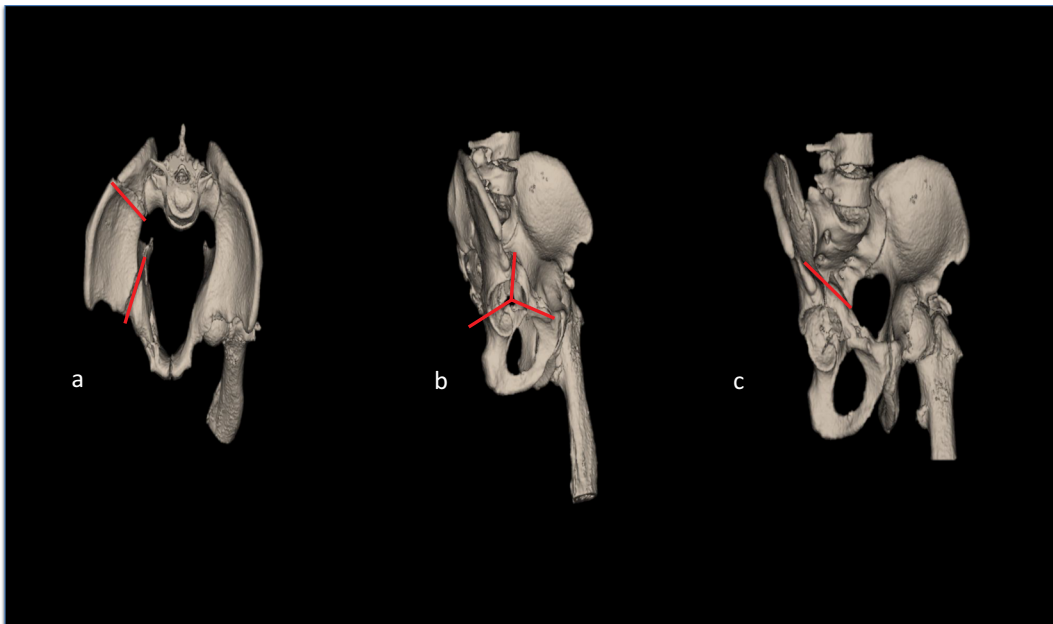
**Table 1**  
Sillence classification depicting different types of osteogenesis imperfecta.

| Type | Fracture                 | Deformity level   |
|------|--------------------------|-------------------|
| I    | Mostly during pre-school | Mild              |
| II   | Extreme bone fragility   | Severe            |
| III  | Fractures at birth       | Deforming         |
| IV   | Mostly during childhood  | Moderate severity |

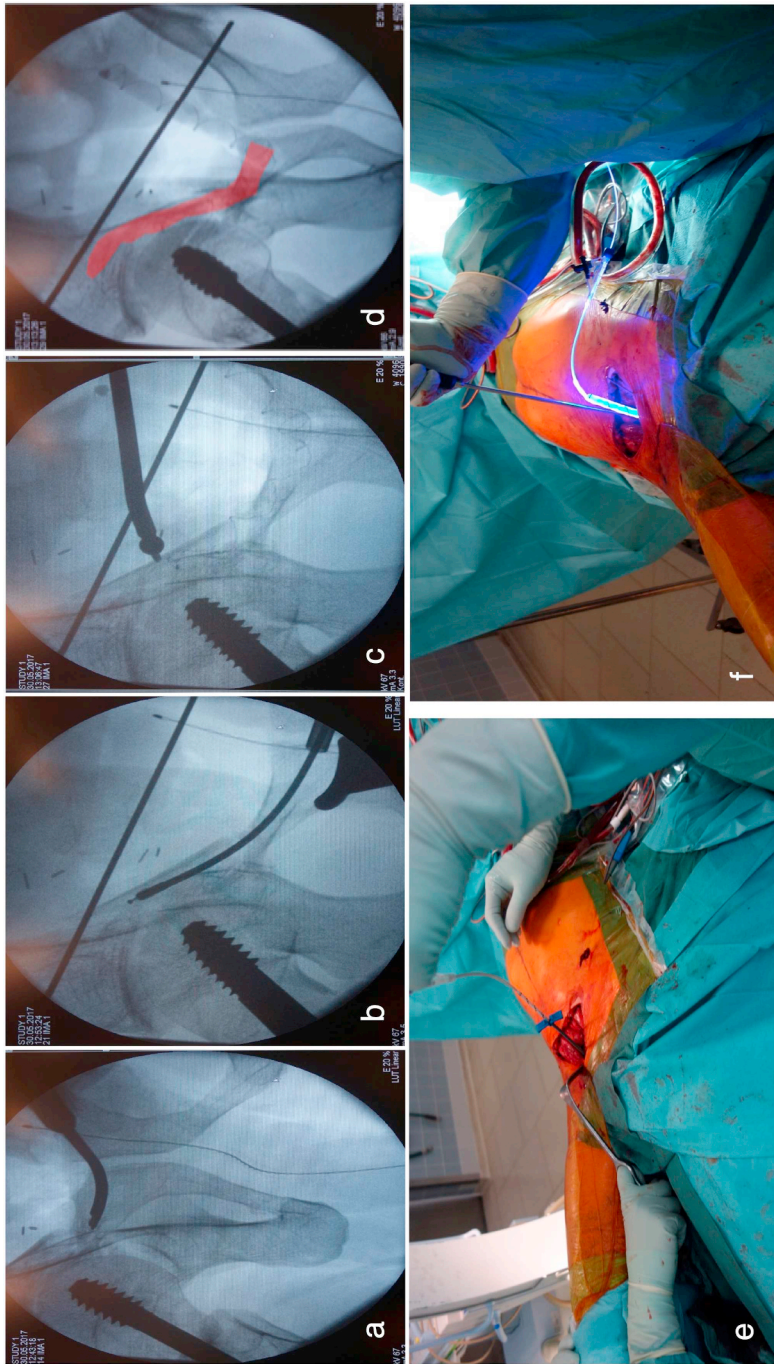
The presented case reports an intramedullary augmentation technique (PBS) to augment established implants in surgical fracture treatment of OI patients. For this minimally invasive procedure, a thin-walled polyethylene terephthalate (PET) balloon with a liquid monomer that is adjusted to the patient's anatomy is inserted into the intramedullary canal. Once the monomer has cured, the intramedullary augmentation provides longitudinal strength and rotational stability across the length of the implant.

### Case report

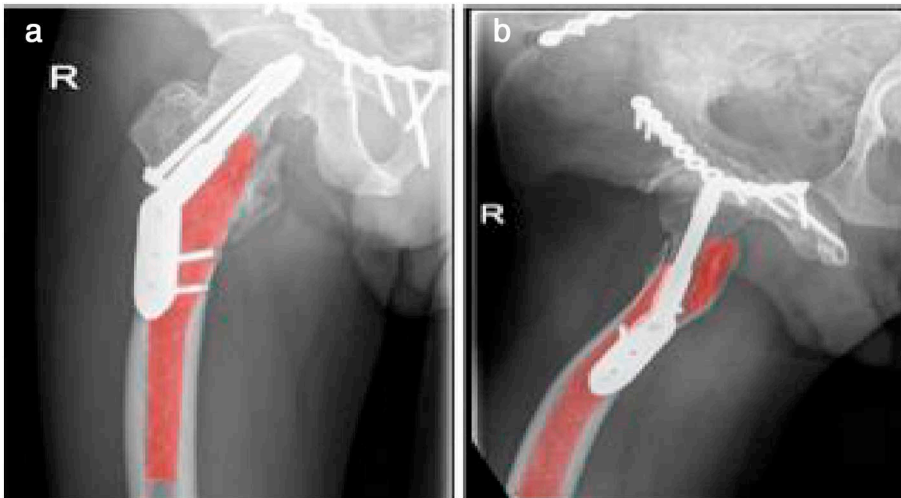
A 41-year-old patient with already known osteogenesis imperfecta (OI) type IV presented with a displaced medial femoral neck fracture (Garden type IV, Pauwels type III), as well as a fracture of the acetabulum (AO-Type 62-B.3), both on the right side after a bicycle accident (see Fig. 1). Four years ago, the patient had already sustained a stable pelvic fracture (AO-type 61-B.2) during a car accident which, was treated conservatively at our Level I trauma center. One year after the car accident, the patient had sustained a glenoid fracture (Ideberg type 5) on the right side, which was treated surgically using locking plate fixation.



**Fig. 1.** 3D CT-reconstruction of the pelvic brim (a) with subtraction of the right femur shows the right-sided acetabular fracture 6.2-B3 (b, red lines) according to the AO-Foundation. The fracture line runs along the posterior iliac wing (a, c). (For interpretation of the references to color in this figure legend, the reader is referred to the web version of this article.)



**Fig. 2.** Intraoperative pictures showing the initial reposition (a), reaming and stabilization of the upper pubic bone by the implementation of the PBS (Illuminos®) (b-d; e) during the curing process activated by the light source (f).



**Fig. 3.** a) Pelvic a.p. (X-ray) showing right medial femur neck fracture (Garden IV) and acetabular fracture (AO.62-B3) 6 month postoperatively. b) Postoperative axial right hip (X-ray) showing the DHS with supplemented PBS (see the red area). (For interpretation of the references to color in this figure legend, the reader is referred to the web version of this article.)

After initial diagnostic workup in the emergency department and exclusion of further injuries, the patient was immediately taken to the operation theater to treat the medial femoral neck fracture. Based on the patient's age, immediate surgical treatment using a dynamic fixation was chosen to preserve the femoral head. The affected femur exhibited a proximal bowing deformity. This specific anatomical situation impeded the implantation of a rigid standard intramedullary device. Thus, the surgical treatment was substantially hindered by the known poor bone quality as well as the abnormal anatomy. Therefore, the decision was made to combine an extramedullary device (dynamic hip screw (DHS)) with a PBS (e.g. IlluminOss®) system to increase the bone stability and to improve the anchorage of this device. The IlluminOss® catheter (9 mm × 160 mm) was inserted via a lateral approach proximal to the greater trochanter, the DHS was fixed through the IlluminOss®-augmented femur. The patient recovered very well after the fixation of the femoral neck fracture. The surgical treatment of the acetabular fracture could be performed 10 days later. Primarily, the fracture of the iliac bone was addressed through the first window of an ilio-inguinal approach. After achieving an anatomical fracture reduction, a locking plate (4-hole reconstruction plate) was used to fix the iliac wing. In a second step, the acetabular fracture was exposed via a “Stoppa” approach. To achieve a proper stabilization of the altered bone substance, an IlluminOss® bone catheter (9 mm × 160 mm) was inserted in the upper pubic bone (see Fig. 2). Subsequently, internal fixation of the acetabular fracture was performed using an 11-hole reconstruction plate. The screws were placed through the augmented bone, which resulted in a firm anchorage of the screws.

The patient recovered very well and active-assisted movement of the hip and the knee joint were performed from the 2nd postoperative day on. Range of motion of the hip increased each day, whereas the pain was decreasing constantly after surgery. The initial patient-controlled intravenous analgesia was terminated after two days and switched to oral analgesia (Targin hydrochlorid 10 mg 1-0-1, NSAID (i.e. Ibuprofen 400 mg 1-1-1). The post-operative X-ray control showed an anatomic restoration of the acetabular joint line as well as of the proximal femur (see Fig. 3). No postoperative complications occurred so that the patient was discharged 7 days after the acetabular surgery. The outpatient rehabilitation program included active-assisted exercises. Half body weight-bearing (around 25–30 kg) of the right lower extremity was set for the following 6 weeks. After 12 weeks, the patient showed a good overall rehabilitation with full weight-bearing and physical range of motion of the hip joint (HHS 90) (see Fig. 4). He presented 14 months later in our outpatient clinic without complications and a full recovery.

## Discussion

For the first time, we present an alternative management of fracture fixation using advanced augmentation of poor bone substance by a photodynamic bone stabilization system (PBS) for consecutive internal stabilization of a medial femoral neck (Garden type IV, Pauwels type III) and acetabular fracture (AO-Type 62-B.3) in OI patients. The concept of PBS for reinforcing bone strength by internal augmentation was already postulated in the early 1990s [4]. This system mainly consists of three major parts including a de- and inflatable catheter shaft (PET balloon), a light sensitive liquid monomer and a light-conducting fiber [5]. Basically, the balloon is inserted intramedullary above the fracture line after manual reposition and infused with the light-sensitive monomer. The curing process of the monomer is then activated by a specific light source. The application of the PBS delivers an exact and individually customized fixation tool based on the internal aligning to the corrected anatomy. Its applicability and efficacy in the current literature is well elaborated (e.g. Illuminoss®) [6,7].

In the current literature, the PBS was used in pathological and osteoporotic fractures including long bones [6]. In contrast to PMMA, PBS shows decreased “thermal excursion and curing time”, which favors the use in older patients presenting with further



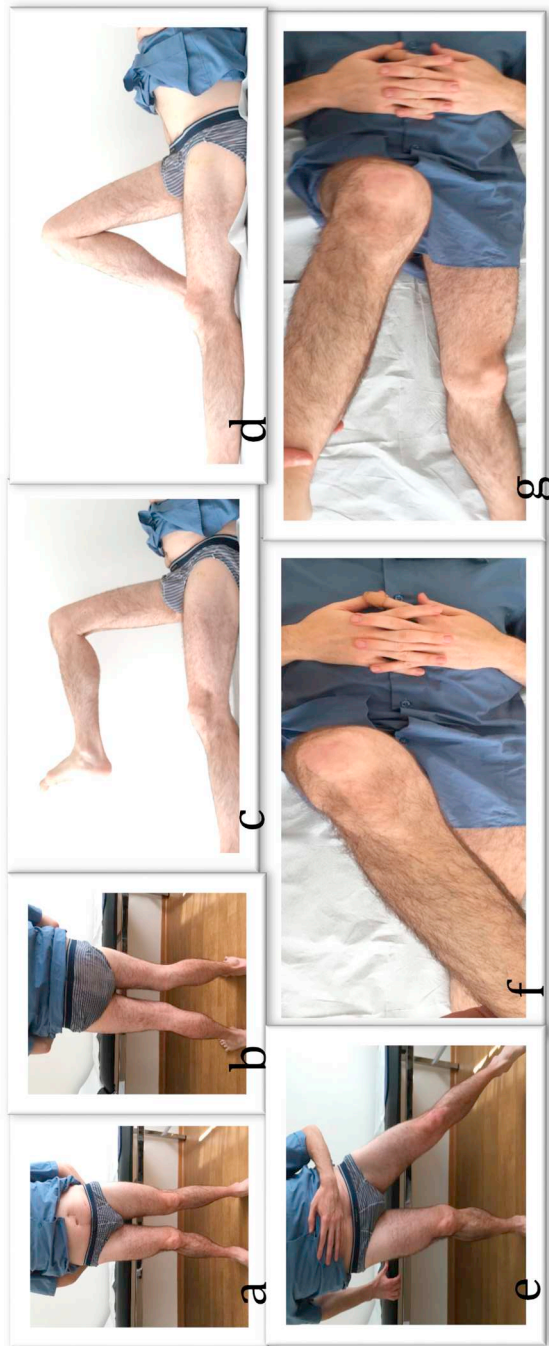


Fig. 4. Standing position is possible and weight bearing on the affected side (a, b, e). Showing the range of motion (RoM) of the hip joint around 12 weeks postoperatively (f, g). Active flexion of the hip joint was possible  $> 90^\circ$  (c, d). The patient was only suffering from discomfort of the adductor muscles.

comorbidities. Vegt et al. postulate the ease of implementation (minimally-invasive) and the stable reconstruction [6,7]. They reported excellent results of PBS in osteoporotic long bone fractures of the humerus, femur, fibula and distal radius/ulna [6].

The general use of this system in fracture fixation is not prevalent in the current research. However, from our perspective the PBS delivers a good to excellent internal augmentation or single fixation tool in distinct indications (e.g. > 80 years of age with distal fibular fracture and critical soft tissues/pelvic fracture (Type AO-61.A–B)). Especially after the curing process, the monomer remains drillable, which emphasizes the properties for additional augmentation and internal fixation.

Regarding our case, surgical treatment of OI patients is exceptionally challenging since their bone structure is more fragile and the perioperative risk is increased for lengthy surgery (e.g. intraoperative bleeding [8]). The presented case emphasizes the benefits of a combined use of reinforcing bone system and standard plate fixation. In detail, we used the application of the PBS in contrast to other augmentation systems like bone cement, bone glass, autogenous or allogeneic bone grafts.

From our point of view, the PBS provides three main benefits in this special case of OI: (1) the balloon catheter, which offers exact placement of the intramedullary bone support without cement extravasation, (2) the additional internal plate fixation through the bone support and (3) the temporary stabilization by the PBS simplifying the following plate fixation. Therefore, in individuals affected with OI, the challenging anchorage of screws in the fragile bone was overcome by the PBS. Thus, in the early postoperative phase, a weight-bearing physical therapy program was possible and successively realized due to the additional internal augmentation.

## Conclusion

Osteogenesis imperfecta is a rare systemic connective tissue disorder leading to an increased bone fragility due to minor bone density. Fractures occur statistically more often and mostly need an advanced (OI-adapted) surgical treatment. We recommend to combine PBS with internal fixation techniques for fracture reconstruction in these cases. However, long-term outcome following this relatively new treatment is lacking. Nevertheless, the excellent short-term follow-up results are promising.

## References

- [1] F. Rauch, F.H. Glorieux, Osteogenesis imperfecta, *Lancet* 363 (9418) (2004) 1377–1385.
- [2] D. Silience, A. Senn, D. Danks, Genetic heterogeneity in osteogenesis imperfecta, *J. Med. Genet.* 16 (2) (1979) 101–116.
- [3] F.H. Glorieux, et al., Cyclic administration of pamidronate in children with severe osteogenesis imperfecta, *N. Engl. J. Med.* 339 (14) (1998) 947–952.
- [4] S.B. Poddar, Inflatable Bone Fixation Device, Google Patents, 1992.
- [5] R.A. Rabiner, D.P. Collieran, J.G. Dye, Photodynamic Bone Stabilization Systems and Methods for Treating Spine Conditions, Google Patents, 2010.
- [6] P. Vegt, J.M. Muir, J.E. Block, The photodynamic bone stabilization system: a minimally invasive, percutaneous intramedullary polymeric osteosynthesis for simple and complex long bone fractures, *Med. Devices* 7 (2014) 453.
- [7] I. Golub, et al., Lightfix: a prospective, multi-center study of the photodynamic bone stabilization system for the treatment of impending and actual pathological fractures from metastatic bone disease in the humerus, *J. Am. Coll. Surg.* 223 (4) (2016) e27.
- [8] M.T. Keegan, B.D. Whatcott, B.A. Harrison, Osteogenesis imperfecta, perioperative bleeding, and desmopressin, *Anesthesiology* 97 (4) (2002) 1011–1013.