

Brief Report

Echogenic mass in the right atrium after surgical ventricular septal defect closure: thrombus or tumour?

Nicole de Winkel,¹ Karen Becker,² Manfred Vogt¹

Departments of ¹Pediatric Cardiology and Congenital Heart Disease, and ²Pathology and Pathologic Anatomy, German Heart Centre Munich, Technische Universität München, Munich, Germany

Abstract We describe a neonate who presented with an echogenic mass in the right atrium 8 weeks after closure of ventricular and atrial septal defects. On a routine post operative check up after discharge, a mass was detected in the right atrium on echocardiography. As a thrombotic formation was suggested, lysis was started, in combination with the administration of unfractionated heparin. As there was no change in echogenicity or size of the mass, it was surgically excised. Histopathological examination revealed a myofibroblastic inflammatory tumour.

Keywords: Cardiac tumour; myofibroblastic inflammatory tumour; intracardiac lesions

Received: 21 January 2009; Accepted: 14 June 2009; First published online 13 January 2010

THE PREVALENCE OF PRIMARY CARDIAC TUMOURS in childhood is low. Histologically, most of them are rhabdomyomas. Myofibroblastic inflammatory tumours are rare entities in infancy. Initially, they were recognized in the lung, but are now known to occur in virtually every major organ of the body. The precise biological nature and the clinical characteristics of these kinds of lesions are still uncertain. They can occur at any age, but are referred to as soft tissue tumours of childhood.¹

The rarity of myofibroblastic inflammatory tumours in the heart poses a diagnostic difficulty for both paediatricians and pathologists because of the clinical and morphological overlap with other intracardiac masses.²

Case report

A neonate was originally admitted to our hospital at the age of 6 weeks because of haemodynamically relevant ventricular and atrial septal defects. His mother had had a history of 3 stillbirths, as well as

1 missed abortion. The current pregnancy had been the product of in-vitro fertilization, complicated by premature labour, and a ventricular septal defect that had already been suspected on fetal scans. The family history did not show any birth defects, especially no history of malignant tumours. Coagulation testing in the mother, as well as in the patient, failed to show any abnormalities. Because of progressive congestive cardiac failure, despite anti-congestive treatment, surgery was performed when the baby was aged 8 weeks. After an uneventful post-operative course, the patient developed a mass in the right atrium, measuring 2 by 1.4 centimetres (Fig. 1), which was detected echocardiographically 8 weeks later. Until then the patient had been asymptomatic.

Because of the closeness to the superior caval vein, and a relatively broad base on the atrial septum, we initially suspected formation of thrombus. On this account, the patient was put on unfractionated heparin, with a target partial thromboplastin time of 60 to 70 seconds. Lysis with recombinant tissue plasminogen activator was also initiated. As there was no change of the echocardiographic findings within 7 days, we decided to remove the mass surgically. Intraoperatively, the formation was still suggestive of thrombus. It could

Correspondence to: Dr Nicole de Winkel, Department of Pediatric Cardiology and Congenital Heart Disease, Technische Universität München, German Heart Centre Munich, Lazarettstraße 36, 80636 München, Germany. Tel: 00 49 8912183305; Fax: 00 49 8912183333; E-mail: dewinkel@dhm.mhn.de

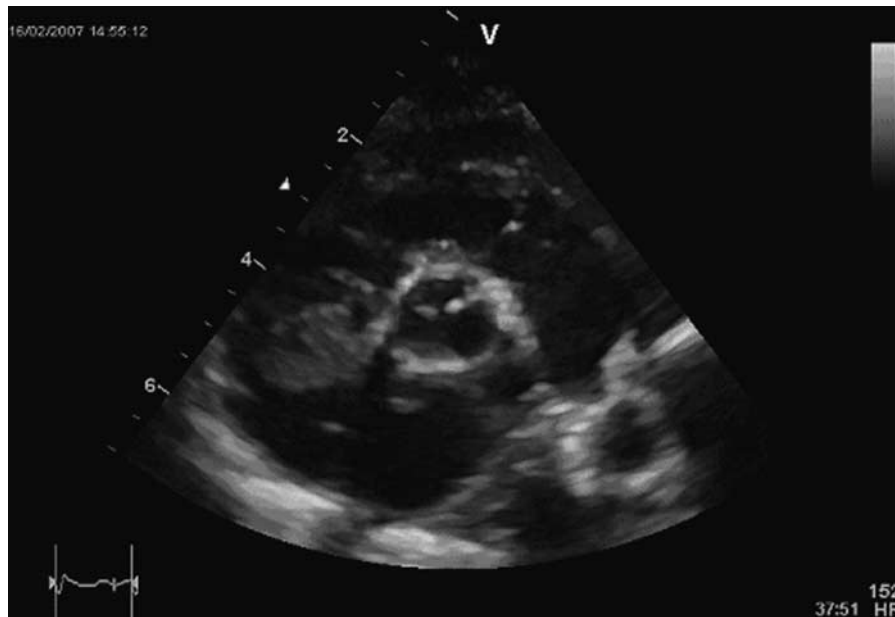


Figure 1.

The transthoracic short-axis view shows an inhomogeneous echogenic mass adherent to the right atrial wall 8 weeks after surgical closure of ventricular and atrial septal defects.

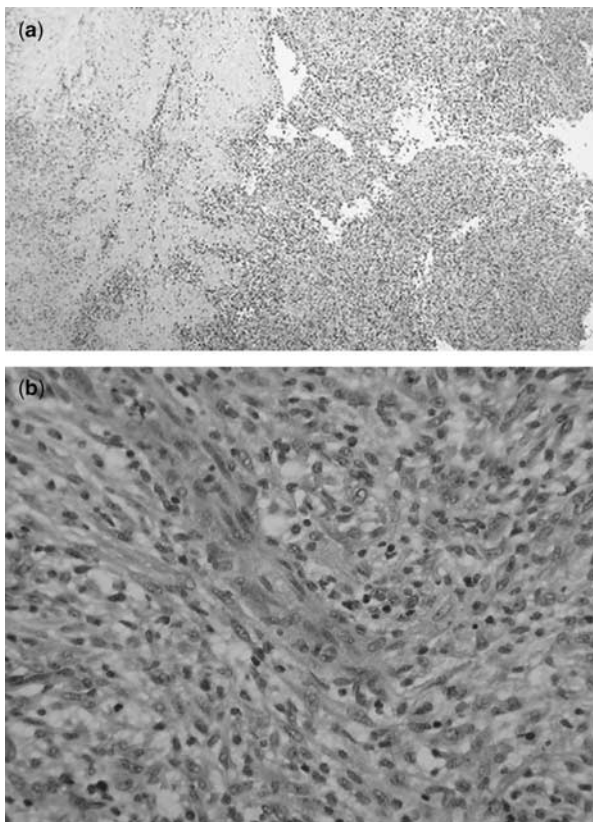


Figure 2.

Microscopic sectioning of the tumour shows its inhomogeneous, fissured, surface (a); and the spindle shaped tumour and muscle cells with inflammatory reaction (b).

be excised almost in its entirety with a sharp spoon. A few days later, the surprising diagnosis of a myofibroblastic inflammatory tumour was established on the basis of the histopathological findings (Fig. 2).

As in this low grade lesion metastatic invasion is very rare, we decided to dispense with staging, although a complete resection due to the broad infiltration had not been possible. Additional chemotherapy or radiotherapy seemed not to be indicated because of the known low malignancy of the tumour. In order to avoid a thrombotic aggregation at the site of the excision, we put the patient on coumadin for the first 3 month after the operation. Detailed echocardiographic follow-up for 18 months has revealed no signs of a local relapse of the tumour. Clinically, the patient has been stable since the operation.

Discussion

Newly recognised echogenic masses within the heart after a cardiac operation are most often related to formation of thrombus.² Cardiac tumours in general are rare in children, with the majority of cases detected in infancy being rhabdomyomas. The inflammatory myofibroblastic tumour was initially described in the lung in 1939. Biologically, it is classified as a low grade spindle cell lesion presenting with only mild dysplasia. Since its

first description, there have been reports of such tumours in almost all organ systems, including the heart.³ In virtually all of them, the tumour originated from the right atrium. Only a minority of the patients have been asymptomatic. The majority showed signs of cardiac disease, such as coronary ischaemia due to involvement of the coronary arteries, as well as dyspnoea, cyanosis, or pericardial effusion.

Although inflammatory myofibroblastic tumours are described as being low grade lesions, with a low potential for invasive growth, a slight risk remains for penetration of neighbouring structures, such as

coronary arteries or valves. In our patient, the tumour could be excised almost in total, and the patient has since been well.

References

1. Sebire NJ, Ramsay A, Sheppard M, Malone M, Harding B, Risdon RA. Intravascular inflammatory myofibroblastic tumors in infancy. *Pediatr Dev Pathol* 2002; 5: 400–404.
2. Li L, Cerilli LA, Wick MR. Inflammatory pseudotumor (myofibroblastic tumor) of the heart. *Ann Diagn Pathol* 2002; 6: 116–121.
3. Murdison KA, Septimus S, Garola RE, Pizarro C. Intracardiac inflammatory myofibroblastic tumor: a unique presentation. *Eur J Cardiothorac Surg* 2007; 31: 750–752.