

# Surgical Morphology of the Pancreatic Isthmus

Stanisław A. Hac<sup>a</sup> Marek Dobosz<sup>b</sup> Adam Nalecz<sup>c</sup> Jacek Reszetow<sup>a</sup>  
Sebastian Dobrowolski<sup>a</sup> Helmut Friess<sup>e</sup> Andre L. Michaljevic<sup>e</sup>  
Pawel Mroczkowski<sup>f</sup> Michal Studniarek<sup>d</sup> Zbigniew Sledzinski<sup>a</sup>

<sup>a</sup>Department of General Endocrine and Transplant Surgery, Medical University of Gdansk, <sup>b</sup>Department of General Surgery, Gdansk Municipal Hospital, Division of Nursing, and Departments of <sup>c</sup>Pathomorphology and <sup>d</sup>Radiology and Nuclear Medicine, Medical University of Gdansk, Poland; <sup>e</sup>Department of Surgery, Klinikum rechts der Isar, Technische Universität München, Munich and <sup>f</sup>Department of Surgery, Klinik für Allgemein-, Viszeral- und Gefäßchirurgie, Universitätsklinikum, Magdeburg, Germany

## Key Words

Anatomy · Pancreatic ducts · Pancreatoduodenectomy

## Abstract

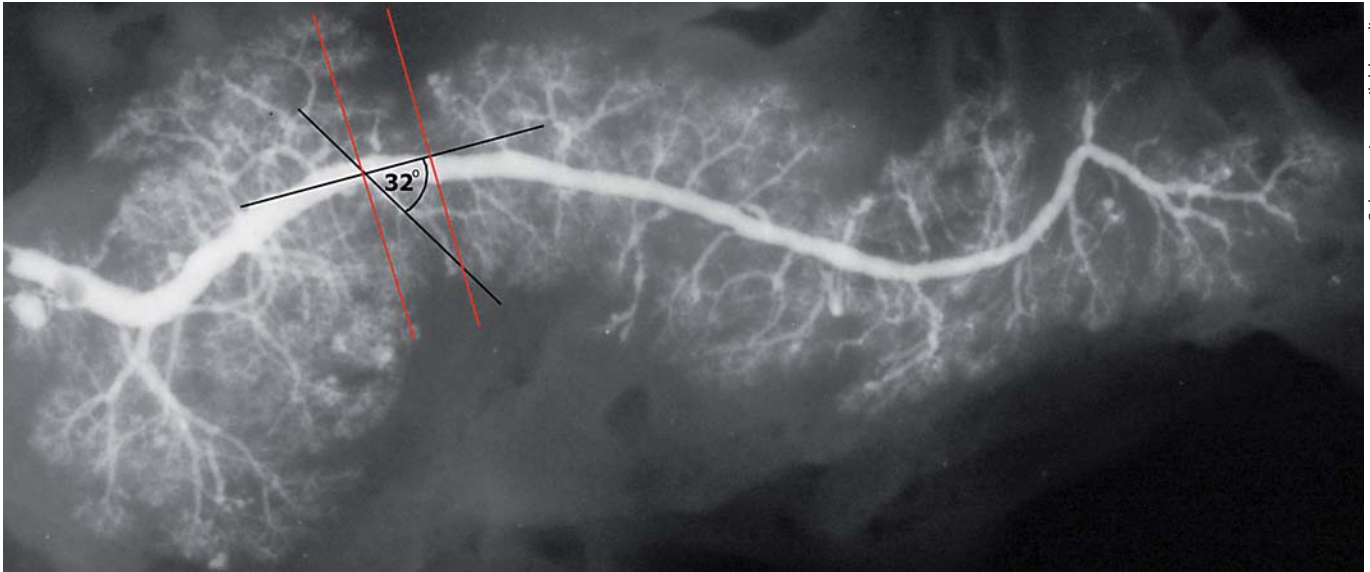
**Background:** Pancreatic isthmus method anastomosis following pancreatic resection is an important factor of post-operative fistula formation. While the anatomy and vascular supply of the pancreatic head have been studied in detail, little is known about the morphology of the pancreatic isthmus. The authors determine the anatomy and morphology of the pancreatic isthmus. **Methods:** 99 consecutive cadaveric pancreatic specimens were taken during standard autopsy. Organs were transected at the isthmus and pancreatograms and microscopic specimens of the transection plane were analyzed. **Results:** The mean size of the Wirsung duct at the isthmus was 2.89 mm ( $\pm 0.87$  mm, from 1.4 to 6 mm). The main pancreatic duct was located approximately in the middle of the pancreatic cross-section plane in almost all specimens. The total number of second-degree pancreatic ducts visible on pancreatograms within the isthmus was 1.77 ( $\pm 1.00$ , from 0 to 4) and 1.83 ( $\pm 1.4$ , from 0 to 5) on microscopic analysis. **Conclusions:** The presence of second-

degree pancreatic ducts at the transection site might favor the use of a pancreatocentric anastomosis with stump invagination to reduce the risk of anastomotic leakage.

Copyright © 2010 S. Karger AG, Basel and IAP

## Introduction

Pancreatoduodenectomy (PD) has become the standard treatment for various benign and malignant diseases of the pancreatic head, periampullary region and distal biliary tree. Pancreatic resection requires gland cross section followed by pancreatocentric anastomosis [1]. Frequently the pancreas is transected at the isthmus or close to it. There are numerous ways for pancreatic stump anastomosis [1], however, most frequently the pancreas is either anastomosed to the jejunum (pancreaticojejunostomy) or to the stomach (pancreaticogastrostomy). The pancreatoenteral anastomosis is performed in two modifications: (a) full-thickness anastomosis with pancreatic stump invagination or (b) selective, round duct to mucosa end-to-side anastomosis with or without temporary external drainage of the Wirsung duct [1–3]. The type of



**Fig. 1.** Pancreatogram obtained after barium-sulfate injection into the pancreatic duct after pancreatic removal. The angle between the main pancreatic duct and second-degree ducts is pointed out with black lines. Grey lines (red in the online version) indicate pancreatic isthmus segment.

pancreatic anastomosis that yields the best results, i.e. lowest complication rate, is still under debate and so far no consensus has been achieved [1, 2]. Although pancreatic anatomy has been studied extensively by anatomists and surgeons over the last decades and pancreatologists have gained insight into the vascular supply as well as the anatomy and morphology of the pancreatic head, our knowledge of the pancreatic isthmus region remains woefully underdeveloped [4–8]. The aim of this study was to analyze pancreatic isthmus anatomy and morphology, especially in relation to the presence of second-degree pancreatic ducts, a feature important for surgical anastomosis.


## Material and Methods

The study was approved by the local ethics committee at the University of Gdansk, Poland (No. NKEBN/191/2004). The study was performed on 99 consecutive fresh cadavers. The mean age of patients was  $66.9 \pm 12.1$  years. There were 61 males and 38 females, all without any detectable pancreatic pathology or history of pancreatic illnesses. On autopsy the pancreas with duodenum, portal and superior mesenteric vessels and hepatoduodenal ligament was gently removed ‘en bloc’. The pancreatic duct was identified and cannulated via the papilla of Vater with an 18-gauge needle (Dekta VEN2) held in place by a purse-string stitch. Consequently the pancreatic duct was filled with 2.5–3.5 ml of barium-sulfate solution (depending on the size of the gland) (fig. 1).

Pancreatograms were performed at a right angle, on plain  $24 \times 30$  cm radiographic films with green film screen. Exposure was set at 2.8 mAs and 43 kV. The superior mesenteric vein was identified on pancreatograms by a metal marker. Pancreatograms were categorized by three experienced blinded experts according to the classification proposed by Cubilla and Fitzgerald [9] (fig. 2). The pancreatic isthmus was defined as the part of the gland directly above the axis of the superior mesenteric vein. All specimens were fixed in buffered formalin. In a next step, cross sections of the pancreatic isthmus were performed. Slices were treated with standard hematoxylin and eosin staining evaluated by light microscopy at  $40\times$  magnification by an experienced pathologist for presence, number and distribution of second-degree pancreatic ducts as well as Wirsung duct size and localization. All identified pancreatic ducts were positioned according to the pancreatic cross-section ellipse model [10]. Pancreatograms were digitalized (using Snap-Scan 1236, Agfa, China). The isthmus was identified after fourfold magnification of digital pancreatograms. The isthmus segment was defined as 0.5 cm distal and 0.5 cm proximal to the isthmus axis. The number of second-degree pancreatic ducts as well as the angle between the main duct and side branches were analyzed within the defined isthmus segment.

## Statistics

Pancreatic duct type and distribution were classified by three blinded pancreatologists according to the classification proposed by Bang et al. [11]. Results underwent Cohen’s  $\kappa$  test (correlation/reliability) between categorization pairs of the same individual. Each rater classified each sample into 1 of 19 categories. Rules-of-thumb for  $\kappa$  values  $<0.40$  indicate a low association, values between 0.40 and 0.75 indicate a medium association, and values  $>0.75$  indicate a high association between the two raters.



**Fig. 2.** Cubilla classification of pancreatic ductal system. In types A and B the Wirsung duct formed the main pancreatic duct, however, in type C the Wirsung duct did not form the main pancreatic duct. In type A the Santorini duct is either obliterated or absent. Santorini duct type B is an accessory pancreatic duct and runs into the minor papilla of the duodenum. If the pancreatic duct system did not fall into any of these three groups it was classified as type D.

The descriptive statistics reported are means, standard deviations, ranges, and 95% confidence intervals. A linear correlation model was applied in order to calculate and describe the data. Statistical evaluations were performed by the Statistica 7.1 Version (StatSoft, Inc., Tulsa, Okla., USA) packages on a personal computer.

## Results

Three blinded experts classified pancreatic duct configurations into type A (32–57 samples), type B (12–20 samples), type C (22–29 samples) or type D (0–5 samples). Three, 2 or 5 cases, respectively, remained unclassified.  $\kappa$  statistic revealed low association between the three pairs of experts (0.331, 0.324 and 0.370, respectively). Detailed frequency of pancreatic duct configuration is shown in table 1.

The mean thickness of the isthmus cross section was 10.32 mm ( $\pm 2.69$  mm, from 3.33 to 18.50 mm) and the mean height was 26.09 mm ( $\pm 4.62$  mm, from 17.27 to 40.00 mm). The mean size of the Wirsung duct within the isthmus was 2.89 mm ( $\pm 0.87$  mm, from 1.4 to 6 mm). Wirsung duct position coordinates (X;Y) within the transected isthmus were X = mean 44.03, SD  $\pm 12.4$ , min. 16.7, max. 77.5, and Y = mean 51.16, SD  $\pm 9.44$ , min. 31.6,

**Table 1.** Pancreatic duct configuration based on pancreatograms

Category	Expert					
	R1	R2	R3	R1, %	R2, %	R3, %
A1	24	6	22	24	6	23
A2	12	11	17	12	11	18
A3	0	0	1	0	0	1
A4	0	2	3	0	2	3
A5	2	1	3	2	1	3
A6	19	12	9	19	12	9
A 1–6	57	32	55	58	33	57
B1	13	18	4	13	18	4
B2	6	10	6	6	10	6
B3	1	1	1	1	1	1
B4	0	1	0	0	1	0
B5	0	2	1	0	2	1
B 1–5	20	32	12	20	33	13
C1	0	1	0	0	1	0
C2	1	4	7	1	4	7
C3	21	23	17	21	23	18
C4	0	1	5	0	1	5
C 1–4	22	29	29	22	30	30
D1	0	0	0	0	0	0
D2	0	3	0	0	3	0
D3	0	0	0	0	0	0
D4	0	2	0	0	2	0
D 1–4	0	5	0	0	5	0
Unclassified	2	3	5	2	3	5

Category column contains pancreatogram categories according to the classification proposed by Cubilla and Fitzgerald [9].

R1, R2 and R3 indicate the results of three blinded experts in pancreatology.

Results are presented as numbers and percentages.

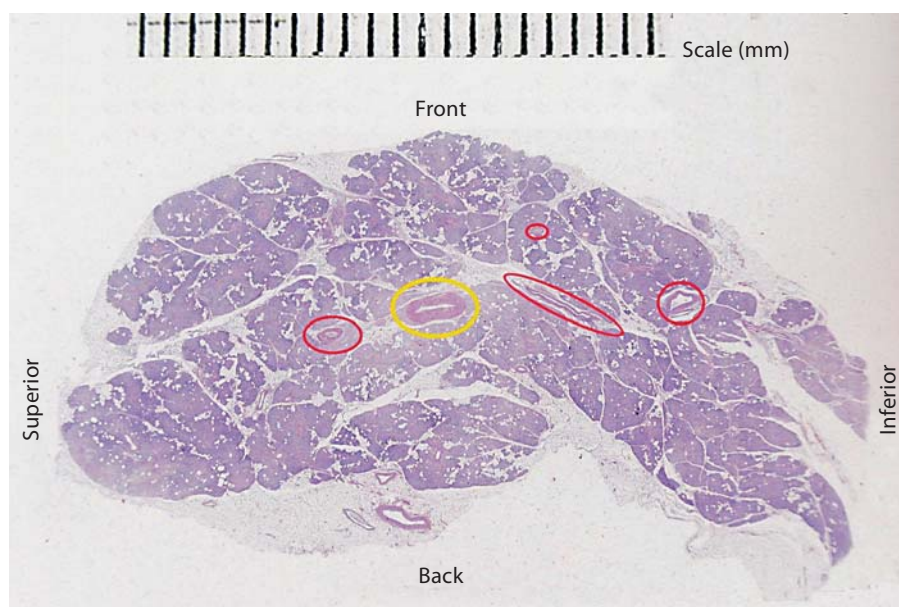
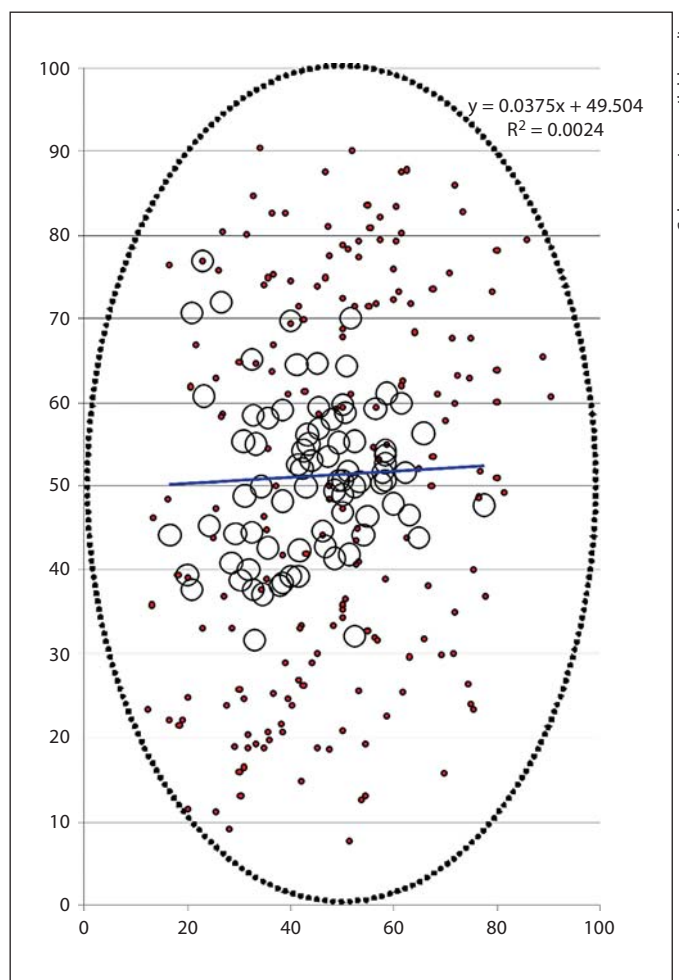
max. 76.9 (fig. 3). The total number of second-degree pancreatic ducts visible on pancreatograms within the isthmus segment (5 mm distal and 5 mm proximal from the isthmus axis) was 1.77 ( $\pm 1.0$ , from 0 to 4). The number of second-degree ducts visible on cross-section planes under the microscope was 1.83 ( $\pm 1.4$ , from 0 to 5) (fig. 4).

The angle between second-degree pancreatic ducts and the Wirsung duct within the isthmus segment was 79.11° ( $\pm 23.16^\circ$ , from 39.45 to 156.50°) (fig. 1). Second-degree pancreatic ducts were described with two coordinates. All results as well as patient characteristics are summarized in table 2.

**Table 2.** Patient characteristics and pancreatogram and isthmus cross-section parameters

Parameter	Mean value ± SD	Min–Max
<i>Patient characteristics</i>		
Age, years	66.9 ± 12.1	31–97
Gender		
Male	61	
Female	38	
<i>Pancreatic isthmus morphology in light microscopy</i>		
Thickness, mm	10.32 ± 2.69	3.33–18.50
Height, mm	26.09 ± 4.62	17.27–40.00
Number of second-degree ducts	1.83 ± 1.4	0–5
<i>Pancreatic isthmus morphology on pancreatograms</i>		
Number of second-degree ducts within isthmus segment	1.77 ± 1.0	0–4
Angle between second-degree ducts and Wirsung duct, °	79.11 ± 23.16	39.45–156.50
Isthmus pancreatic duct diameter, mm	2.89 ± 0.88	1.4–6

**Fig. 3.** Schematic representation of Wirsung duct localization (large circles) and second-degree pancreatic ducts (grey spots; red in the online version) within the ellipse model of pancreatic isthmus transection plane. The Wirsung duct position regression line formula and R<sup>2</sup> coefficient are indicated. The interrupted ellipse symbolizes a pancreatic isthmus cross-section margin.



**Fig. 4.** A pancreatic isthmus cross-section after standard hematoxylin and eosin staining. The light grey ellipse (yellow in the online version) indicates the Wirsung duct, the dark grey figures (red in the online version) indicate transected second-degree pancreatic ducts.

## Discussion

The human pancreas is composed of two embryological primordia: the ventral and dorsal one. They contact each other around day 37 and consequently fuse with each other at the end of week 6 [12]. The junction usually lies within the head of the gland. Pancreatic duct variability is caused by differences in configuration and proportion of the two embryological parts [13]. The functional and topographic anatomy of pancreatic ducts within the pancreatic head and duodenal papilla has been studied in depth [13–17] and has influenced clinical management strategies [4, 18–20]. Surprisingly, however, studies concerning the anatomy and morphology of the isthmus and pancreatic corpus have been sparse. PD is a widely used surgical procedure in the treatment of benign and malignant diseases of the pancreatic head and periampullary region. During PD the pancreatic isthmus, i.e. the part of the gland situated above the venous confluence, is frequently used as a site of transection by surgeons due to its thinness. Our study focuses on elucidating the anatomic and morphological features of the pancreatic isthmus as a site for surgical transection [5, 11, 21].

Initially we analyzed the configuration of pancreatic ducts in the isthmus region. Ducts were classified by three blinded experts independently. We only found a low association between the results. Furthermore, the distribution of pancreatic duct configurations in our study was different from that reported previously [11, 22]. Interestingly, each pair of blinded expert showed a similar association for certain results, thus the power of their judgment is similar. The diversion of the results might therefore indicate insufficiency of categorization criteria in the model and might indicate the need for re-evaluation of the categorization system.

A number of technical variants of PD exist since it was first performed by Kauch almost a century ago [3, 6, 14, 23–25]. Most surgeons regard the pancreatoenteral anastomosis after PD as the ‘Achilles heel’ of the whole procedure [5, 6, 25, 26]. Anastomosis leakage is a serious complication following PD and determines the overall surgical outcome. Especially the rate of pancreatic fistula after PD is a common source of in-hospital morbidity with numbers ranging from 2.5 to even 28% [23, 27, 28].

A surgeon-independent factor influencing pancreatoenteral anastomosis leakage is the texture of the pancreas (soft vs. hard) [6, 24]. Anastomoses to normal pancreatic parenchyma (soft texture) show higher rates of postoperative pancreatic fistula (12–28%) compared to anasto-

moses to fibrotic tissue (hard texture, 5–9%) [3, 29, 30]. Another documented risk factor of anastomotic insufficiency is a small pancreatic duct [8].

Surgeon-dependent postoperative pancreatic fistula factors include the method of reconstruction. Numerous techniques have been described – pancreaticojejunostomy or pancreaticogastrostomy, end-to-end or end-to-side anastomosis, invagination or duct-to-mucosa anastomosis, the use of an isolated Roux-en-Y limb, continuous or interrupted sutures, single or double layer stitching, the use of fibrin glue and postoperative temporal pancreatic duct stenting [3, 5, 26, 31, 32]. The departmental as well as individual experience in pancreatic surgery is another well-documented factor influencing outcome. High-volume centers (at least 25 operations performed annually) have significantly fewer postoperative complications and lower mortality rates than low-volume centers. Furthermore, several authors have shown that the duration of preoperative jaundice, intraoperative blood loss, operative time and preoperative creatinine clearance are significant risk factors for postoperative pancreatic fistulas [8, 11].

We analyzed the pancreatic isthmus segment as the usual place of pancreatocenteric anastomosis after PD with regard to the presence of second-degree pancreatic ducts. Pancreatograms showed a variable number and angulation of second-degree pancreatic ducts within the pancreatic isthmus. The angle between the main duct and its branches indicate the probability of second-degree duct transection during pancreatic resection. Furthermore, we found differences in number, size and location of second-degree pancreatic ducts at the cross-section plane between specimens (fig. 4; table 2). The present study confirms the presence of second-degree pancreatic ducts at the pancreatic isthmus on pancreatograms as well as in the microscopic analysis of tissue cross sections. We found a robust association between the two analysis methods.

Second-degree pancreatic ducts opened during isthmus transection secrete pancreatic juice and might thus account for postoperative pancreatic fistulas if left undrained. Furthermore, if these ducts are occluded during the placement of the anastomosis, postoperative pancreatitis in the pancreatic remnant might occur which can also contribute to pancreatic fistula formation or anastomotic leakage.

The reliable risk factor of postoperative pancreatic fistula is soft pancreas [6]. The discussion of anastomosis technique priority is focused around the partner for pancreatic stump – the jejunum or stomach. Randomized

controlled data did not indicate one of them being more efficient than the other [6]. Duct-to-mucosa pancreaticoenteral anastomosis definition and details vary considerably. For example, Watanabe et al. [8] and Bassi et al. [1] described a circumferential end-to-side duct-to-mucosa technique, the same name given by the Bern group [26], who, however, performed a combination of the duct-to-mucosa and dunking method. Duct-to-mucosa pancreaticoenteral anastomosis is not more prone to postoperative pancreatic fistula (from 2 to 11.8%) [6, 8] when compared to the dunking technique (from 3 to 15.6%) [8]. Bassi et al. [1] reported the RCT duct-to-mucosa versus dunking method of pancreaticoenteral anastomosis. Fistulas occur in 13% of the duct-to-mucosa group and in 15% of the dunking group, respectively. These reports with a variance of high results suggest differences in technique, definitions and the criteria used. Our finding explains why pancreaticoenteral anastomosis with round (circumferential) pancreatic duct stitching and coverage of the pancreatic transection plane with the jejunal muscular layer might not guarantee adequate drainage of the pancreatic remnant, since second-degree pancreatic ducts are left out of the anastomosis. The morphological feature described in this work is not the panacea for safe pancreaticoenteral anastomosis, but should be considered as an important factor. It therefore seems reasonable to apply anastomotic techniques that circumvent this problem, like invagination of the pancreatic stump into

the digestive tract during pancreaticoenteral anastomosis [26] or application of selective not-round pancreatic duct stitching. Moreover, left pancreatic resection results in the mirror picture of the pancreatic isthmus transection plane. The technique of pancreatic stump closure should consider the main duct stitching and second-degree duct management in the cut-line plane by precise suturing up. Several patients have large or aberrant second-degree ducts within the pancreatic body and tail [33]. These ducts might be of clinical importance in case of extended PD or pancreatic tail resection.

## Conclusions

The abundance of second-degree pancreatic ducts within the pancreatic isthmus region found in our study might account for the high rates of pancreatic fistulas found after pancreatic resection procedures and supports the application of surgical techniques that include second-degree pancreatic ducts at the site of transection into the anastomosis.

## Acknowledgments

We would like to thank Mr. Leszek Moroń for his help and kindness. This work was supported with Medical University of Gdansk Grant W-34.

## References

- Bassi C, Falconi M, Molinari E, Mantovani W, Butturini G, Gumbs AA, Salvia R, Pederzoli P: Duct-to-mucosa versus end-to-side pancreaticojejunostomy reconstruction after pancreaticoduodenectomy: result of a prospective randomized trial. *Surgery* 2003; 134:766–771.
- Konishi M, Ryu M, Kinoshita T, Inoue K: Pathophysiology after pylorus-preserving pancreatoduodenectomy: a comparative study of pancreaticogastrostomy and pancreaticojejunostomy. *Hepatogastroenterology* 1999;46:1181–1186.
- Yamaguchi H, Yamada Y, Kakizaki K: Pancreatic division by electrocautery in pancreatoduodenectomy. *J Hepatobiliary Pancreat Surg* 1999;1:86–89.
- Kamisawa T, Yoshiike M, Egawa N, Ishiwata J, Okamoto A: Patency of the accessory pancreatic duct evaluated by dye-injection endoscopic retrograde pancreatography: methods and clinical implication. *Dig Endosc* 2004;16:272–276.
- Strasberg SM, McNeven MS: Results of a technique of pancreaticogastrostomy that optimizes blood supply to the pancreas. *J Am Coll Surg* 1998;187:591–596.
- Shinchi H, Takao S, Maemura K, Aikou T: A new technique for pancreaticogastrostomy for the soft pancreas: the transfixing suture method. *J Hepatobiliary Pancreat Surg* 2006; 13:212–217.
- Rao AC, Gabriel G, Serrano J, Benedicto R: Inkwell pancreaticojejunal anastomosis after pancreatoduodenectomy. *Am J Surg* 2004;187:410–412.
- Watanabe M, Usui S, Kajiwara H, Nakamura M, Sumiyama Y, Takada T, Nagakawa T: Current pancreaticogastrointestinal anastomotic methods: result of Japanese survey of 3,109 patients. *J Hepatobiliary Pancreat Surg* 2004;11:25–33.
- Cubilla AL, Fitzgerald PJ: Gross anatomy; in Cubilla AL, Fitzgerald PJ (eds): *Tumors of the Exocrine Pancreas*, series 2, fasc. 19. Washington, Armed Forces Institute of Pathology, 1984, pp 31–52.
- Hac S, Nalecz A, Dobosz M, Radziszewski K, Reszetow J, Jaskiewicz K, Sledzinski Z: Pancreatic cross-section – an elliptical model. *JOP* 2007;8:186–190.
- Bang S, Suh JH, Park BK, Park SW, Song SY, Chung JB: The relationship of anatomic variation of pancreatic ductal system and pancreaticobiliary diseases. *Yonsei Med J* 2006;47: 243–248.
- Kamisawa T, Koine M, Okamoto A: Embryology of the pancreatic duct system. *Digestion* 1999;60:161–165.
- Li L, Yamataka A, Wang YX, Wang DY, Wang K, Li ZX, Shimizu T, Yamashiro Y, Zhang JZ, Lane GJ, Miyano T: Anomalous pancreatic duct anatomy, ectopic distal location of the papilla of Vater and congenital biliary dilatation: a new developmental triad? *Pediatr Surg Int* 2003;19:180–185.
- Kausch W: Das Carcinom der Papilla duodeni und seine radikale Entfernung. *Beitr Klin Chir* 1912;78:439–486.

- 15 Yoshihiro S, Motoki N, Nobutaka T, Nobori M, Tsukamoto T, Nokubi M, Suzuki Y, Makauuchi M: Anatomical segmentectomy of the head of the pancreas along the embryological fusion plane: a feasible procedure? *Surgery* 2000;128:822–831.
- 16 Uchida T, Takada T, Ammori BJ, Suda K, Takahashi T: Three-dimensional reconstruction of the ventral and dorsal pancreas: a new insight into anatomy and embryonic development. *J Hepatobiliary Pancreat Surg* 1999;6:176–180.
- 17 Chumpon W, Paisal P: Pancreaticobiliary ductal anatomy in Thai people. *J Hepatobiliary Pancreat Surg* 1999;1:79–85.
- 18 Kimura W: Surgical anatomy of pancreas for limited resection. *J Hepatobiliary Pancreat Surg* 2000;7:473–479.
- 19 Cano DA, Hebrok M, Zenker M: Pancreatic development and disease. *Gastroenterology* 2007;132:745–762.
- 20 Matsusue S, Takeda H, Nakamura Y, Nishimura S, Kozumi S: A prospective analysis of the factors influencing pancreaticojejunostomy performed using a single method, In 100 consecutive pancreaticoduodenectomies. *Surg Today* 1998;28:719–726.
- 21 Hyodo M, Nagai H: Pancreatogastrostomy after pancreatoduodenectomy with or without duct-to-mucosa anastomosis for the small pancreatic duct: short- and long-term results. *Hepatogastroenterology* 2000;47:1138–1141.
- 22 Nakao A, Fujii T, Sugimoto H, Kaneko T, Takeda S, Inoue S, Nomoto S, Kanazumi N: Is pancreatogastrostomy safer than pancreaticojejunostomy? *J Hepatobiliary Pancreat Surg* 2006;13:202–206.
- 23 Ohwada S, Ogawa T, Kawate S, Tanahashi Y, Iwazaki S, Tomizawa N, Yamada T, Ohya T, Morishita Y: Results of duct-to-mucosa pancreaticojejunostomy for pancreaticoduodenectomy Billroth I type reconstruction in 100 consecutive patients. *J Am Coll Surg* 2001;193:29–35.
- 24 Bassi C, Falconi M, Molinari E, Salvia R, Butturini G, Sartori N, Mantovani W, Pederzoli P: Reconstruction by pancreaticojejunostomy versus pancreaticogastrostomy following pancreatotomy. Results of a comparative study. *Ann Surg* 2005;242:767–773.
- 25 Greene BS, Loubeau JM, Peoples JB, Elliot DW: Are pancreatoenteric anastomoses improved by duct-to-mucosa sutures? *Am J Surg* 1991;161:45–49.
- 26 Z'Graggen K, Uhl W, Friess H, Büchler MW: How to do a safe pancreatic anastomosis. *J Hepatobiliary Pancreat Surg* 2002;9:733–737.
- 27 Yeo CJ, Cameron JL, Sohn TA, Lillemoe KD, Pitt HA, Talamini MA, Hruban RH, Ord SE, Sauter PK, Coleman J, Zahurak ML, Grochow LB, Abrams RA: Six hundred fifty consecutive pancreaticoduodenectomies in the 1990s: pathology, complications, and outcomes. *Ann Surg* 1997;226:248–260.
- 28 Wente MN, Shrikhande S, Muller MW, Diener MK, Seiler CM, Friess H, Büchler MW: Pancreaticojejunostomy versus pancreaticogastrostomy: systematic review and meta-analysis. *Am J Surg* 2007;193:171–183.
- 29 Bartoli FG, Armone GB, Ravera G, Bachi V: Pancreatic fistula and relative mortality in malignant disease after pancreaticoduodenectomy. Review and statistical meta-analysis regarding 15 years of literature. *Anticancer Res* 1991;11:1831–1848.
- 30 Duffas JP, Suc B, Msika S, Fourtanier G, Muscari F, Hay JM: A controlled randomized multicenter trial of pancreatogastrostomy or pancreaticojejunostomy after pancreatoduodenectomy. *Am J Surg* 2005;189:720–729.
- 31 Ohwada S, Iwazaki S, Nakamura S, Ogawa T, Tanahashi Y, Ikeya T, Iino Y, Morishita Y: Pancreaticojejunostomy-securing technique: duct-to-mucosa anastomosis by continuous running suture and parachuting using monofilament absorbable thread. *J Am Coll Surg* 1997;185:202–206.
- 32 Suzuki Y, Fujino Y, Ku Y, Tanioka Y, Ajiki T, Kamigaki T, Tominaga M, Takeyama Y, Kuroda Y: New pancreatic duct-invasion anastomosis using ultrasonic dissection for nonfibrotic pancreas with a nondilated duct. *World J Surg* 2002;26:162–165.
- 33 Hac S, Nalecz A, Dobosz M, Reszetow J, Dobrowolski S, Friess H, Mihaljevic AL, Studniarek M, Jaskiewicz K, Sledzinski Z: Pancreatic duct diversity. *Pancreas* 2009;38:318–321.