

Fetal Spina Bifida Repair – Current Trends and Prospects of Intrauterine Neurosurgery

M.A. Fichter^a U. Dornseifer^b J. Henke^c K.T.M. Schneider^d L. Kovacs^a
E. Biemer^a J. Bruner^e N.S. Adzick^f M.R. Harrison^g N.A. Papadopoulos^a

^aDepartment of Plastic and Reconstructive Surgery, Technical University of Munich, ^bDepartment of Plastic and Reconstructive Surgery, Hand Surgery and Burn Center, Klinikum Bogenhausen, Technical University of Munich, ^cInstitute of Experimental Oncology and Therapy Research, and ^dSection of Perinatal Medicine, Department of Obstetrics and Gynecology, Technical University of Munich, Munich, Germany; ^fCenter for Fetal Diagnosis and Treatment, Children's Hospital of Philadelphia and the University of Pennsylvania School of Medicine, Philadelphia, Pa., ^eDepartments of Obstetrics and Gynecology, Vanderbilt University Medical Center, Nashville, Tenn., and ^gDepartments of Surgery and Fetal Treatment Center, University of California, San Francisco, Calif., USA

Key Words

Myelomeningocele · Fetal surgery · Spina bifida ·
Open neural tube defects · Dysraphic syndromes

Abstract

Myelomeningocele is a common dysraphic defect leading to severe impairment throughout the patient's lifetime. Although surgical closure of this anomaly is usually performed in the early postnatal period, an estimated 330 cases of intrauterine repair have been performed in a few specialized centers worldwide. It was hoped prenatal intervention would improve the prognosis of affected patients, and preliminary findings suggest a reduced incidence of shunt-dependent hydrocephalus, as well as an improvement in hindbrain herniation. However, the expectations for improved neurological outcome have not been fulfilled and not all patients benefit from fetal surgery in the same way. Therefore, a multicenter randomized controlled trial was initiated in the USA to compare intrauterine with conventional postnatal care, in order to establish the procedure-related benefits and risks. The primary study endpoints include the need for shunt at

1 year of age, and fetal and infant mortality. No data from the trial will be published before the final analysis has been completed in 2008, and until then, the number of centers offering intrauterine MMC repair in the USA is limited to 3 in order to prevent the uncontrolled proliferation of new centers offering this procedure. In future, refined, risk-reduced surgical techniques and new treatment options for preterm labor and preterm rupture of the membranes are likely to reduce associated maternal and fetal risks and improve outcome, but further research will be needed.

Copyright © 2008 S. Karger AG, Basel

Background

Myelomeningocele (MMC) is a severe and complex birth defect caused by a failure in the process of neurulation in the 4th week of gestation. Although the number of new cases has steadily decreased in the past decades, each year more than 1,000 fetuses are diagnosed with MMC in the USA [1]. Worldwide, about 5 of 10,000 infants are born with spina bifida, with variations in population and geography [2–4]. The generic term spina bifida

KARGER

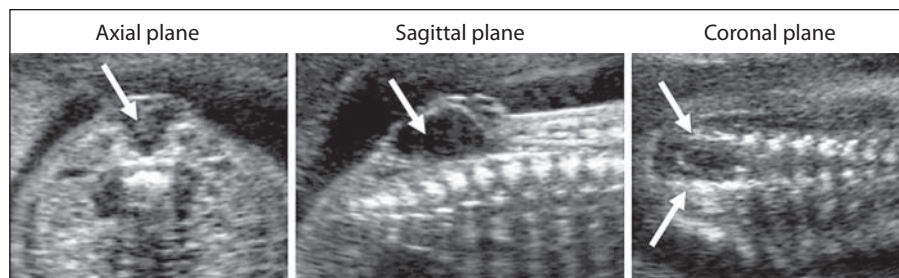
Fax +41 61 306 12 34
E-Mail karger@karger.ch
www.karger.com

© 2008 S. Karger AG, Basel
1015–3837/08/0234–0271\$24.50/0

Accessible online at:
www.karger.com/ftd

Nikolaos A. Papadopoulos, MD
Department of Plastic and Reconstructive Surgery, Klinikum rechts der Isar
Technical University of Munich
Ismaninger Strasse 22, DE-81675 Munich (Germany)
Tel. +49 89 4140 2171, Fax +49 89 4140 4869, E-Mail n.papadopoulos@lrz.tum.de

Fig. 1. Ultrasound images in 3 different planes show the described MMC defect (→) extending over 4 spinal levels (L3 to S1). The lesion is characterized by a fluid-filled sac (sagittal plane). As the cystic lesion fills with cerebrospinal fluid, the neural placode, which is scarred to the inside of the sac, is lifted out of the spinal canal and hair-like nerves can be seen rising through the sac (sagittal plane).



(forked spinal cord) subsumes a spectrum of neural tube defects (NTD) of which MMC is the most perilous survivable end of the scale, and is characterized by the protrusion of neural tissue through a defect in the vertebral arch and skin. After standard early postnatal defect closure, all affected patients show neurological deficits of varying degrees, such as sensory and motor weakness in the lower extremities, bowel and bladder incontinence, and sexual dysfunction. Additional complications arise from associated malformations like hydrocephalus and the Chiari II malformation (CM), and from secondary tethered cord syndrome and syrinx formation. It was hypothesized that the loss of neurological function is a gradual process and that some of the function might be preserved by repairing the defect in utero and avoiding damage to the exposed neural tissue in the intrauterine environment. MMC is now among the first nonlethal malformations that can be treated before birth.

Embryogenesis

At the beginning of the third week of gestation, the central nervous system (CNS) appears as a plate of thickened ectoderm called the neural plate. Controlled cell proliferation, cell migration and cell shaping in the neural plate lead to the formation of the neural groove in the median plane and neural folds on either side. The neural folds subsequently rise, approach each other and fuse to form the neural tube. The fusion begins in the cervical region and proceeds in both the cephalad and caudal directions. Neural crest derived ectomesenchyme in the cranial region and somitic mesenchyme in the spinal region grow around the newly developed neural tube and form the primordia of the meninges, vertebrae and autochthonous dorsal musculature. This whole process is called (primary) neurulation and is finished by the end of the 4th week of gestation [5].

NTD result from a failure in this process, but the exact pathogenesis is still in dispute [6]. Theories comprise developmental arrest in the process of neurulation [7], secondary rupture of a previously closed neural tube [8], overgrowth preventing correct infolding and fusion of the neural plate as well as disturbed cerebrospinal fluid hydrodynamics [9]. Regardless of which theory best describes the actual genesis of MMC, an open posterior neuropore and consequent insufficiency of migration of mesodermal tissues lead to a defect characterized by an open vertebral arch, and open meninges fused laterally to the skin forming a sac that contains protruding parts of the spinal cord (neural placode) (fig.1).

Etiology

Most likely, the etiology for MMC is multifactorial [10]. Genetic and environmental factors as well as gene-gene and gene-environment interactions are being discussed as possible causes for this aberration. In most cases, MMC manifests as a solitary disorder [11], but in less than 20% of cases, NTD are associated with chromosomal aberrations (i.e. trisomy 13, trisomy 18) or certain genetic syndromes (i.e. Waardenburg syndrome, Czeizel syndrome, Meckel-Gruber syndrome) [12, 13]. The probability of giving birth to another affected child is increased 10–20 times, supporting the genetic basis [14, 15]. Additional support comes from over 100 mutant mouse models (i.e. *circle tail*, *curly tail*, *loop tail*, *shrm*) and numerous knockouts, most of them phenotypically resembling human NTD to a large extent [16].

Differences in incidence depending on geographical location, socioeconomic status, season etc. suggest that environmental factors also play a role. Maternal diabetes [17], obesity [18], and hyperthermia [19, 20] have been discussed as possible risk factors. A number of pharmaceutical substances like certain antiepileptics, i.e. benzodiazepines, calcium-channel blockers and other active

substances are known to be teratogenic and potentially induce NTD [10].

A relationship between folic acid (FA) deficiency and the incidence of NTD is well established. Folic acid, an essential vitamin, plays an important role in one-carbon (1C) metabolism and is essential for the *de novo* synthesis of nucleotides for DNA synthesis and repair. Folate deficiency and mutations in the folate metabolic pathway are known to induce NTD [21, 22]. Periconceptional folate supplementation, on the other hand, has the potential to reduce the incidence of NTD. Since 1998, FA has been added to grains and bread in the United States. Since then, folate fortification and periconceptional supplementation has helped to decrease the incidence of NTD by 70% [23]. However, the level of FA fortification is low in order not to mask vitamin B12 deficiency. The validity of this rationale has been challenged repeatedly [24], since many women still do not achieve the recommended daily intake of 0.4 mg FA and the incidence of folic-acid-dependent NTD has remained considerably high [25]. However, it should be noted that about 30% of all NTD do not share this relationship with folate [23].

Prenatal Screening and Diagnosis

MMC can be diagnosed prenatally in over 80% of all cases by maternal serum α -fetoprotein (MSAFP) and high-resolution obstetrical ultrasound [26, 27]. Pathologic MSAFP levels (2–2.5 times the normal MSAFP level) and positive ultrasound findings can be followed by amniocenteses for acetylcholinesterase, α -fetoprotein and chromosomal analysis. In the USA, MSAFP is commonly examined at about 16 weeks of gestation. However, MSAFP does not constitute a significant screening parameter during the first trimester and it is not specific for NTDs; furthermore, multiple pregnancies, an error in calculating the stage of pregnancy, as well as a number of other birth defects can cause abnormal readings. Therefore, MSAFP screening is rarely used in Europe today.

Sonographically, spina bifida can be detected before the 12th postmenstrual week by noting irregularities of the bony spine or a bulging within the posterior contour of the fetal back [28] (fig. 2). Indirect signs like a characteristically shaped skull (lemon sign) and a dysplastic cerebellum (banana sign) are present in most MMC cases before the 24th week of gestation; these often disappear later in gestation [29]. Other common sonographic findings are ventriculomegaly, CM, obliteration of the cisterna magna, paralysis of the lower limbs or clubfoot deform-

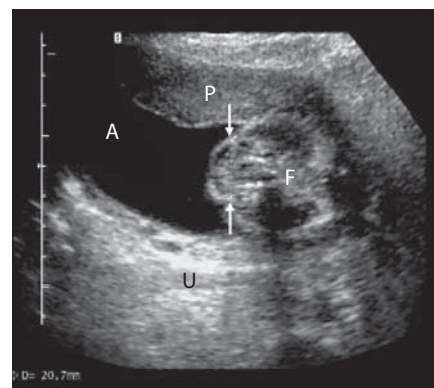


Fig. 2. Ultrasound image of a fetus (F) with a large sacral MMC (→) in the 17th week of gestation. Axial plane. P = Placenta; U = uterus, A = amniotic cavity.

ity. Serial ultrasonography may be used to identify the presence or absence of hydrocephalus (enlarged ventricles together with raised intracranial pressure) and other additional anomalies, and can detect a possible progression of the disease [27]. However, ultrasound evaluation of the fetal CNS is limited due to technical factors and progressive ossification of the skull, complicating the visualization of intracranial structures [30]. Therefore, magnetic resonance imaging (MRI), with ultrafast T_2 -weighted sequences, is now widely used for assessment of the fetal CNS [31]. Prenatal MRI enables acquisition of multiplanar views and allows a detailed visualization and evaluation of intracranial structures. Moreover, MRI can detect additional spinal cord anomalies (i.e. syrinx formation) in patients with sonographically diagnosed bony anomalies of the spine. This might help in prenatal counseling and could direct further treatment of the fetus [32].

Early prenatal diagnosis allows predications about neurological deficits [33] and the infant's estimated ambulatory status. The most meaningful predicament parameter for neurological impairment is the anatomic level of the lesion, with lower (sacral) levels exhibiting a better outcome than higher (thoracic) levels [34]. An early estimation of a child's prognosis might aid in prenatal counseling, giving expectant parents time to learn about their child's condition. If the parents decide to continue the pregnancy, an early diagnosis gives them time to find appropriate health care facilities where their future child can get pre- and postnatal special care.

Clinical Presentation

In the 19th century, before the times of aseptic surgery, most spina bifida patients died of infections. With the advent of aseptic surgery and prolonged survival, the development of hydrocephalus became a major concern, but could be controlled with the invention of the Spitz-Holter valve in the 1950s. Today, with aggressive treatment, the majority of patients survive the neonatal period and about 75% of the patients can be expected to reach early adulthood [35, 36]. The surviving children suffer from neurological deficits, depending on the level of the MMC. The disabilities range from weakness in the upper or lower extremities with mild sensoric paresthesia to severe physical and intellectual impairment with complete paraplegia and wheelchair dependency, double incontinence and sexual dysfunction. Additional complications arise from associated anomalies like hydrocephalus and CM. The majority of spina bifida patients (70%) have a normal IQ (above 80) [35, 37] and are able to attend normal school classes. About one fifth of patients need to attend special education classes [35, 36]. In a 25-year follow-up of 71 patients, 45% were actively employed and almost 10% worked as volunteers [36]. Most postnatally treated patients with an L5 or sacral MMC level can be expected to be able to walk, whereas the percentage of ambulatory patients with an L4 level drops significantly (57%) and none of the individuals with an MMC level above L3 can be expected to walk on a significant basis [36]. Motoric weakness and muscular atrophy can also be the cause of orthopedic deformations like talipes or scoliosis, requiring additional orthopedic interventions [36]. Moreover, later deterioration of motor function is common and the percentage of patients still ambulating decreases as they grow, so less than half of the patients continue to ambulate after reaching adulthood [36, 38]. A shifting in the strength-to-weight ratio, adhesions of the spinal cord (frequently occurring at the site of repair – tethered cord) and syringomyelia are possible explanations for this deterioration [39].

Dysfunction of the bladder and anal sphincter will, in most cases, demand clean intermittent catheterization and the use of enemas in order to reach social continence [36]. Steinbok et al. [35] reported 75% social continence of urine and 86% bowel continence in a 10-year follow-up of 101 postnatally treated spina bifida patients. Apart from social problems, bladder sphincter spasm or dyssynergia and a weak detrusor can lead to voiding dysfunction and consequent vesico-ureteral reflux, the most frequent cause of infections of the urinary

tract. Moreover, urinary retention can be the cause of hydronephrosis, renal hypertension and renal scarring. This can ultimately lead to acute renal failure which used to be the leading cause of death [40]. Today, however, with aggressive follow-up, including antibiotic prophylaxis, intermittent self-catheterization and a number of surgical procedures, renal injury can often be prevented [36].

Chiari II Malformation

The sequelae of MMC cannot be reduced to an uncovered spinal cord, but constitutes the result of a pancerebral abnormality associated with severe malformations throughout the nervous system. The most frequent anomalies associated with MMC are CM and hydrocephalus. In varying degrees, almost all MMC patients show signs of CM, a complex abnormality affecting the whole neuroaxis. As a predominant sign, hindbrain herniation is observed, defined as downward displacement of parts of the rhombencephalon (comprising the cerebellum, pons, and medulla oblongata) through the foramen magnum. The pathogenesis of CM is still open to debate. In their *unified theory*, McLone and Knepper [41] ascribe the development of the observed abnormalities to the continuous leak of cerebrospinal fluid (CSF) from the central canal, leading to a lack of distension in the embryonic ventricular system. This leads to a small posterior fossa and subsequent herniation of the rhombencephalon, as well as other associated abnormalities, including enlarged massa intermedia of the thalamus, beaking of the tectum, callosal dysgeneses as well as structural changes in the skull (fenestrated skull) and numerous anomalies in the cerebral hemispheres [6]. Curiously, despite its omnipresence, only about 20% of the patients show symptoms related to CM [42]. Nonetheless, lower cranial nerve compression, respiratory complications and apnea, all of them typical presentations of CM, are the most common cause of death in children (73%) [36, 38, 43, 44]. Other common symptoms comprise swallowing difficulty, stridor, bronchial aspiration, arm weakness and opisthotonos [45].

Syringomyelia describes tubular cavitations and gliosis in the spinal cord. Syringomyelia is present on MRI in 80% of spina bifida patients, but becomes symptomatic in only 2–5% [46–48]. Typical presentations are upper-extremity weakness or loss of function, scoliosis, progressive deterioration of lower-extremity motor function as well as lower cranial nerve compression and brainstem dysfunction (syringobulbia).

Hydrocephalus

Hydrocephalus, defined as increased intracranial pressure with distension of the ventricles, is present in the vast majority of affected patients [33, 35–37, 49, 50]. In the presence of spina bifida, cerebrospinal fluid leaks from the bottom of the spine, and accordingly CSF dynamics are substantially altered. Surgical repair of the structural defect stops further leakage of CSF from the central canal, and pressure within the cerebral ventricles often increases, resulting in hydrocephalus and the need for a ventricular shunt. In most cases, some sort of diversion is required, preferably ventriculoperitoneal shunting. The shunt rate after postnatal therapy is as high as 81–95% and several shunt-revisions are required in most of the patients [33, 35–37, 49–51]. In a 25-year follow-up of 71 spina bifida patients, 95% had undergone at least 1 shunt revision and 29% had at least 1 shunt infection. Especially in the first year after shunt placement, mechanical failure is a common problem with a failure rate of 40% in the first year, and 5% in subsequent years [52]. Each shunt placement procedure carries a 5–10% risk of shunt infection [52–54]. Shunt-associated complications, i.e. infections, shunt malfunction, are reported to be the most common cause of death in young adults [36], carrying a 1% per year mortality rate [55]. Apart from that, episodes of raised intracranial pressure secondary to an unrecognized malfunction of the shunt system, infections, hypoxemia and complications secondary to CM are discussed as probable causes of progressive mental retardation and later social nonachievement [56–58].

Symptomatic Tethered Cord

Tethered cord describes adhesions of the spinal cord to the repaired dura, resulting in a low conus medullaris (below L1–L2). With growth and development, the scarry adhesions lead to excessive stretching of the spinal cord, resulting in reduced mitochondrial oxidative metabolism [59, 60]. Symptomatic tethered cord (secondary tethered cord syndrome) was described as a possible cause of progressive neurological deterioration after the initial radical operation for spinal dysraphisms in numerous studies [61–70] with an incidence of 14–32% [36, 66, 70, 71]. Surgical untethering becomes necessary when symptoms of neurological deterioration manifest (deterioration of motor function, lumbosciatica, foot deformities, scoliosis and the beginning of bladder dysfunction). The procedure leads to an improvement of neurological function in 42–75%, possibly by way of improved oxidative metabolism [64, 67, 70].

Treatment

Until recently, parents expecting a child with prenatally diagnosed MMC had only 2 options: voluntary abortion or postnatal surgical closure followed by life-long medical care. Between 23 and 52% of the mothers chose termination of the pregnancy when confronted with their child's prognosis [72, 73]. In the last few years, fetal surgery has been offered to selected mothers as a third option of dealing with the problem.

Mode and Timing of Delivery

The uncovered neural tissue at the site of the MMC defect is vulnerable to mechanical and toxic trauma happening in the intrauterine environment during periods of labor and during birth. Several studies investigated the influence of time and route of delivery on neurological outcome [74–81]. Based on a review of this work, Anteby and Yagel [82] concluded that there is no conclusive evidence that caesarean section improves neurological outcome in children with spina bifida relative to vaginal delivery. Caesarean section might, however, be justified for large lesions in order to reduce the risk of trauma [82]. Induced early delivery (delivery before the 37th week of gestation) was discussed as another route of delivery that might reduce intrauterine trauma to the neural tissue, but no randomized trials were performed to confirm this effect. Induced early delivery may be indicated if rapidly increasing ventriculomegaly is observed and fetal lung maturity has been documented, otherwise term delivery is preferable [83]. In summary, the current data are inadequate to make a general recommendation about the optimal route of delivery, and the decision should therefore be individualized [83]. Future trials should address the effect of labor and the impact of time and route of delivery on neurologic outcome.

Standard Postnatal Care

The first cases of postnatal surgical reconstruction were described in 1892 [84]. Today, immediate postnatal closure within 48 h and life-long care is routinely performed in order to prevent ascending infections and to stabilize neurological function throughout lifetime. Since the mid-1970s it has become clear that this aggressive early postnatal repair combined with rigorous shunt placement, in order to control hydrocephalus and prevention of complications from neurogenic bladder disorder, makes long-term survival possible. Since then, however, progress in postnatal care has been limited and the sequelae of MMC remains devastating in many cases.

Moreover, the development of hydrocephalus seems to be inseparably linked to the surgical procedure preventing CSF leaking from the site of the defect. Some institutions advocate the thesis that the simultaneous insertion of a shunt during the repair operation might counteract this effect [85–87], but this attempt has been fiercely criticized because of the immense risks associated with shunting [88, 89].

Fetal Surgery

For more than 20 years, fetal surgery has been successfully performed for a number of life-threatening anomalies like congenital diaphragmatic hernia, lower urinary tract obstruction, congenital cystic adenomatoid malformation, sacrococcygeal teratoma and upper-airway obstruction. MMC might also be suitable for in utero treatment since it is compatible with life, is associated with considerable morbidity after postnatal care and can be detected before the 20th week of gestation. Prenatal repair might prevent intrauterine trauma and potentially preserve neurological function.

Evidence Supporting in utero MMC Repair

Fetal Wound Healing and Neuronal Regeneration

An important advantage of fetal surgery was believed to be a larger potential for wound healing and axonal regeneration of the fetus. Observations made in numerous animal experiments showed scarless wound healing of fetal skin [90–92], callus-free bone healing [93] and superior axonal regeneration [94–97]. Brunelli and Brunelli [98] demonstrated wound healing without scars and with no signs of inflammatory processes in rabbits after the surgical creation of a MMC-like defect. Callus-free bone healing was observed in fetal sheep after creation of a cleft-like defect [93]. Experiments with embryonic chicks demonstrated accelerated axonal regeneration after the complete transection of the spinal cord [94–97]. The degree of recovery was dependent upon the age at the time of transection. Early transected chicks were indistinguishable from controls, and even after complete neurogenesis, total functional and anatomical recovery were seen. However, this was lost if myelination had occurred already at the time of transection. In humans, the process of myelination has been documented to commence between the 15th and the 24th weeks of gestation, but progresses into the postnatal period [99]. For these reasons, intrauterine MMC repair (IUMR) might have the potential to reverse preexisting injuries to a certain degree.

Prevention of Secondary Damage

The neurological dysfunction in MMC could be a direct result of a developmental anomaly or a secondary effect caused by subsequent trauma. In fact, there are grounds to believe that both factors play a role in the deterioration – a theory often referred to as the two-hit hypothesis [100]. The first hit designates the primary defect in the neuroulation process leading to an NTD and myelodysplasia. The second hit is all subsequent injuries endured in the intrauterine environment leading to further mutilation of the exposed neural tissue. The rationale behind IUMR is to cover the dysraphic lesion before secondary damage leads to an irreversible loss of neural function.

Three preconditions must be fulfilled to justify IUMR from an experimental point of view. It has to be demonstrated that: (1) some function of the placode is preserved after the manifestation of the primary congenital anomaly, (2) there is a risk that this function could be lost in the course of gestation or at birth, and (3) fetal intervention can avert the secondary damage and save neurological function. Several observations made in vitro, in animal models and in humans support the theory that neurological function is preserved, despite the disordered neurulation, and gets lost later in gestation.

The histology of the spinal cord in the dysplastic region is preserved in large parts as late as the 55th day of gestation [101]. Further support comes from sonographic findings showing that normal fetal leg movements are present as early as 16–17 weeks, but get lost later in gestation [102, 103]. However, it is not clear yet whether the leg movements observed in utero were of cerebral origin or merely spinal arc reflexes.

There is experimental evidence that amniotic fluid is directly toxic to neural tissue [100, 104], and late gestational amniotic fluid seems to be more toxic to the neural tissue cultures than amniotic fluid from earlier gestational stages. This is probably due to a change of composition of amniotic fluid with accumulation of potentially toxic substances (urea, creatine, meconium and others) later in gestation [27]. Autopsies of stillborn human fetuses provide evidence supporting the idea that injury seen in neural tissue occurs later in pregnancy or during the perinatal period as a consequence of vaginal delivery [105, 106]. Recent histological and structural analysis of resected human placodes, using novel immunohistochemical molecular markers, suggest that both developmental malformation and secondary injury promote abnormal spinal cord function [107].

Observations of less severe forms of dysraphism (cervical dysraphism, lipomyelomeningocele, hemimyelocele) substantiate the idea of neurological function being preserved, despite the provoked myelodysplasia, if an adequate covering is provided [108]. In cervical dysraphism, a thick layer of skin covers the neural and bony defect. In contrast to the devastating effects observed in patients with (uncovered) MMC, children with cervical dysraphism have normal or near-normal neurological function [109]. Lipomyelomeningocele constitutes another milder variant of spinal dysraphism. A layer of lipoma covers the spinal cord and averts secondary injury. As a consequence, patients tend to have only minor sensorimotoric deficits and retained continence [110]. Possibly the most convincing example is hemimyelocele, a rare variation of MMC, in which one half of the defect is devoid of skin and meningeal covering, whereas the other half is covered by a layer of dura mater. Affected patients show only mild deficits in lower extremity function on the dural covered side, whereas on the side directly exposed to the intrauterine milieu, patients suffer from varying degrees of neurological impairment up to complete loss of function [111].

Surgical Repair in Animal Models

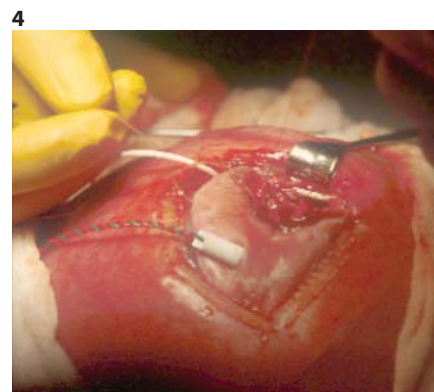
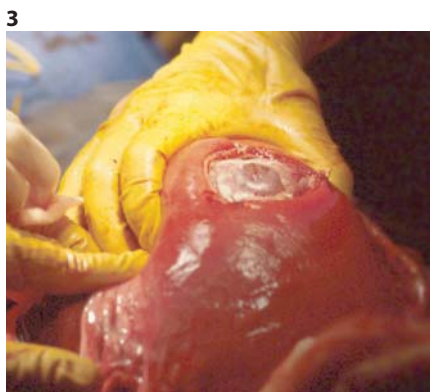
Numerous small and large animal models have been developed to closely resemble the human MMC and a great variety of material (autogeneic bone paste, skin grafts, cellulose grafts, latissimus dorsi pedicle flaps, autologous amnion grafts and standard multilayer technique) was used in order to close the artificial defect [112–115]. The feasibility of intrauterine creation and repair of a spina bifida-like defect was first demonstrated by Michejda [112] in a primate model in 1984. Eight *Macaca mulatta* fetuses underwent laminectomy between L3 to L5. The spinal cord was extruded from the central canal in order to create a MMC-like defect repaired directly afterwards using allogeneic bone paste to reconstruct the bony deficit. The in utero treated animal developed normally after birth, whereas 3 unrepaired control animals all showed symptoms of paraplegia, somatosensory deficits, as well as bowel and bladder dysfunction, comparable to symptoms observed in human spina bifida patients. Corresponding series of experiments with rats [100] and pigs [116] showed the same promising results even after a 24-hour delayed repair. These first studies supported the hypothesis that neurological function gets lost progressively in the course of gestation and can be preserved by intrauterine repair.

However, these models could not serve as an adequate comparison to the human situation with regard to developmental time and time of exposure to the intrauterine milieu, since the chosen time interval between the creation of the defect and its repair was too short to allow for a relevant exposure of the neural tissue to the intrauterine environment. Due to these considerations, Meuli et al. [117–120] created a mid-gestational (day 75 of a 145-day gestation) fetal sheep model with prolonged time of exposure to demonstrate the effect of a 25-day delayed repair of a MMC-like defect. Despite some neurological delay and hindlimb weakness, the repaired group showed almost normal neurological function when compared to the unrepaired control group. The intervention group was able to ambulate, showed no signs of incontinence and had intact somatosensory function, whereas the unrepaired lambs were severely handicapped. Since in this model, hindbrain herniation and other MMC-associated brain anomalies were not observed, Paek et al. [121] used the same surgical model to perform an additional myelotomy, in order to allow leakage of CSF, as can be seen in spontaneous MMC. In his series, the surviving fetal sheep in the unrepaired control group all developed hindbrain herniation, whereas the repaired animals showed no signs of herniation at birth. In a more recent study [122] corroborating Paek's findings, hindbrain herniation was observed in 85% of the sheep with additional myelotomy and had reversed in most animals 3 weeks after in utero closure. However, neither of the 2 studies allows conclusions to be drawn on neuromuscular function, since the posterior parts of the spinal cord were manipulated by the myelotomy, resulting in poor neurological function. Recently, Yoshizawa et al. [123, 124] demonstrated normal development of rectal and anal sphincter muscles and nerves after the creation and repair of a MMC-like defect in the mid-gestational sheep model, regardless of the repair method they used.

So far, animal experiments were successful in providing a promising basis for IUMR in humans. However, the genuine birth defect in humans develops as early as the first month, whereas the artificial defect in all animal models was created much later, in mid- or late gestation. With regard to the time of exposure of the neural tissue to chemical and mechanical forces, the experimental setup still does not correspond well enough to the human situation. To deal with this issue, other methods beside surgical creation have been tested to induce a NTD at an earlier stage in gestation. These methods include drug-induced NTD [125] and genetic mutations [16]. Still, each of these methods is beset with certain drawbacks. Drugs on

Fig. 3. The fetus is positioned with the spina bifida defect centered in the hysterotomy. Polyglycolic acid staples hold all the layers of the uterus together, with little or no blood loss. A combination of general and regional anesthesia provides marked uterine atony, allowing easy manipulation of the fetus. From Bruner et al. [51].

Fig. 4. The MMC is repaired by the pediatric surgeon using standard neonatal techniques.



the one hand, have a tendency to induce a large variety of different anomalies in the same creature, making it difficult to attribute symptoms to a specific defect. On the other hand, a large number of multifactorious genetic mutant models exist, but even if dysraphic syndromes were induced by a single-gene defect, which is not the case, this gene would be unlikely to be the same in humans.

The inadequacy of hitherto existing animal models might in part explain the discrepancy between benefits seen in the animal model and in humans after IUMR. Large animal models with a long pregnancy time, early nonsurgical induction of the defect, and a delayed repair would be needed to allow a more realistic prognosis of what can be expected from IUMR.

Early Experience with Humans

The first 4 cases of IUMR were performed between 1994 and 1997 [126, 127]. Minimally invasive technology was used with the intention to reduce maternal and fetal risks, but the results were poor and the fetoscopic approach was therefore abandoned. Soon after that, the first open repairs were performed in rapid succession at 2 centers in the USA: the Children's Hospital of Philadelphia (CHOP) and at the University Medical Center of Vanderbilt (VUMC) in 1997 [128, 129]. The results of the first open repairs were more promising. The first case report of open IUMR presented evidence of improved neurological functioning after covering the defect in a fetus with thoracolumbosacral defect in the 23rd week of gestation [129]. Despite a right clubfoot deformity, the baby showed flexion and extension in knee and hip (L4 level) at birth and had, except for absence of plantar flexion, normal motor function of the left foot (L5 level). It should be mentioned that almost all neonates with thoracolumbar lesions are paraplegic and require shunt placement in order to treat hydrocephalus [33]. Unfortunately, at 6 months of

age, severe tethering of the spinal cord required surgical release and resulted in a loss of the gained motor function. The report of the first 3 cases treated in utero at VUMC, however, showed no benefit regarding neurological function [128]. It was speculated that the cause for the discrepancy in neurological outcome between the 2 centers was the different age of the fetuses at the time of repair (22–25 weeks at CHOP vs. 28–30 weeks at VUMC).

Notwithstanding this dissimilarity, another important outcome was unexpectedly observed at both institutions. After repair of the NTD, the patients demonstrated an improvement in CM, seen in a reduction and even reversal of preexisting hindbrain herniation [129, 130]. Equally important and of indisputable clinical interest was the observation that IUMR seemed to have a positive effect on hydrocephalus, resulting in a decreased need for ventriculoperitoneal shunting [130]. Considering the substantial morbidity and mortality caused by CM and shunt-dependent hydrocephalus, these findings strongly supported the idea of prenatal intervention.

Current Data of Intrauterine MMC Repair in Humans

Today, open IUMR is being offered to selected mothers at 3 centers in the USA and a few centers in Europe and South America [131–135]. More than 330 such interventions have been performed during the past 8 years (fig. 3–5). A number of outcome measures could be extracted from the short-term clinical outcome that allow a temporary conclusion to be drawn about the potential benefits and risks of IUMR.

Chiari II Malformation and Hindbrain Herniation

Partial regression of CM, particularly in the reduction of hindbrain herniation, has been observed at all 3 centers

in the USA, corroborating the results of the earlier case series [130, 133, 134]. Although symptoms related to CM manifest in only 20% of patients [42], respiratory complications and apnea resulting from brainstem and lower cranial nerve compression remain the most common causes of death in children with CM [36, 38, 43, 44]. Thus, fetal surgery might reduce the mortality rate in early childhood significantly. So far, however, no long-term data have produced evidence that the observed reduction of hindbrain herniation leads to a reduction of symptoms and a decreased mortality. Large cohorts would be necessary in order to evaluate the clinical relevance, since CM becomes symptomatic in no more than one fifth of all affected patients [42].

Hydrocephalus and the Need for Shunt

Preliminary experience at Vanderbilt and CHOP shows a significant decrease in shunt-dependent hydrocephalus. In a series of 178 patients treated in utero at VUMC, the shunt rate was 46% [136] compared with 95% in historical controls [51]. A similar rate (43%) could be seen from 51 cases treated at CHOP [133]. Even in those babies who require shunt placement, the median age at which this occurs is 86 days (range, 1–410 days) compared to 5 days (range, 1–46 days) in historical controls [51, 136]. The preliminary data from both institutions suggest that especially those patients with an estimated gestational age of less than 25 weeks at the time of surgery, patients with a ventricle size of <14 mm and patients with lesion levels below L2 benefit from IUMR [132]. In particular, the shunt rate drops significantly from 71 to 39% when fetal surgery is performed prior to 25 weeks. On the other hand, no significant benefit was achieved in patients with lesions above L3 or if surgery was performed after 25 weeks of gestation [132]. The necessity for shunt placement can be predicted in about 80% of the cases if 3 parameters, the estimated gestational age, the anatomic level of the defect and the size of the ventricles at the time of surgery, are known [137]. However, the objectivity of the timing for shunt-placement has been debated because no generally accepted objective criteria existed to define the correct time for shunt placement. In most cases, mothers were discharged from the hospital with their child after a short period of observation and the decision of shunt placement was made elsewhere. For that reason, shunt placement became very difficult to control. Bannister [6] raises another issue, namely that parents and medical practitioners might have become ‘shunt averse’. Starting from the belief that shunt placement after IUMR is a treatment failure, the treating physician might try to

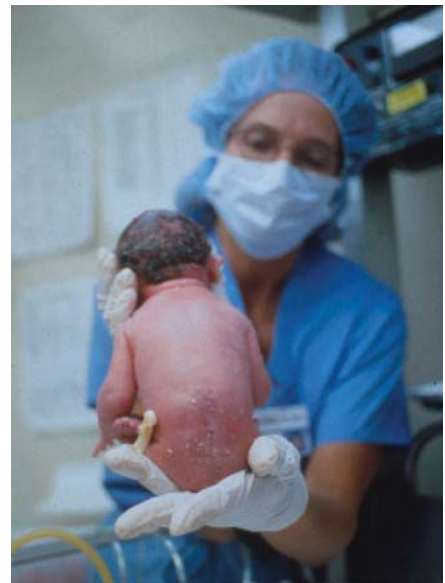


Fig. 5. The surgical wound of the fetus is almost completely healed after 3 weeks postoperatively in the uterine environment. The uterine scar heals well, but caesarean delivery is required in this and every pregnancy because of the fundal hysterotomy scar.

avoid shunt placement initially unless a life-threatening reason demands it. Therefore, the need for a shunt might not decrease but just be delayed. All these considerations have been taken into account when planning the ‘Management of MMC Study’ (see below).

Sensorimotor Function of the Lower Limbs

Current reports from the different institutions on neurological function are as conflicting as earlier reports. No benefit for leg function was reported by VUMC or the University of California at San Francisco [134, 138], whereas short-term clinical data from CHOP suggest better function in 57% (24 of 42) of the surviving infants with thoracic or lumbar defects, at least in the early postnatal period [129, 133]. Patients with lower lumbar and sacral lesions, however, did not benefit from the surgery [133]. In a cohort of 37 patients treated prenatally at VUMC, no difference in sensorimotor function, with correlating functional and anatomic lesion levels, was observed, even when gestational age at the time of surgery was taken into account [138]. Data from the first 13 patients treated at the University of California at San Francisco between 1998 and 2002 corroborate these findings, with sensorimotor function in the lower body being, within 1 or 2 vertebral levels of the bony lesion level [134], comparable to conventional postnatal outcome [49].

One possible explanation for this difference in outcome may have been patient selection. At CHOP, fetuses with talipes or absent leg movement in prenatal ultrasound were excluded. These strict eligibility criteria for IUMR at CHOP might have filtered out patients whose neurological impairment had deteriorated to a point at which surgery could not have contributed to an improvement of the situation. Therefore, it is possible that the CHOP group may have identified a good prognosis group for leg function [136], just as the Vanderbilt group was able to identify a good prognosis group for shunt requirement [137]. Notably, the findings represent data collected in the early postnatal period, and time will tell if neurological function can be preserved into adulthood.

Continence

To date, only 2 small studies on bladder function have been conducted [139, 140]. A total of 22 patients (16 and 6 cases) were examined using videourodynamics, voiding cystometrograms, renal/bladder ultrasound and other investigation methods in order to evaluate urinary function. Neither of the reports showed improvement in bladder function when patients were compared to conventionally treated controls. Anatomical abnormalities of the urinary tract and pathologic urodynamic parameters corresponded to the results seen in spina bifida patients without closure of the spinal lesion during gestation. However, the 2 studies are small and the infants' age was no older than a mean of 6.5 months at the time of the examination. Besides, one has to keep in mind that a large part of the complete cohort of intrauterinely treated patients with spina bifida has not yet reached an age at which toilet training becomes practical. Until long-term data is available, reliable statements on social continence and sexual function cannot be made.

Symptomatic Tethered Cord

It was speculated that IUMR might improve wound healing and avoid scarring that is causally related to the development of tethered cord. Tethered cord is one of the leading causes responsible for loss of neurological function [61–71]. About one third of postnatally treated spina bifida patients develop symptomatic tethered cord, requiring surgical release in order to avoid further deterioration [36]. However, occurrence of tethered cord requiring surgical release was also observed after IUMR [141]. Mazzola et al. [141] report 3 cases in which deterioration of the neurologic status (loss of motor function, progressive scoliosis or the beginning of bladder dysfunction) occurred due to dermoid inclusion cysts and tethered

cord, requiring excision of the cyst and microsurgical release of the intradural adhesions. Interestingly, in all cases, tethered cord had manifested before the age of 1, whereas in conventionally treated groups, the average age at presentation is 6–11 years, and only 1 of 100 show symptoms related to tethered cord before the age of 1 [142]. The concrete cause of the tethering of the cord has not been examined in these cases, but might be related to poor operating conditions, not using a microscope, operating under time pressure and problems discerning between fetal skin and the tissues of the placode. The authors, however, speculate that the tethering of the cord might also be the result of a higher potential for rapid growth in the fetus [141] – an assumption conflicting with the observations of scarless fetal wound healing seen in early gestation. Of course, the small number of patients described in these case reports is not representative and adhesions might have been discovered early as a result of the careful surveillance IUMR patients have to undergo. However, if this complication turns out to be a serious risk associated with in utero surgery, operative techniques and the correct time for surgery will have to be thought over.

Maternal and Fetal Risks

Fetal surgery always involves fetus and mother and is accordingly associated with risks for both. Possible risks for the fetus include further damage to the spinal cord and nerves, prematurity, membrane separation leading to early delivery and interference with the blood supply for fetal body parts. Of all these risks, iatrogenic prematurity remains the Achilles heel of maternal-fetal surgery – the predominant cause of complications and fetal death. Current statistics suggest a perinatal morbidity and mortality attributable to extreme prematurity of 11.8 and 2.8%, respectively [136]. In virtually every case, preterm labor occurs at some time or other in the course of gestation [51], eventually leading to preterm delivery at a mean age of 34 weeks [133, 143]. The spectrum of complications arising from premature delivery following maternal-fetal therapy is no different from complications associated with prematurity resulting from other causes [144]: hypothermia, respiratory distress syndrome, chronic lung disease, patent ductus arteriosus, necrotizing enterocolitis and infections are the most frequent complications resulting from anatomic or functional immaturity [143]. Moreover, premature birth after maternal-fetal surgery always carries the risk of perinatal neurological injury to the infant's immature brain [11].

Potential maternal risks are wound infection, intrauterine infection, amniotic fluid leak, premature preterm rupture of membranes, infertility, bleeding and side effects from the medication or complications from general anesthesia. A cesarean section must be performed in this and all subsequent pregnancies as a precautionary measure to prevent uterus rupture. The little data available on maternal risks after IUMR suggest that the most frequent complications are oligohydramnios (25%), preterm labor and preterm membrane separation or rupture [136]. Maternal fertility seems to be unaffected by the intervention, but at present, no prospective long-term data exist to confirm this assumption made in 2 rather small studies [145, 146]. There are reports of potentially life-threatening complications such as pulmonary edema (5.1%), uterine dehiscence (2.2%) or rupture and bowel obstruction (0.5%) [133, 136]. Fortunately, until today no maternal mortality has occurred after IUMR. However, at least 8 infants have died from complications associated with preterm labor and premature birth after surgical interventions.

Management of MMC Study

Many questions about potential benefits of IUMR and the clinical relevance of current findings remain unanswered and the risks for the fetus and mother have not been established, yet. So far, patients were only compared to historical controls and therefore, all results must be considered preliminary until validated scientifically. As a result, IUMR has become controversial; discussed in public and among maternal-fetal specialists [147]. With this in mind, the National Institute of Health and Human Development funded a 5-year-prospective multicenter randomized controlled trial in February 2003 [148]. The goal of this trial is to evaluate the benefits and risks of IUMR compared to standard postnatal care. The Management of MMC Study (MOMS) is an unblinded, randomized trial with 100 patients in the prenatal repair group and 100 patients in the postnatal repair group. All 3 centers currently performing IUMR in the USA are participating, coordinated through the George Washington University Biostatistics Center. A 4th institution has abandoned fetal surgery to serve the trial. Significantly, it was generally agreed that no IUMR would be offered in the United States outside of the trial, in order to prevent a backdoor effect. Based on the early experience of the 3 centers, selection criteria for IUMR include an MMC level at or above S1 with hindbrain herniation on MRI, ges-

tation <26 weeks, normal leg movement and absence of talipes, lateral ventricle diameter <17 mm as well as normal fetal karyotype. If all inclusion and no exclusion criteria are met, and the mother wishes to participate in the study, she will be randomized into either intrauterine or standard treatment. If randomized to the fetal surgery group, surgery will be performed prior to 26 weeks of gestation and the baby will be delivered by caesarean section at approximately 37 weeks of gestation. Mothers randomized to standard care will return home until the 37th gestational week, when delivery will be performed by caesarean section at the assigned MOMS center.

The early data suggest the only outcome variables that could be expected to reach significance are fetal mortality and the need for shunt. Therefore, these 2 parameters were chosen as primary outcome measures and will be assessed at 1 year of age. In order to prevent an unconscious bias against shunting in the IUMR group, shunts will be placed according to strict criteria and an independent group of pediatric neurosurgeons will review each case to ensure that the criteria have been met [149]. Secondary outcome measures are motor function, urologic function and intelligence. Morbidity and mortality as well as any required surgical intervention will be recorded.

Future Perspectives

The first cases of MMC repair were performed fetoscopically to minimize maternal risks – but proved unsuccessful [126]. Repeated attempts to reintroduce minimally invasive surgery demonstrated again the technical difficulty associated with this procedure [131, 134]. Today, with recent advances in robotics, some of these technical difficulties might be solved, e.g. using a computer between the surgeon's hands and the robot's arms to downscale movements and filter out physiological tremor. 3D optics and a sophisticated control mechanism allow the surgeon to operate the robot equipment in a very precise way. Pilot experiments with the da Vinci robotic operating system successfully demonstrated the superiority of robot-assisted fetoscopy in a sheep model [150]. Spina bifida-like lesions were created in the fetal lambs and then repaired. All lesions were repaired satisfactorily with only 1 case of postoperative membrane collapse. An important advantage of the laparoscopic approach might be that patients could deliver vaginally at term, whereas after hysterotomy, all pregnancies deliver prematurely and require caesarean section in this and all future preg-

nancies. This would mean a significant shift in the risk: benefit ratio for intrauterine surgery, potentially allowing intrauterine interventions for other nonfatal anomalies, which cannot now justifiably be addressed by fetal surgery.

In order to find ways to deal with the most important risk of fetal surgery, prematurity, alternative methods for amniotic membrane closure were tested that might help to reduce the incidence of iatrogenic preterm prelabor rupture of membranes. In an attempt to treat or prevent this condition, miscellaneous tissue sealants were applied intracervically or intra-amniotically, but the success was limited. Numerous matrices and sealants were inserted into fetal membrane defects in order to improve the low wound-healing activity of fetal membranes [151–155]. In recent times, tissue engineering was used to support fetal membrane suturing [156, 157]. Human amniotic extracellular matrix scaffold has been shown to support amniotic cell in-growth [157] and engineered native rabbit amniotic membrane scaffolds could successfully enhance fetal wound healing response in surgical membrane defects in rabbits [158].

Progressive injury to the fetal spinal cord in utero, an increasing tendency of fetal tissues to develop scars later in gestation along with a decreased ability of neuronal regeneration after the onset of myelination might be responsible for unsatisfactory results seen today. In future, refined, risk-reduced surgical techniques and innovative treatment options for the iatrogenic preterm prelabor rupture of membranes along with advances might help to reduce the risk of prematurity and allow fetal surgery at an earlier time in gestation. Earlier closure could prevent further intrauterine damage and might reduce the risk of scarry adhesions (tethered cord) affecting neural function.

Conclusion

Preliminary findings suggest that intrauterine MMC repair leads to a reversal of hindbrain herniation and a decreased incidence of shunt-dependent hydrocephalus. Especially fetuses treated before 26 weeks of gestational age, with small ventricles (<14 mm) at the time of surgery, and lesion levels below L2 seem to profit from fetal surgery. However, the clinical relevance of the observed regression of CM is still in dispute and a positive effect on sensorimotor function could only be observed for patients with higher lumbar and thoracic spinal defects in the early postnatal period. The ongoing multicenter trial

comparing pre- and postnatal treatment will answer many of the remaining questions and allow us to draw a more precise picture of who might profit from fetal intervention and help filter out those who are safer with postnatal treatment. However, given the small amount of improvement, the evaluation of neurologic improvement would demand a far larger number of patients to treat in order to reach significance, since motor outcome and cognitive performance would have to be compared to each lesion level [134]. While the MOMS trial is establishing a definite list of risks and benefits related to IUMR, only 3 specialized clinical and experimental centers in the USA are permitted to offer this procedure. Surely enough, the National Institute of Health and Human Development had forced this trial not only for the reason to answer the questions posed above, but also to stop the further proliferation of centers in the USA offering an ‘unmanaged innovation’ [159]. However, these limitations do not apply outside the USA. Centers outside the USA considering offering this procedure should be cautioned by the associated risks and the learning curve of a complex procedure that has not yet proven its safety and efficacy. In the words of Olutoye and Adzick [160], ‘Until the benefits of fetal (meningomyelocele) repair are carefully elucidated, weighed against maternal and fetal risks and compared to conventional postnatal therapy, this procedure should be restricted to a few centers that are committed (clinically and experimentally) to investigating these issues.’

Acknowledgements

We wish to thank the members of our intrauterine surgery team: R. Bergmeyer, E. Brendle, T. Brill DVM, W. Erhardt, Dr. med. vet. R. Hertel, S. Klotz, M. Leucz, B. Matzen, B. Pichotka, V. Pohlheimer, A. Raith and S. Riedel of the Institute of Experimental Oncology and Therapy Research for their fruitful discussions. Dr. P. Boettcher of the Department of Small Animal Surgery & Institute of Veterinary Anatomy, Ludwig Maximilians University Munich, Prof. M.A. Papadopoulos of the Department of Orthodontics, Aristotle University of Thessaloniki and Prof. H.-F. Zeilhofer of the Department of Oral & Maxillofacial Surgery, Technical University of Munich are thanked for their discussion and for review of the manuscript.

References

- 1 Centers for Disease Control and Prevention: Folic acid and prevention of spina bifida and anencephaly. *MMWR* 2002;51(RR-13):9–11.
- 2 Boockvar JA, Loudon W, Sutton LN: Development of the Spitz-Holter valve in Philadelphia. *J Neurosurg* 2001;95:145–147.
- 3 Moore CA, Li S, Hong S, et al: Elevated rates of severe neural tube defects in a high-prevalence area in northern China. *Am J Med Genet* 1997;73:113–118.
- 4 Feuchtbaum LB, Currier RJ, Riggle S, Robertson M, Lorey FW, Cunningham GC: Neural tube defect prevalence in California (1990–1994): eliciting patterns by type of defect and maternal race/ethnicity. *Genet Test* 1999;3:265–272.
- 5 Colas JF, Schoenwolf GC: Towards a cellular and molecular understanding of neurulation. *Dev Dyn* 2001;221:117–145.
- 6 Bannister CM: The case for and against intrauterine surgery for myelomeningoceles. *Eur J Obstet Gynecol Reprod Biol* 2000;92:109–113.
- 7 Warkany J, Wilson JG, Geiger JF: Myeloschisis and myelomeningocele produced experimentally in the rat. *J Comp Neurol* 1958;109:35–64.
- 8 Padgett DH: Spina bifida and embryonic neuroschisis – a causal relationship. Definition of the postnatal conformations involving a bifid spine. *Johns Hopkins Med J* 1968;123:233–252.
- 9 Gardner W: The Dysraphic States from Syringomyelia to Anencephaly. Amsterdam, Excerpta Medica, 1973, pp 1–201.
- 10 Manning SM, Jennings R, Madsen JR: Pathophysiology, prevention, and potential treatment of neural tube defects. *Ment Retard Dev Disabil Res Rev* 2000;6:6–14.
- 11 Aguiar MJ, Campos AS, Aguiar RA, Lana AM, Magalhaes RL, Babeto LT: Neural tube defects and associated factors in liveborn and stillborn infants. *J Pediatr* 2003;79:129–134.
- 12 Coerdts W, Miller K, Holzgreve W, Rauskolb R, Schwinger E, Rehder H: Neural tube defects in chromosomally normal and abnormal human embryos. *Ultrasound Obstet Gynecol* 1997;10:410–415.
- 13 Lynch SA: Non-multifactorial neural tube defects. *Am J Med Genet C Semin Med Genet* 2005;135:69–76.
- 14 Rinke U, Koletzko B: Prävention von Neuralrohrdefekten durch Folsäurezufuhr in der Frühschwangerschaft. *Dtsch Arztebl* 1994;91:A0–A37.
- 15 Bässler KH GILD, Pietrik K: Vitamin-Lexikon für Ärzte, Apotheker und Ernährungswissenschaftler, ed 3. München, Urban & Fischer, 2002.
- 16 Harris MJ: Why are the genes that cause risk of human neural tube defects so hard to find? *Teratology* 2001;63:165–166.
- 17 Ray JG, Vermeulen MJ, Meier C, Wyatt PR: Risk of congenital anomalies detected during antenatal serum screening in women with pregestational diabetes. *QJM* 2004;97:651–653.
- 18 Dietl J: Maternal obesity and complications during pregnancy. *J Perinat Med* 2005;33:100–105.
- 19 Moretti ME, Bar-Oz B, Fried S, Koren G: Maternal hyperthermia and the risk for neural tube defects in offspring: systematic review and meta-analysis. *Epidemiology* 2005;16:216–219.
- 20 Suarez L, Felkner M, Hendricks K: The effect of fever, febrile illnesses, and heat exposures on the risk of neural tube defects in a Texas-Mexico border population. *Birth Defects Res [A]* 2004;70:815–819.
- 21 Richter B, Stegmann K, Roper B, Boddeker I, Ngo ET, Koch MC: Interaction of folate and homocysteine pathway genotypes evaluated in susceptibility to neural tube defects (NTD) in a German population. *J Hum Genet* 2001;46:105–109.
- 22 Morrison K, Papapetrou C, Hol FA, Mariman EC, Lynch SA, Burn J, Edwards YH: Susceptibility to spina bifida; an association study of 5 candidate genes. *Ann Hum Genet* 1998;62:379–396.
- 23 MRC Vitamin Study Research Group: Prevention of neural tube defects: results of the Medical Research Council Vitamin Study. *Lancet* 1991;338:131–137.
- 24 Brent RL, Oakley GP Jr: The folate debate. *Pediatrics* 2006;117:1418–1419.
- 25 Choumenkovitch SF, Selhub J, Wilson PW, Rader JI, Rosenberg IH, Jacques PF: Folic acid intake from fortification in United States exceeds predictions. *J Nutr* 2002;132:2792–2798.
- 26 Brock DJ, Barron L, Raab GM: The potential of mid-trimester maternal plasma alpha-fetoprotein measurement in predicting infants of low birth weight. *Br J Obstet Gynaecol* 1980;87:582–585.
- 27 Bruner JP, Davis G, Tulipan N: Intrauterine shunt for obstructive hydrocephalus – still not ready. *Fetal Diagn Ther* 2006;21:532–539.
- 28 Braithwaite JM, Armstrong MA, Economides DL: Assessment of fetal anatomy at 12 to 13 weeks of gestation by transabdominal and transvaginal sonography. *Br J Obstet Gynaecol* 1996;103:82–85.
- 29 Nicolaides KH, Campbell S, Gabbe SG, Guidetti R: Ultrasound screening for spina bifida: cranial and cerebellar signs. *Lancet* 1986;iii:72–74.
- 30 Levine D, Barnes PD, Madsen JR, Abbott J, Wong GP, Hulka C, Mehta T, Li W, Edelman RR: Fetal CNS anomalies revealed on ultrafast MR imaging. *AJR* 1999;172:813–818.
- 31 Levine D, Barnes PD, Robertson RR, Wong G, Mehta TS: Fast MR imaging of fetal central nervous system abnormalities. *Radiology* 2003;229:51–61.
- 32 von Koch CS, Glenn OA, Goldstein RB, Bar-kovich AJ: Fetal magnetic resonance imaging enhances detection of spinal cord anomalies in patients with sonographically detected bony anomalies of the spine. *J Ultrasound Med* 2005;24:781–789.
- 33 Cochran DD, Wilson RD, Steinbok P, Farquharson DF, Irwin B, Irvine B, Chambers K: Prenatal spinal evaluation and functional outcome of patients born with myelomeningocele: information for improved prenatal counselling and outcome prediction. *Fetal Diagn Ther* 1996;11:159–168.
- 34 Lorber J: Results of treatment of myelomeningocele: an analysis of 524 unselected cases, with special reference to possible selection for treatment. *Dev Med Child Neurol* 1971;13:279–303.
- 35 Steinbok P, Irvine B, Cochran DD, Irwin BJ: Long-term outcome and complications of children born with meningocele. *Childs Nerv Syst* 1992;8:92–96.
- 36 Bowman RM, McLone DG, Grant JA, Tomita T, Ito JA: Spina bifida outcome: a 25-year prospective. *Pediatr Neurosurg* 2001;34:114–120.
- 37 McLaurin R: Myelomeningocele: outcome and late complication; in Section of Pediatric Neurosurgery of the American Association of Neurological Surgeons (ed): *Pediatric Neurosurgery: Surgery of the Development Nervous System*, ed 2. Saunders, Philadelphia, 1989, pp 53–70.
- 38 McLone DG: Continuing concepts in the management of spina bifida. *Pediatr Neurosurg* 1992;18:254–256.
- 39 Hirose S, Meuli-Simmen C, Meuli M: Fetal surgery for myelomeningocele: panacea or peril? *World J Surg* 2003;27:87–94.
- 40 Singhal B, Mathew KM: Factors affecting mortality and morbidity in adult spina bifida. *Eur J Pediatr Surg* 1999;9(suppl 1):31–32.
- 41 McLone DG, Knepper PA: The cause of Chiari II malformation: a unified theory. *Pediatr Neurosci* 1989;15:1–12.
- 42 Rauzzino M, Oakes WJ: Chiari II malformation and syringomyelia. *Neurosurg Clin N Am* 1995;6:293–309.
- 43 Cochran DD, Adderley R, White CP, Norman M, Steinbok P: Apnea in patients with myelomeningocele. *Pediatr Neurosurg* 1990;16:232–239.
- 44 McLone D: The cause of the Chiari malformation; in Matsumoto S, Sato H (eds): *International Symposium on Spina Bifida, School Age and Adolescence. Part II*. Tokyo, Springer, 1997.

- 45 Park TS, Hoffman HJ, Hendrick EB, Humphreys RP: Experience with surgical decompression of the Arnold-Chiari malformation in young infants with myelomeningocele. *Neurosurgery* 1983;13:147-152.
- 46 Cameron AH: The Arnold-Chiari and other neuro-anatomical malformations associated with spina bifida. *J Path Bact* 1957;73:195-211.
- 47 Mackenzie NG, Emery JL: Deformities of the cervical cord in children with neurospinal dysraphism. *Dev Med Child Neurol* 1971;13:59-67.
- 48 LaMarca F, Grant JA, Tomita T, McLone DG: Spinal lipomas in children: outcome of 270 procedures. *Pediatr Neurosurg* 1997;26:8-16.
- 49 Rintoul NE, Sutton LN, Hubbard AM, Cohen B, Melchionni J, Pasquariello PS, Adzick NS: A new look at myelomeningoceles: functional level, vertebral level, shunting, and the implications for fetal intervention. *Pediatrics* 2002;109:409-413.
- 50 Tulipan N, Bruner JP, Hernanz-Schulman M, Lowe LH, Walsh WF, Nickolaus D, Oakes WJ: Effect of intrauterine myelomeningocele repair on central nervous system structure and function. *Pediatr Neurosurg* 1999;31:183-188.
- 51 Bruner JP, Tulipan N, Paschall RL, Boehm FH, Walsh WF, Silva SR, Hernanz-Schulman M, Lowe LH, Reed GW: Fetal surgery for myelomeningocele and the incidence of shunt-dependent hydrocephalus. *JAMA* 1999;282:1819-1825.
- 52 Chumas P, Tyagi A, Livingston J: Hydrocephalus - what's new? *Arch Dis Child* 2001;85:F149-F154.
- 53 Drake JM, Kestle JR, Milner R, Cinalli G, Boop F, Piatt J Jr, Haines S, Schiff SJ, Cochrane DD, Steinbok P, MacNeil N: Randomized trial of cerebrospinal fluid shunt valve design in pediatric hydrocephalus. *Neurosurgery* 1998;43:294-303, discussion 303-305.
- 54 Langley JM, LeBlanc JC, Drake J, Milner R: Efficacy of antimicrobial prophylaxis in placement of cerebrospinal fluid shunts: meta-analysis. *Clin Infect Dis* 1993;17:98-103.
- 55 Iskandar BJ, Tubbs S, Mapstone TB, Grabb PA, Bartolucci AA, Oakes WJ: Death in shunted hydrocephalic children in the 1990s. *Pediatr Neurosurg* 1998;28:173-176.
- 56 Hunt GM: The Casey Holter lecture. Non-selective intervention in newborn babies with open spina bifida: the outcome 30 years on for the complete cohort. *Eur J Pediatr Surg* 1999;9(suppl 1):5-8.
- 57 Mataro M, Poca MA, Sahuquillo J, Cuxart A, Iborra J, de la Calzada MD, Junque C: Cognitive changes after cerebrospinal fluid shunting in young adults with spina bifida and assumed arrested hydrocephalus. *J Neurol Neurosurg Psychiatry* 2000;68:615-621.
- 58 Phuong LK, Schoeberl KA, Raffel C: Natural history of tethered cord in patients with meningomyelocele. *Neurosurgery* 2002;50:989-993, discussion 993-995.
- 59 Stoodley MA, Gutschmidt B, Jones NR: Cerebrospinal fluid flow in an animal model of noncommunicating syringomyelia. *Neurosurgery* 1999;44:1065-1075, discussion 1075-1066.
- 60 Tani S, Yamada S, Knighton RS: Extensibility of the lumbar and sacral cord. Pathophysiology of the tethered spinal cord in cats. *J Neurosurg* 1987;66:116-123.
- 61 Anderson FM: Occult spinal dysraphism: a series of 73 cases. *Pediatrics* 1975;55:826-835.
- 62 Boor R, Schwarz M, Reitter B, Voth D: Tethered cord after spina bifida aperta: a longitudinal study of somatosensory evoked potentials. *Childs Nerv Syst* 1993;9:328-330.
- 63 Heinz ER, Rosenbaum AE, Scarff TB, Reigel DH, Drayer BP: Tethered spinal cord following meningomyelocele repair. *Radiology* 1979;131:153-160.
- 64 Linder M, Rosenstein J, Sklar FH: Functional improvement after spinal surgery for the dysraphic malformations. *Neurosurgery* 1982;11:622-624.
- 65 McLone DG, Dias MS: Complications of myelomeningocele closure. *Pediatr Neurosurg* 1991;17:267-273.
- 66 Oi S, Yamada H, Matsumoto S: Tethered cord syndrome versus low-placed conus medullaris in an over-distended spinal cord following initial repair for myelodysplasia. *Childs Nerv Syst* 1990;6:264-269.
- 67 Ohe N, Futamura A, Kawada R, Minatsu H, Kohmura H, Hayashi K, Miwa K, Sakai N: Secondary tethered cord syndrome in spinal dysraphism. *Childs Nerv Syst* 2000;16:457-461.
- 68 Pang D, Wilberger JE Jr: Tethered cord syndrome in adults. *J Neurosurg* 1982;57:32-47.
- 69 Selber P, Dias L: Sacral-level myelomeningocele: long-term outcome in adults. *J Pediatr Orthop* 1998;18:423-427.
- 70 Tamaki N, Shirataki K, Kojima N, Shouse Y, Matsumoto S: Tethered cord syndrome of delayed onset following repair of myelomeningocele. *J Neurosurg* 1988;69:393-398.
- 71 Begeer JH, Meihuizen de Regt MJ, Hogen-Esch I, Ter Weeme CA, Mooij JJ, Vencken LM: Progressive neurological deficit in children with spina bifida aperta. *Z Kinderchir* 1986;41(suppl 1):13-15.
- 72 Roberts HE, Moore CA, Cragan JD, Fernhoff PM, Khoury MJ: Impact of prenatal diagnosis on the birth prevalence of neural tube defects, Atlanta, 1990-1991. *Pediatrics* 1995;96:880-883.
- 73 Garne E, Loane M, Dolk H, De Vigan C, Scarano G, Tucker D, Stoll C, Gener B, Pierini A, Nelen V, Rosch C, Gillerot Y, Feijoo M, Tincheva R, Queisser-Luft A, Addor MC, Mosquera C, Gatt M, Barisic I: Prenatal diagnosis of severe structural congenital malformations in Europe. *Ultrasound Obstet Gynecol* 2005;25:6-11.
- 74 Sutton LN, Adzick NS, Johnson MP: Fetal surgery for myelomeningocele. *Childs Nerv Syst* 2003;19:587-591.
- 75 Luthy DA, Wardinsky T, Shurtleff DB, Hollenbach KA, Hickok DE, Nyberg DA, Benedetto TJ: Cesarean section before the onset of labor and subsequent motor function in infants with meningomyelocele diagnosed antenatally. *N Engl J Med* 1991;324:662-666.
- 76 Shurtleff DB, Luthy DA, Nyberg DA, Benedetto TJ, Mack LA: Meningomyelocele: management in utero and post natum. *Ciba Found Symp* 1994;181:270-280, discussion 280-286.
- 77 Cochrane D, Aronyk K, Sawatzky B, Wilson D, Steinbok P: The effects of labor and delivery on spinal cord function and ambulation in patients with meningomyelocele. *Childs Nerv Syst* 1991;7:312-315.
- 78 Lewis D, Tolosa JE, Kaufmann M, Goodman M, Farrell C, Berghella V: Elective cesarean delivery and long-term motor function or ambulation status in infants with meningomyelocele. *Obstet Gynecol* 2004;103:469-473.
- 79 Hill AE, Beattie F: Does caesarean section delivery improve neurological outcome in open spina bifida? *Eur J Pediatr Surg* 1994;4(suppl 1):32-34.
- 80 Merrill DC, Goodwin P, Burson JM, Sato Y, Williamson R, Weiner CP: The optimal route of delivery for fetal meningomyelocele. *Am J Obstet Gynecol* 1998;179:235-240.
- 81 Sakala EP, Andree I: Optimal route of delivery for meningomyelocele. *Obstet Gynecol Surv* 1990;45:209-212.
- 82 Anteby E, Yagel S: Route of delivery of fetuses with structural anomalies. *Eur J Obstet Gynecol Reprod Biol* 2003;106:5-9.
- 83 ACOG Committee on Practice Bulletins: ACOG practice bulletin. Clinical management guidelines for obstetrician-gynecologists. Number 44, July 2003. (Replaces Committee Opinion Number 252, March 2001). *Obstet Gynecol* 2003;102:203-213.
- 84 Bayer C: Zur Technik der Operation der Spina Bifida und Encephalocele. *PragMed Wschr* 1892:317-345.
- 85 Machado HR, Santos De Oliveira R: Simultaneous repair of myelomeningocele and shunt insertion. *Childs Nerv Syst* 2004;20:107-109.
- 86 Miller PD, Pollack IF, Pang D, Albright AL: Comparison of simultaneous versus delayed ventriculoperitoneal shunt insertion in children undergoing meningomyelocele repair. *J Child Neurol* 1996;11:370-372.

- 87 Epstein NE, Rosenthal AD, Zito J, Osipoff M: Shunt placement and myelomeningocele repair: simultaneous vs. sequential shunting. Review of 12 cases. *Childs Nerv Syst* 1985;1:145-147.
- 88 Pang D: Surgical complications of open spinal dysraphism. *Neurosurg Clin N Am* 1995;6:243-257.
- 89 Chaddock WM, Reding DL: Experience with simultaneous ventriculo-peritoneal shunt placement and myelomeningocele repair. *J Pediatr Surg* 1988;23:913-916.
- 90 Burrington JD: Wound healing in the fetal lamb. *J Pediatr Surg* 1971;6:523-528.
- 91 Somasundaram K, Prathap K: Intra-uterine healing of skin wounds in rabbit foetuses. *J Pathol* 1970;100:81-86.
- 92 Huhn EA, Jannowitz C, Boos H, Papadopoulos MA, Zeilhofer HF, Henke J, Muller D, Kovacs L, Biemer E, Papadopoulos NA: Fetal wound healing: current status and new perspectives. *Chirurg* 2004;75:498-507.
- 93 Papadopoulos NA, Papadopoulos MA, Zeilhofer HF, Boos H, Henke J, Erhardt W, Boettcher P, Stolla R, Kovacs L, Biemer E: Intrauterine autogenous foetal bone transplantation for the repair of cleft-like defects in the mid-gestational sheep model. *J Craniomaxillofac Surg* 2004;32:199-210.
- 94 Steeves JD, Keirstead HS, Ethell DW, Hasan SJ, Muir GD, Pataky DM, McBride CB, Petrusch B, Zwimpfer TJ: Permissive and restrictive periods for brainstem-spinal regeneration in the chick. *Prog Brain Res* 1994;103:243-262.
- 95 Keirstead HS, Hasan SJ, Muir GD, Steeves JD: Suppression of the onset of myelination extends the permissive period for the functional repair of embryonic spinal cord. *Proc Natl Acad Sci USA* 1992;89:11664-11668.
- 96 Hasan SJ, Keirstead HS, Muir GD, Steeves JD: Axonal regeneration contributes to repair of injured brainstem-spinal neurons in embryonic chick. *J Neurosci* 1993;13:492-507.
- 97 Shimizu I, Oppenheim RW, O'Brien M, Schneiderman A: Anatomical and functional recovery following spinal cord transection in the chick embryo. *J Neurobiol* 1990;21:918-937.
- 98 Brunelli G, Brunelli F: Experimental foetal microsurgery as related to myelomeningocele. *Microsurgery* 1984;5:24-29.
- 99 Weidenheim KM, Kress Y, Epshteyn I, Rashbaum WK, Lyman WD: Early myelination in the human fetal lumbosacral spinal cord: characterization by light and electron microscopy. *J Neuropathol Exp Neurol* 1992;51:142-149.
- 100 Heffez DS, Aryanpur J, Hutchins GM, Freeman JM: The paralysis associated with myelomeningocele: clinical and experimental data implicating a preventable spinal cord injury. *Neurosurgery* 1990;26:987-992.
- 101 Osaka K, Tanimura T, Hirayama A, Matsumoto S: Myelomeningocele before birth. *J Neurosurg* 1978;49:711-724.
- 102 Korenromp MJ, van Gool JD, Bruinese HW, Kriek R: Early fetal leg movements in myelomeningocele. *Lancet* 1986;1:917-918.
- 103 Sival DA, Begeer JH, Staal-Schreinemachers AL, Vos-Niel JM, Beekhuis JR, Prechtl HF: Perinatal motor behaviour and neurological outcome in spina bifida aperta. *Early Hum Dev* 1997;50:27-37.
- 104 Drewek MJ, Bruner JP, Whetsell WO, Tulipan N: Quantitative analysis of the toxicity of human amniotic fluid to cultured rat spinal cord. *Pediatr Neurosurg* 1997;27:190-193.
- 105 Hutchins GM, Meuli M, Meuli-Simmen C, Jordan MA, Heffez DS, Blakemore KJ: Acquired spinal cord injury in human fetuses with myelomeningocele. *Pediatr Pathol Lab Med* 1996;16:701-712.
- 106 Meuli M, Meuli-Simmen C, Hutchins GM, Seller MJ, Harrison MR, Adzick NS: The spinal cord lesion in human fetuses with myelomeningocele: implications for fetal surgery. *J Pediatr Surg* 1997;32:448-452.
- 107 George TM, Cummings TJ: The immunohistochemical profile of the myelomeningocele placode: is the placode normal? *Pediatr Neurosurg* 2003;39:234-239.
- 108 Adzick NS, Walsh DS: Myelomeningocele: prenatal diagnosis, pathophysiology and management. *Semin Pediatr Surg* 2003;12:168-174.
- 109 Pang D, Dias MS: Cervical myelomeningocele. *Neurosurgery* 1993;33:363-372, discussion 372-363.
- 110 Sutton LN: Lipomyelomeningocele. *Neurosurg Clin N Am* 1995;6:325-338.
- 111 Duckworth T, Sharrard WJ, Lister J, Seymour N: Hemimyelocele. *Dev Med Child Neurol* 1968(suppl 16):69-75.
- 112 Michejda M: Intrauterine treatment of spina bifida: primate model. *Z Kinderchir* 1984;39:259-261.
- 113 Pedreira DA, Valente PR, Abou-Jamra RC, Pelarigo CL, Silva LM, Goldenberg S: Successful fetal surgery for the repair of a 'myelomeningocele-like' defect created in the fetal rabbit. *Fetal Diagn Ther* 2003;18:201-206.
- 114 Meuli-Simmen C, Meuli M, Adzick NS, Harrison MR: Latissimus dorsi flap procedures to cover myelomeningocele in utero: a feasibility study in human fetuses. *J Pediatr Surg* 1997;32:1154-1156.
- 115 Copeland ML, Bruner JP, Richards WO, Sundell HW, Tulipan NB: A model for in utero endoscopic treatment of myelomeningocele. *Neurosurgery* 1993;33:542-544, discussion 545.
- 116 Heffez DS, Aryanpur J, Rotellini NA, Hutchins GM, Freeman JM: Intrauterine repair of experimental surgically created dysraphism. *Neurosurgery* 1993;32:1005-1010.
- 117 Meuli M, Meuli-Simmen C, Yingling CD, Hutchins GM, Hoffman KM, Harrison MR, Adzick NS: Creation of myelomeningocele in utero: a model of functional damage from spinal cord exposure in fetal sheep. *J Pediatr Surg* 1995;30:1028-1032, discussion 1032-1033.
- 118 Meuli M, Meuli-Simmen C, Hutchins GM, Yingling CD, Hoffman KM, Harrison MR, Adzick NS: In utero surgery rescues neurological function at birth in sheep with spina bifida. *Nat Med* 1995;1:342-347.
- 119 Meuli-Simmen C, Meuli M, Hutchins GM, Harrison MR, Buncke HJ, Sullivan KM, Adzick NS: Fetal reconstructive surgery: experimental use of the latissimus dorsi flap to correct myelomeningocele in utero. *Plast Reconstr Surg* 1995;96:1007-1011.
- 120 Meuli M, Meuli-Simmen C, Yingling CD, Hutchins GM, Timmel GB, Harrison MR, Adzick NS: In utero repair of experimental myelomeningocele saves neurological function at birth. *J Pediatr Surg* 1996;31:397-402.
- 121 Paek BW, Farmer DL, Wilkinson CC, Albanese CT, Peacock W, Harrison MR, Jennings RW: Hindbrain herniation develops in surgically created myelomeningocele but is absent after repair in fetal lambs. *Am J Obstet Gynecol* 2000;183:1119-1123.
- 122 Bouchard S, Davey MG, Rintoul NE, Walsh DS, Rorke LB, Adzick NS: Correction of hindbrain herniation and anatomy of the vermis after in utero repair of myelomeningocele in sheep. *J Pediatr Surg* 2003;38:451-458, discussion 451-458.
- 123 Yoshizawa J, Sbragia L, Paek BW, Sydorak RM, Yamazaki Y, Harrison MR, Farmer DL: Fetal surgery for repair of myelomeningocele allows normal development of anal sphincter muscles in sheep. *Pediatr Surg Int* 2004;20:14-18.
- 124 Yoshizawa J, Sbragia L, Paek BW, Sydorak RM, Yamazaki Y, Harrison MR, Farmer DL: Fetal surgery for repair of myelomeningocele allows normal development of the rectum in sheep. *Pediatr Surg Int* 2003;19:162-166.
- 125 Danzer E, Kiddoo DA, Redden RA, Robinson L, Radu A, Zderic S, Doolin EJ, Adzick NS, Flake AW: Structural and functional characterization of bladder smooth muscle in fetal rats with retinoic acid induced myelomeningocele. *Am J Physiol* 2007;292:F197-F206.
- 126 Bruner JP, Tulipan NE, Richards WO: Endoscopic coverage of fetal open myelomeningocele in utero. *Am J Obstet Gynecol* 1997;176:256-257.
- 127 Bruner JP, Richards WO, Tulipan NB, Arney TL: Endoscopic coverage of fetal myelomeningocele in utero. *Am J Obstet Gynecol* 1999;180:153-158.
- 128 Tulipan N, Bruner JP: Myelomeningocele repair in utero: a report of three cases. *Pediatr Neurosurg* 1998;28:177-180.

- 129 Adzick NS, Sutton LN, Crombleholme TM, Flake AW: Successful fetal surgery for spina bifida. *Lancet* 1998;352:1675–1676.
- 130 Tulipan N, Hernanz-Schulman M, Lowe LH, Bruner JP: Intrauterine myelomeningocele repair reverses preexisting hind-brain herniation. *Pediatr Neurosurg* 1999; 31:137–142.
- 131 Kohl T, Hering R, Heep A, Schaller C, Meyer B, Greive C, Bizjak G, Buller T, Van de Vondel P, Gogarten W, Bartmann P, Knopfle G, Gembruch U: Percutaneous fetoscopic patch coverage of spina bifida aperta in the human—early clinical experience and potential. *Fetal Diagn Ther* 2006;21:185–193.
- 132 Tulipan N, Sutton LN, Bruner JP, Cohen BM, Johnson M, Adzick NS: The effect of intrauterine myelomeningocele repair on the incidence of shunt-dependent hydrocephalus. *Pediatr Neurosurg* 2003;38:27–33.
- 133 Johnson MP, Sutton LN, Rintoul N, Crombleholme TM, Flake AW, Howell LJ, Hedrick HL, Wilson RD, Adzick NS: Fetal myelomeningocele repair: short-term clinical outcomes. *Am J Obstet Gynecol* 2003;189: 482–487.
- 134 Farmer DL, von Koch CS, Peacock WJ, Danielpour M, Gupta N, Lee H, Harrison MR: In utero repair of myelomeningocele: experimental pathophysiology, initial clinical experience, and outcomes. *Arch Surg* 2003;138:872–878.
- 135 Zambelli H, Barini R, Iscaife A, Cursino K, Braga Ade F, Marba S, Sbragia L: Successful developmental outcome in intrauterine myelomeningocele repair. *Childs Nerv Syst* 2007;23:123–126.
- 136 Bruner JP, Tulipan N: Intrauterine repair of spina bifida. *Clin Obstet Gynecol* 2005;48: 942–955.
- 137 Bruner JP, Tulipan N, Reed G, Davis GH, Bennett K, Luker KS, Dabrowiak ME: Intrauterine repair of spina bifida: preoperative predictors of shunt-dependent hydrocephalus. *Am J Obstet Gynecol* 2004;190: 1305–1312.
- 138 Tubbs RS, Chambers MR, Smyth MD, Bartolucci AA, Bruner JP, Tulipan N, Oakes WJ: Late gestational intrauterine myelomeningocele repair does not improve lower extremity function. *Pediatr Neurosurg* 2003;38:128–132.
- 139 Holzbeierlein J, Pope JI, Adams MC, Bruner J, Tulipan N, Brock JW 3rd: The urodynamic profile of myelodysplasia in childhood with spinal closure during gestation. *J Urol* 2000;164:1336–1339.
- 140 Holmes NM, Nguyen HT, Harrison MR, Farmer DL, Baskin LS: Fetal intervention for myelomeningocele: effect on postnatal bladder function. *J Urol* 2001;166:2383–2386.
- 141 Mazzola CA, Albright AL, Sutton LN, Tuite GF, Hamilton RL, Pollack IF: Dermoid inclusion cysts and early spinal cord tethering after fetal surgery for myelomeningocele. *N Engl J Med* 2002;347:256–259.
- 142 Scott RM, Wolpert SM, Bartoshesky LE, Zimble S, Klauber GT: Dermoid tumors occurring at the site of previous myelomeningocele repair. *J Neurosurg* 1986;65:779–783.
- 143 Hamdan AH, Walsh W, Bruner JP, Tulipan N: Intrauterine myelomeningocele repair: effect on short-term complications of prematurity. *Fetal Diagn Ther* 2004;19:83–86.
- 144 Hamdan AH, Walsh W, Heddings A, Bruner JP, Tulipan N: Gestational age at intrauterine myelomeningocele repair does not influence the risk of prematurity. *Fetal Diagn Ther* 2002;17:66–68.
- 145 Farrell JA, Albanese CT, Jennings RW, Kilpatrick SJ, Bratton BJ, Harrison MR: Maternal fertility is not affected by fetal surgery. *Fetal Diagn Ther* 1999;14:190–192.
- 146 Longaker MT, Golbus MS, Filly RA, Rosen MA, Chang SW, Harrison MR: Maternal outcome after open fetal surgery: a review of the first 17 human cases. *JAMA* 1991; 265:737–741.
- 147 Lyerly AD, Cefalo RC, Socol M, Fogarty L, Sugarman J: Attitudes of maternal-fetal specialists concerning maternal-fetal surgery. *Am J Obstet Gynecol* 2001;185:1052–1058.
- 148 Chervenak FA, Duncan C, Ment LR, Tortora M, McClure M, Hobbins JC: Perinatal management of meningomyelocele. *Obstet Gynecol* 1984;63:376–380.
- 149 Tulipan N: Intrauterine closure of myelomeningocele: an update. *Neurosurg Focus* 2004;16:E2.
- 150 Aaronson OS, Tulipan NB, Cywes R, Sundell HW, Davis GH, Bruner JP, Richards WO: Robot-assisted endoscopic intrauterine myelomeningocele repair: a feasibility study. *Pediatr Neurosurg* 2002;36:85–89.
- 151 Papadopoulos NA, Dumitrascu I, Ordonez JL, Decaluwe H, Lerut TE, Barki G, Deprest JA: Fetoscopy in the pregnant rabbit at midgestation. *Fetal Diagn Ther* 1999;14: 118–121.
- 152 Papadopoulos NA, Van Ballaer PP, Ordonez JL, Laermans JJ, Vandenberghe K, Lerut TE, Deprest JA: Fetal membrane closure techniques after hysteroamniotomy in the midgestational rabbit model. *Am J Obstet Gynecol* 1998;178:938–942.
- 153 Deprest JA, Papadopoulos NA, Decaluwe H, Yamamoto H, Lerut TE, Gratacos E: Closure techniques for fetoscopic access sites in the rabbit at mid-gestation. *Hum Reprod* 1999;14:1730–1734.
- 154 Gratacos E, Yamamoto H, Papadopoulos NA, Adriaenssens T, Philips T, Lerut TE, Deprest JA: The midgestational rabbit as a model for the creation of membrane defects after needle fetoscopy. *Am J Obstet Gynecol* 1999;180:1263–1267.
- 155 Papadopoulos NA, Klotz S, Raith A, Henke J, Klöpferl M, Brill T, Müller D, Kovacs L, Erhardt W, Biemer E: Closure of fetoscopic defects of the fetal membranes in a midgestational rabbit model. *Geburtshilfe Frauenheilkd* 2003;63:651–657.
- 156 Papadopoulos NA, Klotz S, Raith A, Foehn M, Schillinger U, Henke J, Kovacs L, Horch RE, Biemer E: Amnion cells engineering: a new perspective in fetal membrane healing after intrauterine surgery? *Fetal Diagn Ther* 2006;21:494–500.
- 157 Portmann-Lanz CB, Ochsenbein-Kolble N, Marquardt K, Luthi U, Zisch A, Zimmermann R: Manufacture of a cell-free amnion matrix scaffold that supports amnion cell outgrowth in vitro. *Placenta* 2007;28:6–13.
- 158 Ochsenbein-Kölble N, Jani J, Lewi L, Verbist L, Vercruyse L, Portmann-Lanz B: Enhancing sealing of fetal membrane defects using tissue engineered native amniotic scaffolds in the rabbit model. *Am J Obstet Gynecol* 2007;196:263.
- 159 Chervenak FA, McCullough LB, Birnbach DJ: Ethical issues in fetal surgery research. *Best Pract Res Clin Anaesthesiol* 2004;18: 221–230.
- 160 Olutoye OO, Adzick NS: Fetal surgery for myelomeningocele. *Semin Perinatol* 1999; 23:462–473.