

Monaural Tinnitus from a Contralateral Inferior Colliculus Hemorrhage

H. Stimmer A. Borrmann C. Löer W. Arnold E.J. Rummeny

Institut für Röntgendiagnostik, Klinikum rechts der Isar, München, Deutschland

Key Words

Tinnitus · Colliculus inferior · Hemorrhage · Brainstem · Auditory pathway · Cavernoma

Abstract

A 48-year-old man presented with sudden right ear tinnitus and showed no other otoneurologic signs or symptoms. Auditory brainstem response revealed prolonged III–V interpeak latencies from stimulating either ear. MRI revealed a small, circumscribed lesion of the left inferior colliculus, probably from an acute hemorrhage leading to a small cavernous malformation. Circumscribed lesions of the inferior colliculus are rare with no prior reports of contralateral tinnitus.

Copyright © 2008 S. Karger AG, Basel

Introduction

The etiology of tinnitus is still largely unclear. The underlying disease of the middle or inner ear (the most common cause), of the cochlear nerve or the brainstem can be found in less than 1% of all tinnitus cases. Tinnitus resulting from a defined central nervous system disease is very rare. Only few cases of tinnitus caused by a circumscribed inferior colliculus lesion are known.

In this report, we discuss the auditory effects of a lesion in the central auditory pathway. The patient presented with sudden right ear tinnitus resulting from a small contralateral hemorrhagic brainstem lesion. The lesion, in all probability a cavernoma, was located in the mesencephalic colliculus inferior, which plays an important role in the transmission of acoustic afferences to the thalamus and to the temporal cortex.

Case Report

A 48-year-old man presented with right ear tinnitus (a high-pitched murmuring sound) with sudden onset the day before. On examination, his hearing was unimpaired, there were no symptoms of vertigo, both ear canals and tympanic membranes appeared normal and there were no neurological deficits – especially no cranial nerve pathologies. The medical history revealed no tinnitus episodes in the past or any possible triggering events like ototoxic drugs, noise, head injury or ear surgery. Test showed normal hearing bilaterally, no tympanometry abnormalities, normal stapedial reflexes and normal otoacoustic emissions bilaterally. The tinnitus was a pure tone at 6 kHz. On examination of the peripheral vestibular organs, a malfunction on the left side was found. Caloric testing revealed underexcitability of the peripheral vestibular organs on the left side. In the absence of clinical symptoms and neuroradiological findings, the vestibular lesion was interpreted as an older meanwhile compensated lesion. The patient's history gave no indication of any acute vestibular disease. An intravenous therapy with prednisolone was initiated but it did not change the intensity of the tinnitus. Therefore, the pa-

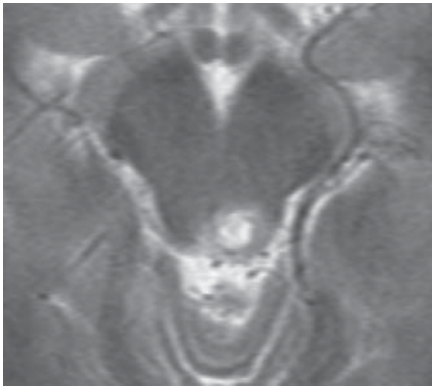


Fig. 1. MRI of the brain on 25.01.2005, T2 TSE axial (TR 3692, TE 96). Strong T2 hyperintense lesion in the left colliculus inferior, small hypointense rim, discrete hypointense internal structure, slight to moderate perifocal edema.

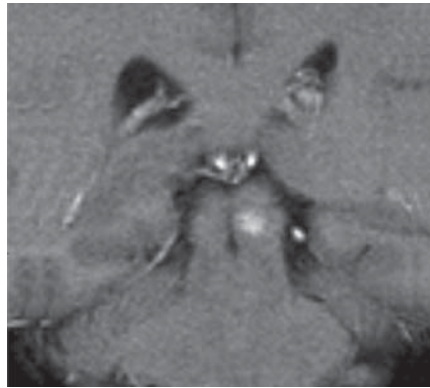


Fig. 2. MRI of the brain on 25.01.2005, T1 GRE coronal (TR 297, TE 10). Hyperintense lesion in the left colliculus inferior caused by methhemoglobin.

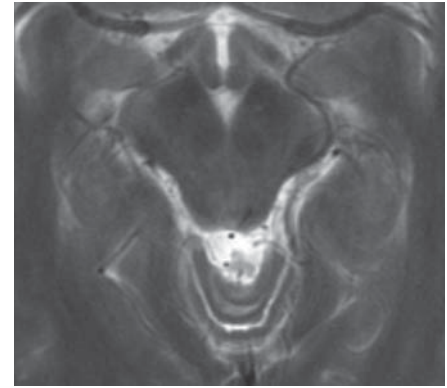


Fig. 3. MRI of the brain on 11.02.2005, T2 TSE axial (TR 4980, TE 104). Seventeen days later, only discrete T2 signal hyperintensity in the left inferior colliculus with slight central signal reduction.

4

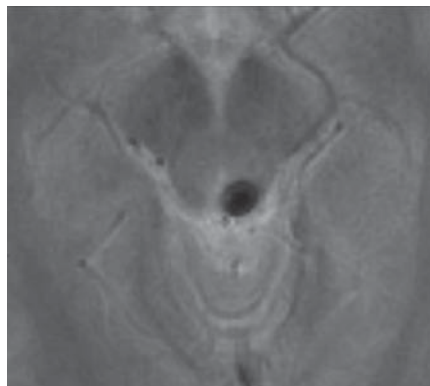
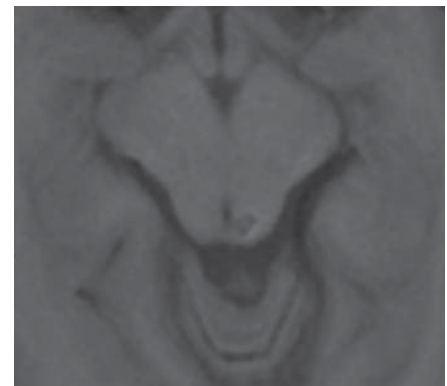


Fig. 4. MRI of the brain on 11.02.2005, T2 GRE axial (TR 802, TE 29). Heavy signal loss in the left inferior tectal plate. No other lesion of this kind in the brain parenchyma.

Fig. 5. MRI of the brain on 11.02.2005, T1 SE axial (TR 535, TE 13). Moderate central signal reduction in the left inferior colliculus with slightly hyperintense rim.

5



tient underwent further tests with the following pathological findings:

The auditory brainstem response testing showed a prolonged interwave latency on both sides. The prolongation was between peak III and V – with 2.8 ms on the right side and 2.9 ms on the left side (the upper threshold in our clinical system is 1.8 ms). This result corresponds to findings in a patient with a totally destroyed colliculus inferior, suggesting that the wave V generator is localized within or rostral to the inferior colliculus [Durrant et al., 1994].

A retrocochlear pathology was suspected and indeed verified by a cranial MRI. The images showed an isolated clearly circumscribed lesion in the left inferior colliculus in the midbrain's tectal plate. Initially, the lesion showed a hyperintense T1 signal and the T2 signal was predominantly hyperintense with a hypointense rim (fig. 1, 2). An acute hemorrhage in the left inferior colliculus was suspected and the MRI was repeated 17 days later. Now the signal intensity had clearly diminished on the T1 images, with T1 hypointense changes also noticeable. A further sig-

nal reduction occurred on T2 images; T2 GRE images showed a significant signal loss (fig. 3–5). No substantial gadolinium enhancement was seen in or around the inferior colliculus. Therefore, in all probability, the lesion appeared to be an isolated cavernoma in the left inferior colliculus with an acute hemorrhage that was responsible for the sudden onset of the tinnitus. No further parenchymal lesions, supra- or infratentorial, were found, especially not on T2 GRE images. The tinnitus improved slowly after the bleeding episode, but the patient still feels impaired by a lower pitch tone.

Discussion

The MRI signs mentioned above and their evolution are typical for an acute hemorrhage which in this case is located in the left colliculus inferior to the midbrain.

This clearly circumscribed midbrain hemorrhage may have been due to a small arteriovenous malformation; however, considering the MRI signal and the appearance of our patient's lesion, a midbrain cavernoma with an acute bleeding episode seems to be more probable.

Cavernous malformations of the brain can occur sporadically or are of genetic origin, but the latter usually present with multiple manifestations [Aiba and Tanaka, 1995]. Reported incidents are only between 0.4–0.9%.

In a survey published in 2002, 72 cavernomas were examined. Of these, 33% were localized in the brainstem [Bertalanffy et al., 2002].

In the generally published data on the distribution of cavernomas in the brainstem, most cavernomas are described as localized in the pons with about 14–16% in the mesencephalon [Fritschi et al., 1994; Porter et al., 1999].

Isolated and circumscribed hemorrhages in the mesencephalic colliculus inferior are extremely rare. In a review published in 2000, only 9 cases were mentioned [Chen et al., 2000], and up to 1996 only 3 patients were described [Bolzani et al., 1996].

Typical clinical signs of colliculus inferior hemorrhage are: contralateral sensory disturbance, uni- or bilateral trochlear nerve palsy and auditory effects contralateral to the lesion, such as tinnitus, impairment of sound source localization and difficulty of speech recognition in the presence of a competing ipsilateral signal.

Sensory disturbance is caused by the anatomic fact that the spinothalamic tract in its course lateral to the reticular formation is located near the lateral tectal plate [Nieuwenhuys et al., 1981]. The crossing trochlear nerve reaches the median part of the colliculus inferior. This topographic relationship is responsible for trochlear nerve palsy in a hemorrhage of the inferior colliculus [Cocito et al., 1990; Ishihara et al., 2003].

Neuro-otologic symptoms as described emphasize the function of the inferior colliculus in the central auditory pathway: Auditory afferences reach the ventral and dorsal parts of the cochlear nucleus after entering the brainstem through the cochlear nerve with the following transmission on the second neuron.

After this relay station in the cochlear nucleus, a further transfer follows, partly over the superior oliva and the nucleus of the lateral lemniscus, partly in the lateral lemniscus directly to the colliculus inferior. A smaller part of these fibers ascend to the inferior colliculus without crossing. In the inferior colliculus, another transmission follows to the next neuron, which leads to the thalamic corpus geniculatum mediale; from here, auditory afferences reach the transverse temporal gyri, the prima-

ry auditory cortex in the temporal lobe [Bähr and Frotscher, 2003; Demanez and Demanez, 2003; Oliver, 2000]. The fact that the tinnitus was contralateral and unilateral can be explained as follows: There are bilateral afferences from the colliculus inferior to the thalamus (corpus geniculatum mediale), but predominantly they reach the ipsilateral thalamus and then the auditory cortex in the temporal lobe. The colliculus inferior itself gets most of its afferences from the contralateral cochlear nerve. Possibly central cortical registration and processing localize the source of the sound on the side where most of the afferences physiologically come from, even if it arises in the colliculus inferior [Li et al., 1999].

Despite the fact that the bleeding was localized in the central auditory pathway, the patient did not suffer from hearing loss. A probable explanation is the bilaterality and redundancy of central transmissions. Auditory afferences reach the cochlear nucleus; from here, connections exist to the ipsi- and contralateral oliva; therefore, the lateral lemniscus receives auditory afferences from both sides that reach the right and left colliculus inferior and via the thalamus the auditory cortex on both sides [Nieuwenhuys et al., 1981; Bähr and Frotscher, 2003].

There are two possible explanations for tinnitus arising after colliculus inferior lesions. (1) There may be irritation in the neural tissue around the hemorrhage. This may be caused by an edema or instability of the cell membrane potential leading to hyperexcitability. (2) The other possible explanation is a disorder of the inhibitory mechanisms, i.e. the phenomenon of disinhibition.

Neurophysiological examinations (whole cell voltage clamp method) showed that the tinnitus was caused by salicylic acid-induced decreased GABA release in the inferior colliculus. This pharmacological mechanism blocks the calcium membrane channels. A lack of inhibitory GABAergic transmission, possibly induced by local bleeding, leads to disinhibition of neural activity in the colliculus inferior with the clinical consequence of tinnitus [Faingold, 2002; Liu et al., 2005].

It is remarkable that clearly delineated lesions in the inferior colliculus region cause not only focal otological or neurological deficits but also damage similar to that of higher brain function. For example, 'central' bilateral deafness following bilateral colliculus inferior hemorrhage is reported in the literature [Musiek et al., 2004]. This kind of deficit is usually caused by bilateral temporal lesions in the auditory cortex. Intensive rehabilitation leads to considerable improvement in such cases.

Impairment of sound localization in the contralateral hemifield and physiological echo suppression has also

been described after unilateral colliculus inferior hemorrhage [Litovsky et al., 2002].

Another report describes the case of a patient with small posttraumatic hemorrhage in the inferior colliculus on both sides who was surprisingly unable to comprehend spoken words, whilst speech, reading and writing were intact [Johkura et al., 1998].

This kind of deficit is usually found in patients with damage of higher brain function resulting from temporal cortical lesion. This fact illustrates the important function of the inferior colliculus in the central auditory pathway.

References

- Aiba T, Tanaka R: Natural history of intracranial cavernous malformations. *J Neurosurg* 1995;83:56–59.
- Bähr M, Frotscher M: *Neurologisch-topische Diagnostik*. Stuttgart, Thieme, 2003, pp 176–183.
- Bertalanffy H, Benes L, Miyazawa T, Alberti O, Siegel AM, Sure U: Cerebral cavernomas in the adult. Review of the literature and analysis of 72 surgically treated patients. *Neurosurg Rev* 2002;25:1–53.
- Bolzani W, Rognone F, Savoldi F, Montalbetti L: Colliculus hemorrhage. *Rev Neurol (Paris)* 1996;152:548–551.
- Chen CH, Hwang WJ, Tsai TT, Lai ML: Midbrain hemorrhage presenting with trochlear nerve palsy. *Zhonghua Yi Xue Za Zhi* 2000; 63:138–143.
- Cocito D, Amedeo G, Gallo G, Vischia F, De Lucchi R: Hematoma of the inferior colliculus: uncommon cause of trochlear nerve deficit and contralateral sensory hemisyndrome. *Ital J Neurol Sci* 1990;11:71–74.
- Demanez JP, Demanez L: Anatomophysiology of the central auditory nervous system: basic concepts. *Acta Otorhinolaryngol Belg* 2003; 57:227–236.
- Durrant JD, Martin WH, Hirsch B, Schwegler J: 3 CLT ABR analyses in a human subject with unilateral extirpation of the inferior colliculus. *Hear Res* 1994;72:99–107.
- Faingold CL: Role of GABA abnormalities in the inferior colliculus pathophysiology-audiogenic seizures. *Hear Res* 2002;168:223–237.
- Fritsch JA, Reulen HJ, Spetzler RF, Zabramski JM: Cavernous malformations of the brain stem. A review of 139 cases. *Acta Neurochir* 1994;130:35–46.
- Ishihara K, Furutani R, Shiota J, Kawamura M: A case presenting with trochlear nerve palsy and segmental sensory disturbance due to circumscribed midbrain and upper pontine hemorrhage. *Rinsho Shinkeigaku* 2003;43: 417–421.
- Johkura K, Matsumoto S, Hasegawa O, Kuroiwa Y: Defective auditory recognition after small hemorrhage in the inferior colliculi. *J Neurol Sci* 1998;161:91–96.
- Li Y, Evans MS, Faingold CL: Synaptic response patterns of neurons in the cortex of rat inferior colliculus. *Hear Res* 1999;137:15–28.
- Litovsky RY, Fligor BJ, Tramo MJ: Functional role of the human inferior colliculus in binaural hearing. *Hear Res* 2002;165:177–188.
- Liu Y, Li X, Ma C, Liu J, Lu H: Salicylate blocks L-type calcium channels in rat inferior colliculus neurons. *Hear Res* 2005;205:271–276.
- Musiek FE, Charette L, Morse D, Baran JA: Central deafness associated with midbrain lesion. *J Am Acad Audiol* 2004;15:133–151.
- Nieuwenhuys R, Voogd J, van Huijzen C: *The Human Central Nervous System*. Berlin, Springer, 1981, pp 117–120.
- Oliver DL: Ascending efferent projections of the superior olivary complex. *Microsc Res Tech* 2000;51:355–363.
- Porter RW, Detwiler PW, Spetzler RF, Lawton MT, Baskin JJ, Derksen PT, Zabramski JM: Cavernous malformations of the brainstem: experience with 100 patients. *J Neurosurg* 1999;90:50–58.